World Journal of Laparoscopic Surgery

An Official Publication of the World Association of Laparoscopic Surgeons, UK

Editors-in-Chief
RK Mishra (India)
Jiri PJ Fronek (UK)

WJOLS

Also available online at
www.jaypeejournals.com
www.wjols.com

Access Online Resources

For more details, visit
www.wjols.com

Bibliographic Listings:
ProQuest, Scopus, Journals Factor, EBSCO,Genamics JournalSeek, Emcare, HINARI, Embase, J Gate, Google Scholar, Ulrich, CiteFactor, SIS, OAJI, MIAR, SIF, COSMOS, ESJI, SJIF, SJR, IIJIF, ICI

JAYPEE Jaypee Journals

Editorial

Since 2008, I have served as editor of the World Journal of Laparoscopic Surgery (WJOLS). I have done this while practicing and teaching Minimal Access Surgery. Working with surgeons and gynecologists on the frontline from more than 108 countries, I know the importance of reliable information in advanced laparoscopic and other allied minimal access surgical procedures. With respect to modern MIS research, laparoscopic and da Vinci robotic surgical information is now a substantial component of what we publish. In WJOLS, we do not only publish articles because they may make headlines, we but publish them for their scientific value and evidenced-based clinical utility.

In WJOLS we are regularly providing a value added educational surgical DVD related to laparoscopic and robotic surgery. As we grew, we have substantially changed the type of research we published. We have also improved WJOLS's performance and reporting. With the time based on our prior experience we improved the publication of original research and we have developed a way to find the most authoritative and least biased review articles and editorials rather than pursuing a prejudicial approach with commercial entities.

In 2008, only less than a third of our readers accessed the WJOLS electronically. In 2015, nearly 90% of readers' usage is on our digital platform at wjols.com and it is growing substantially. Most of the articles are now getting indexed with very high ranking to almost all the search engines of the world. I am sure with the increasing popularity and due to love of the readers very soon WJOLS will be the most popular journal of laparoscopic surgery in whole world.

RK Mishra
Editor-in-Chief

10.5005/jp-journals-10033-1250

RESEARCH ARTICLE

Comparison of Open and Closed Entry Techniques for Creation of Pneumoperitoneum in Laparoscopic Surgery in Terms of Time Consumption, Entry-related Complications and Failure of Technique

[1]Muzzafar Zaman, [2]Samita Singal, [3]Rikki Singal, [4]Aliya Shah, [5]Karamjot Singh Sandhu, [6]Bir Singh
[7]Aadhar Khera, [8]Sagar Bassi

ABSTRACT

The modern art of examining the abdominal cavity by laparoscopy and its contents which requires insertion of a cannula through abdominal wall, creation of pneumoperitoneum and visualization of abdominal cavity to perform any surgical procedure has become a routine in many institutions. The first step in any laparoscopic procedure is creation of pneumoperitoneum for which mostly carbon dioxide is the recommended gas used. Two commonly used methods to create pneumoperitoneum are closed (veress needle) and open technique (Hasson technique). Both have their own advantages and disadvantages. The current study was designed to compare these two techniques in terms of safety of the procedure, time for induction of pneumoperitoneum, air leakage, and time required to complete the procedure.

Aim: To compare the open and closed methods of creating pneumoperitoneum for doing various laparoscopic procedures in terms of their safety, operating time and other parameters.

Settings and design: A prospective randomized double blind study.

Materials and methods: This was a randomized controlled prospective study conducted at Department of General and minimal access surgery, MMIMSR Medical College, Ambala Haryana from August 2013 to December 2015. Pneumoperitoneum was created by closed technique in group A, and by open technique in group B. Time required for successful pneumoperitoneum was calculated in each group. Failure to induce pneumoperitoneum was determined for each technique. Time required to induce pneumoperitoneum, total operating time, air leakage and injuries sustained during induction of pneumoperitoneum were compared in both techniques.

Result: Out of the total 200 patients included in study, 100 were in group A and 100 in group B. Mean time required for successful pneumoperitoneum was 9.17 minutes in group A and 8.11 minutes in group B. Total operating time ranged from 55 minutes to 130 minutes in group A and from 45 to 110 minutes in group B. Mean of total operating time was 78.34 and 67 minutes in groups A and B respectively. Mean time needed to close the wound was 9.88 minutes in group A and 4.97 minutes in group B. Failure of technique was noted in three patients in group A while no failure was experienced in group B. Air leakage was seen in five patients in group B and none in group B. In two cases in group A minor complications during creation of pneumoperitoneum were observed while in group B no complication occurred. Port site infection and port site hernia was seen in group B and none in group A. No patient died in the study. Two patients were having preperitoneal insufflation which was presented as injury due to induction of pneumoperitoneum.

Conclusion: We concluded from this study that open technique of pneumoperitoneum was, less time consuming and safer than the closed technique.

Keywords: Hasson's technique, Laparoscopic cholecystectomy, Pneumoperitoniem, Veress needle.

How to cite this article: Zaman M, Singal S, Singal R, Shah A, Sandhu KS, Singh B, Khera A, Bassi S. Comparison of Open and Closed Entry Techniques for Creation of Pneumoperitoneum in Laparoscopic Surgery in Terms of Time Consumption, Entry-related Complications and Failure of Technique. World J Lap Surg 2015;8(3):69-71.

Source of support: Nil

Conflict of interest: None

[1,2]Assistant Professor, [3,6]Professor, [4]Postgraduate
[5]Senior Resident [7,8]Postgraduate Resident

[1,3,5,7,8]Department of Surgery, Maharishi Markandeshwar Institute of Medical Sciences and Research, Ambala, Haryana India

[2]Department of Radiology, Maharishi Markandeshwar Institute of Medical Sciences and Research, Ambala, Haryana, India

[4]Department of Microbiology, Maharishi Markandeshwar Institute of Medical Sciences and Research, Ambala, Haryana, India

[6]Department of Surgery, Gain Sagar Medical and Hospital Banur, Punjab, India

Corresponding Author: Muzzafar Zaman, Assistant Professor, Maharishi Markandeshwar Institute of Medical Sciences and Research, Ambala, Haryana, India, Phone: 8059931554, e-mail: muzzafarzaman@yahoo.com

INTRODUCTION

The existence of numerous methods for the induction of pneumoperitoneum at laparoscopy surgery indicates that none have been proven totally efficacious or complication free. These methods include the standard or closed technique of insufflation after insertion of the Veress needle via the umbilicus (infra or supra umbilical), open laparoscopy involving dissection through the linea alba

and opening of the peritoneum under direct vision, and direct trocar insertion. After reviewing the two methods available and surveying the existing data concerning the rates of failure and complications, we conclude that no single technique can claim to be overwhelmingly superior, and that laparoscopic surgeons should, therefore, acquaint themselves with both of these two techniques. The umbilical port (10 mm) is also known as primary port, through which laparoscope is introduced. The majority of visceral or vessel injury is due to entry of primary umbilical port.[1]

The open technique was first described by Hasson in 1970. This technique consists of creating a small umbilical incision under direct visualization to enter the abdominal cavity followed by the introduction of a blunt trocar. Pneumoperitoneum is then rapidly created. Hasson proposed its potential benefits to be the avoidance of blind insertion of the Veress needle and bladed trocar, prevention of visceral and vascular injuries, preperitoneal insufflation and gas embolism, guaranteed pneumoperitoneum, and a more anatomical repair of the abdominal wall.[2]

Under usual circumstances, the Veress needle is inserted in the umbilical area, in the midsagittal plane, with or without stabilizing or lifting the anterior abdominal wall. In patients known or suspected to have periumbilical adhesions, or after failure to establish pneumoperitoneum after three attempts, alternative sites for Veress needle insertion may be sought.[3]

Both of these techniques are associated with vascular as well as visceral injury, but extensive literature reviews have not proved the superiority of one technique to the others, largely due to the lack of large, randomized, controlled trial data. Today, some 30 years on, the debate continues as to which method is the safest to use. Various unreliable available body of facts indicates that the younger generation of General surgeons prefer the open technique.[4-6]

AIMS AND OBJECTIVES

The aim of the study is to see the difference between open and closed methods of creation of pneumoperitoneum for performing any laparoscopic procedure in terms of operating time, safety, failure of technique and time for creation of pneumoperitoneum.

MATERIALS AND METHODS

The study was carried out in the Department of General Surgery, MMIMSR Medical College and Hospital, Ambala, Haryana from August 2013 to December 2015.

INCLUSION CRITERIA

- Cholelithiasis (uncomplicated)
- Age 18 to 70 years
- No history of previous laparotomy
- Normal umbilicus.

EXCLUSION CRITERIA

- Age < 18 and > 80
- Pregnancy
- Past history of laparotomy
- Umbilical hernia or granuloma/abscess
- Severe systemic illnesses.

OBSERVATION AND RESULTS

The study was conducted at MMIMSR Medical College and Hospital, Ambala, Haryana. A total of 200 patients were studied out of which 170 underwent laparoscopic, 20 laparoscopic hernia repair and 10 laparoscopic appendectomy (Table 1). All the patients underwent laparoscopic procedures were divided into two groups A and B. In group A, pneumoperitoneum was created using closed technique and in group B it was created using open technique. The two groups had different parameters regarding time of consumption of entry technique for pneumoperitoneum, safety of viscera vessels and bladder, air leakage, port site hernia and failure of both techniques in two groups (Tables 2 and 3).

DISCUSSION

Minimal access surgery has become the method of choice for management of symptomatic and uncomplicated gallbladder stones, appendectomies and hernia repair

Table 1: Type of procedure carried out in two groups

Procedure	*Group A (n = 100)*	*Group B (n = 100)*
Laparoscopic cholecystectomy	85	85
Laparoscopic appendectomy	5	5
Laparoscopic hernia repair	10	10

Table 2: Time analysis in two groups

Variable	*Group A*		*Group B*	
p-value	*Range*	*Mean SD*	*Range*	*Mean SD*
Time required to induce pneumoperitoneum 0.044	6–17	9.17 ± 2.86	6–10	8.11 ± 1.02
Total operating time 0.005	55–130	78.34 ± 21.59	45–110	67 ± 15.11
Hospital stay 0.034	36–72	49.71 ± 8.30	36–56	45.1 ± 6.76

Table 3: Complications in two groups

Variable	*Group A (100)*	*Group B (100)*
Failure of technique	0	3 (3%)
Air leakage	5 (5%)	0
Port site infection	2 (2%)	0
Port site hernia	0	1 (1%)
Injuries (including preperitoneal insufflation)	0	2 (2%)

p value < 0.05

(TAPP and TEP). One of the key steps in this type of surgery is induction of pneumoperitonium, which is not physiological and has adverse hemodynamic and respiratory outcomes.[7,8] These effects can be minimized with appropriate dedicated anesthetic management.[14-16] Iatrogenic injuries in laparoscopic surgery, however, are still a problem confronted by the surgeon.[15,16] Traditional closed method of pneumoperitonium involves initial blind entry into abdomen and more than half of such injuries are related to this primary blind access and occur before the start of actual anatomic dissection.[9] It is because of these complications that laparoscopic surgery faced a lot of criticism by the surgical community in the beginning.[10] To prevent these complications other methods were introduced in practice like open technique as devised by Harrith Hasson, direct trocar insertion, optical trocars, radically expending trocars and use of disposable shielded trocars.[11-14] However, the veress needle technique and Hasson's technique with their different modifications are the two widely used methods today.[15] We compared these methods in terms of time required to induce pneumoperitonium, time needed to close the wounds, total operating time and complications associated with each method in our studies if failure of technique was more seen in case of closed technique then on other hand port site infection, and air leakage was more a problem with open technique.

CONCLUSION

From this study we can reach to a conclusion that there is no evidence to support the superiority of one technique over the other, and this view is supported by the literature. We believe that surgeons should be competent in both techniques. Either can be used without undue risk.

REFERENCES

1. Fuller J, Scott W, Ashar B, Corrado J. Laparoscopic trocar injuries: a report from US FDA center for devices and radiological health. Systematic Technology Assessment of Medical Products Committee 2005;25:1-14.
2. Kovachev S, Ganovska A, Atanasova V, Sergeev S, Mutafchiyski V, Vladov N. Open laparoscopy: a modified Hasson technique. Akush Ginekol (Sofiia) 2015;54(4):52-56.
3. Dunne N, Booth MI, Dehn TC. Establishing pneumoperitoneum: verres or hasson? The debate continues. Ann R Coll Surg Engl 2011 Jan;93(1):22-24.
4. Ballem RV, Rudomanski J. Techniques of pneumoperitoneum. Surg Laparosc Endosc 1993;3(1):42-43.
5. Hurd WW, Randolph JF Jr, Holmberg RA, Pearl ML, Hubbell GP. Open laparoscopy without special instruments or sutures. Comparison with a closed technique. J Reprod Med 1994;39(5):393-397.
6. Catarci M, Carlini M, Gentileschi P, Santoro E. Major and minor injuries during the creation of pneumoperitoneum: a multicenter study on 12,919 cases. Surg Endosc 2001;15(6):566-567.
7. Schulze S, Lyng KM, Bugge K, Perner A, Bendtsen A, Thorup J, et al. Cardiovascular and respiratory changes and convalescence in laparoscopic colonic surgery comparison between carbon dioxide pneumoperitoneum and gasless laparoscopy. Arch Surg 1999;134(10):1112-1118.
8. Safran DM, Orlando R. Physiologic effects of pneumoperitoneum. Am J Surg 1994;167(2):281-286.
9. Jansen FW, Kapiteyn K, Trimpos T, Herman J. Complication of laparoscopy: a prospective multicentre study. Br J Obstet Gynaecol 1997;104(5):595-600.
10. Yuzpe AA. Pneumoperitoneum needle and trocar injuries in laparoscopy: a survey on possible contributing factors and prevention. J Reprod Med 1990;35(5):485-490.
11. Molly D, Kalloo PD, Cooper M. Laparoscopy entry: a literature review and analysis of techniques and complications of primary port entry. Aust NZ J Obstet Gynaecol 2002;14(3):365-374.
12. Yerdel MA, Karayalcin K, Koyuncu A, Akin B, Koksoy C, Turkcapar AG, et al. Direct trocar insertion versus veress needle insertion in laparoscopic cholecystectomy. Am J Surg 1999 Mar;177(3):247-249.
13. Vilos GA, Ternamian A, Dempster J, Labergy PY. Laparoscopic entery; a review of techniques, technologies and complications. J Obstet Gynaecol Can 2007;29(5):433-465.
14. Ahmad G, Daffy JM, Philips K, Watson A. Laparoscopic entry techniques. Cochrane Database Syst Rev 2008;16(2):CD006583
15. Vilos GA, Vilos AG. Safe laparoscopic entry guided by Veress needle CO_2-insufflation pressure. J Am Assoc Gynaecol Laparosc 2003;10(3):415-420.
16. Singal R, Singal RP, Sandhu K, Singh B, Bhatia G, Khatri A, Sharma BP. Evaluation and comparison of postoperative levels of serum bilirubin, serum transaminases and alkaline phosphatase in laparoscopic cholecystectomy versus open cholecystectomy. J Gastrointest Oncol 2015;6(5):479-486. Available at: http://doi.org/10.3978/j.issn.2078-6891.2015.058

10.5005/jp-journals-10033-1251

ORIGINAL ARTICLE

Laparoscopic Surgery: Results of a Modified Open Technique of Umbilical Port Insertion

[1]Sarbjeet Singh, [2]Delie Rhezhii

ABSTRACT

Insertion of first port and creation of pneumoperitoneum is a key step in laparoscopic surgery. A significant number of complications can be avoided by safe insertion of primary port. Various techniques of umbilical port insertion and their safety have been mentioned in literature. Closed method by using Veress needle is a blind procedure. Studies have shown that vascular injuries are more common with the Veress needle. Hasson first introduced the open technique of port insertion under direct vision. We used a modified open technique and analyzed the safety and efficacy in 80 cases.

Keywords: Laparoscopic surgery, Open technique, Umbilical port.

How to cite this article: Singh S, Rhezhii D. Laparoscopic Surgery: Results of a Modified Open Technique of Umbilical Port Insertion. World J Lap Surg 2015;8(3):72-74.

Source of support: Nil

Conflict of interest: None

INTRODUCTION

In laparoscopic surgery, open method of primary port insertion was first described by Hasson in 1971.[1] The port is inserted under direct vision. Another technique is by blind insertion of Veress needle, which is associated with some serious complications, such as gas embolism, vascular injury and injury to hollow viscus.[2-7] So, Hasson's open method is considered superior to closed method because of lower rate of complications associated with former.[8] In literature, various open techniques for creation of pneumoperitoneum are mentioned. In present study we practiced a modified technique of open method of creating pneumoperitoneum with the objective of evaluating its complications and efficacy.

METHODS

A prospective study was conducted upon 80 conse cutive cases in the department of general surgery during a period from 2011 to 2012. A modified technique of open method of creating pneumoperitoneum in laparoscopic surgery was performed in these patients after taking detailed informed consent. Indication for laparoscopy in these patients was cholecystectomy (90%), diagnostic laparoscopy (8%), laparoscopic liver abscess drainage (2%). Patients with cardiac diseases, chronic respiratory diseases, bleeding disorders, extensive abdominal scars, suspected cases of malignancy and adhesions due to previous surgery or peritonitis and pregnant patients were excluded from the study. Results were analyzed in terms of technical difficulty, time taken for umbilical port insertion, intraoperative gas leak, port closure time and complications, such as vascular injury, visceral injury, postoperative incisional hernia and umbilical sepsis.

TECHNIQUE

After paint and drape, surgeon stands on right side of patient. A semicircular, skin incision about 1.5 cm is made in infraumbilical crease and skin is retracted with langenback retractors. Umbilical skin is held with a towel clip and lifted up. Subcutaneous fat is dissected to expose umbilical stack and its junction with rectus sheath (Fig. 1). Umbilical stalk is stretched by pulling the towel clip up. using no. 11 surgical blade, a vertical incision, about 1 cm is made on umbilical stalk, starting from its junction with rectus sheath and extending upward. While maintaining upward traction on anterior abdominal wall, using tip of

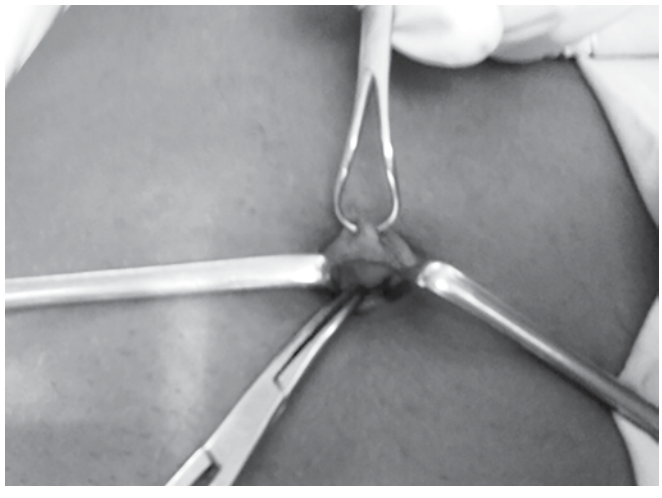

Fig. 1: Dissection of umbilical pillar

[1]Assistant Professor, [2]Resident

[1,2]Department of Surgery, Guru Gobind Singh Medical College Faridkot, Punjab, India

Corresponding Author: Sarbjeet Singh, Assistant Professor Department of Surgery, Guru Gobind Singh Medical College 223, Medical Campus, Faridkot, Punjab, India, Phone: 9855602532, e-mail: drsarab21@gmail.com

an artery forceps peritoneum is carefully breached, cavity is entered and jaw of artery forceps opened. By keeping the blades of artery forceps open, assistant shows opening in umbilical stalk and surgeon introduces tip of blunt trocar-canulla (Hassan trocar) through the opening in the stalk, applying little pressure with right hand and lifting the abdominal wall with left hand (Figs 2 and 3). Trocar is removed from cannula, carbondioxide gas is insufflated and pneumoperitoneum is created. After completion of procedure, umbilical stalk is everted by holding with an allis forceps and a nonabsorbable suture is applied to close the opening.

RESULTS AND DISCUSSION

All patient were in adult age group, age varying from 28 to 62 years. Average time taken for umbilical port insertion was 40 to 50 seconds. Intraoperative gas leakage around the umbilical port occurred in five cases which was corrected by applying sutures around skin incision. In one case, umbilical port was wrongly directed in extraperitoneal space leading to extraperitoneal gas insufflations. It was immediately detected and corrected. No complication of vascular injury or visceral injury occurred by this technique. None of the patients developed umbilical hernia at 6 months of follow-up. Closure of rectus sheath incision at umbilical port site could be easily done in all cases. Average closure time for umbilical port was 1 minute. Intraoperatively no other technical difficulty was encountered. Minor umbilical sepsis developed in seven cases. It was due to application of towel clip to umbilical skin.

Fig. 2: Lifting the abdominal wall and insertion of blunt trocar

Fig. 3: Blunt trocar inserted through umbilical stalk

Insertion of first port and creation of pneumoperitoneum is a key step in laparoscopic surgery. Closed method by using Veress needle is a blind procedure.[9] Studies have shown that vascular injuries are more common with the Veress needle.[10] To avoid these complications, Hasson introduced the open technique of port insertion under direct vision.[1] In the conventional open technique, an umbilical skin crease incision is made after making a skin stab with surgical blade no. 11 and subcutaneous fat is dissected. A transverse incision is made in the rectus sheath. Anterior abdominal wall is lifted by grasping between fingers and thenar eminence of one hand of operating surgeon and assistant on the other side. Operating surgeon using his dominant hand inserts the blunt Hasson trocar through the opening in rectus sheath.[11] Studies have shown that open technique is faster and has lesser complication rate than Veress needle. As a blunt cannula is used for creating pneumoperitoneum and surgeon can also insert his index finger through umbilical incision to confirm the peritoneal space and to break minor adhesions. There is decreased risk of gas embolism, bowel and vascular injury.[12] Risk of complications of in laparoscopic surgery can be further minimized by this modified technique. In modified open technique, it is easier to hold the anterior abdominal wall by grasping the everted umbilical cicatrix with the help of a towel clip and to lift the anterior abdominal wall by pulling umbilical stalk which is a tough structure. It gives adequate traction for safe introduction of port. As umbilical stalk contains obliterated umbilical vessels so, a safe stab incision can be made through. Length of incision in umbilical stalk is adequate to accommodate the size of 10 mm cannula. Junction of umbilical stalk and linea alba is the thinnest part of anterior abdominal wall and peritoneum at this point is fused in a single layer. So port is easily inserted after minimal dissection and without much tissue resistance. After removal of port on completion of the procedure, spontaneous apposition of margins of umbilical stalk occurs and makes the port closure easier. So, modified open technique is an easy and safe technique of primary port insertion and creation of pneumoperitoneum.

REFERENCES

1. Hasson HM. A modified instrument and method for laparoscopy. Am J Obstet Gynecol 1971;110(6):886-887.
2. Siren PH, Kurki T. Nationwide analysis of laparoscopic complications. Obstet Gynecol 1997;89(1):108-112.
3. Chapron CM, Pierre F, Lacroix S, Querleu D, Lansac J, Dubuisson JB. Major vascular injuries during gynecologic laparoscopy. J Am Coll Surg 1997;185(5):461-465. Comments in: J Am Coll Surg 1998;186(5):604-605.
4. Geers J, Holden C. Major vascular injuries as a complication of laparoscopic surgery: a report of three cases and review of literature. Am Surg 1996;62(5):377-379.
5. Champault G, Cazacu F, Taffinder N. Serious trocar accidents in laparoscopic surgery: A French surgery of 103,852 operations. Surg Laparosc Endosc 1996;6(5):367-370.
6. Hanney RM, Alle KM, Cregan PC. Major vascular injury and laparoscopy. Aust N Z J Surg 1995;65(7):533-535.
7. Nordestgaard AG, Bodily KC, Osborne RW, Buttorff JD. Major vascular injuries during laparoscopic procedures. Am J Surg 1994;169(5):543-545.
8. Lal P, Sharma R, Chander R, Ramteke VK. A technique of open trocar placement in laparoscopic surgery using the umbilical cicatrix tube. Surg Endosc 2002;16(9):1366-1370.
9. Fitzgibbons RJ, Marsh RE. Methods of creating a pneumoperitoneum. Surgical Laparoscopy. 2nd ed. Philadelphia, Lippin-cott Williams and Wilkins; 2001. p. 28-39.
10. Chandler JG, Corson SL, Way LW. Three spectra of laparoscopic entry access injuries. J Am Coll Surg 2001;192(4): 478-490.
11. Palanivelu C. Laparoscopic space access. In: Parthasarathi R, editor. Art of laparoscopic Surgery. 1st ed. India: Jaya Publications; 2005. vol. 1. p. 63.
12. Vilos GA, Ternamian A, Dempster J, Laberge PY. Laparoscopic entry: a review of techniques, technologies, and complications. J Obstet Gynaecol Can 2007;29(5):433-465.

10.5005/jp-journals-10033-1252

ORIGINAL ARTICLE

Sleeve Gastrectomy in Metabolic Syndrome for Nonmorbid Obese Patients: Is this the Future for Diabetes Treatment?

[1]Ricardo López Osorio, [2]Pablo Hartedt

ABSTRACT

During the development of surgical treatments, there have been so many improvements and challenging task that have lead surgeons to treat patients with new procedures and new indications.

Gastrectomy surgery initially was performed for cancer surgery. Now it is a worldwide performed procedure for complete healthy stomachs, but the main indication its weight loss, and all the physiological improvements that this procedure will bring to the patients' health.

During the bariatric surgery development, there have been different choices for different indications and different patients, depending on a variety of conditions and data that take evidence based medicine, to approve that this procedures can be accepted in the surgical field.

All the studies that have been showing improvement of medical conditions in obese patients, and had compared different type of procedures (Gastric Bypass, Duodenal Switch, Biliopancreatic Divertion, Sleeve Gastrectomy), led surgeon in different part of the world to take indications of surgery beyond weight loss. Being proved by previous analysis, that most of the patients get remission or cure, of comorbidities before an statistically significant weight loss, this study was led to perform vertical sleeve gastrectomy in patients with overweight, nonobese, that where diagnosed with metabolic syndrome (MS). Ten patients where operated (f = 6 m = 4), all of them met at least three criteria for MS (National Cholesterol Education Program Adult Treatment Panel III Citeria), 100% had diabetes mellitus (DM) as a criteria. After surgery the patients where followed up to 12 months and the mean body mass index (BMI) achieved overall was 22.58 kg/m^2 being the minimum 18.8 kg/m^2 (f = 22.28 m = 22.44). The total mean weight loss overall was 64.95 $\pm$ 12.6 kg, and the mean percentage of weightloss was 35% of initial weight with no clinical significance in the patients and 70% had remission of DM.

Keywords: Bariatric surgery, Diabetes remission, Metabolic surgery, Metabolic syndrome, Nonobese, Sleeve gastrectomy.

How to cite this article: Osorio RL, Hartedt P. Sleeve Gastrectomy in Metabolic Syndrome for Nonmorbid Obese Patients: Is this the Future for Diabetes Treatment? World J Lap Surg 2015;8(3):75-80.

Source of support: Nil

Conflict of interest: None

[1,2]Surgeon

[1,2]Department of Laparoscopic, Metabolic and Bariatric Surgery MetaboliK Minimal Acces Surgery Center, San Benito, Peten Guatemala, CA

Corresponding Author: Ricardo Lopez Osorio, Surgeon Department of Laparoscopic, Metabolic and Bariatric Surgery MetaboliK Minimal Acces Surgery Center, San Benito, Peten Guatemala, CA, e-mail: drlopezri@gmail.com

INTRODUCTION

Obesity and its comorbidities have been the pillars of procedures and investigations to reduce the morbidity and mortality of this preventable disease. Obesity is the second cause of preventable deaths in US after smoking, therefore, this disease is making of bariatric surgery, one of the most performed gastrointestinal procedures in US. In obese patients, main indication of consult in bariatric clinics is not the esthetic aspect but a clinical problem due to morbidity that causes severe weight, like hypertension, diabetes, gout, etc.

Bariatric surgery was initiated in the 1990, with the specific indication of treatment of morbid obese patients, and the main goal of this procedures is to establish an anatomical restructure, for restrictive and metabolic gastrointestinal absorption modification.[1] The main objective of this procedures is to reduce weight, but during the experience of surgeon performing and investigating long-term outcomes of this procedures, it's been shown that comorbidities are improved even before weight loss begins.[2]

Therefore, the metabolic changes that this procedures involves, and the metabolic improvement in patients with metabolic syndrome (MS), took expert surgeons in this field to research if it is possible to improve diabetes mellitus (DM), hypertension, dyslipidemia, which all are diagnostic criteria of MS. And with several data published of improvement of this criteria with deferent type of bariatric procedures, in nonmorbid obese patients,[3-6] we decided to add more data performing a restrictive gastric procedure that can improve MS and remission of DM in nonobese patients.

METABOLIC SYNDROME

Metabolic syndrome (MS) was described by The World Health Organization (WHO) in 1998. Based that insulin resistance was the center pillar to the pathophysiology of MS, the WHO criteria had to determine insulin resistance in patients. Fasting glucose level above 100 mg/dl or impaired glucose tolerance (IGT), defined as a glucose level above 140 mg/dl, after ingestion of 75 gm of glucose load during an oral glucose tolerance test. Alternatively, other measures could serve as evidence of insulin resistance, such as an elevated homeostatic model assessment of insulin resistance (HOMA-IR)

value. In addition to this absolute requirement for insulin resistance, two additional criteria of five, have to be met, to stablish MS. These included obesity, hypertension, dyslipidemia and microalbuminuria.

In 2001, the National Cholesterol Education Program Adult Treatment Panel III (NCEP-ATP III) defined the MS if three or more of the following five criteria are met: waist circumference over 40" in men or 35" in women, blood pressure over 130/85 mm Hg, fasting triglyceride (TG) level over 150 mg/dl, fasting high-density lipoprotein (HDL) cholesterol level less than 40 mg/dl in men or 50 mg/dl in women and fasting blood sugar over 100 mg/dl. This definition does not require that any specific criterion be met, only that at least three of five criteria are met. This definition will not imply that the main cause of MS is the insulin resistance or obesity.

METABOLIC EFFECT OF BARIATRIC PROCEDURES

The Role of the Intestinal Hormones

Previous investigations have demonstrated the rising levels of intestinal hormones segregated to luminal space during postoperative stages of bariatric patients. Neuroendocrinal stimulation and negative feedback in hormones in obese patients are marking an important role in DM control and stimulation. Parietal cells in gut secrete hormones that will directly and indirectly act over glycemic control. The peptides made in the gut and released into the circulation plays a crucial role in the regulation of energy homeostasis, by signals that influence the central melanocortin system.[18] These gut hormones cause hunger and satiety effects and thus, have an integral role in appetite regulation. Therefore, a gut-brain axis can be established to maintain and regulate insulin/incretin secretion and glucagon/glucose blood levels. This gut hormones include: glucagon-like peptide-1 (GLP-1), peptide YY (PYY), ghrelin, cholecystokinin (CCK), glucose-dependent insulinotropic polypeptide (GIP), oxyntomodulin (OXM), and pancreatic polypeptide (PP). This hormones act as an incretin by augmenting the insulin response to nutrients and slowing gastric emptying inhibiting the glucagon secretion in a glucose-dependent manner.

Studies performed in laboratory models, GLP-1 has been shown to expand islet mass by stimulating pancreatic β-cell proliferation and induction of islet neogenesis, and it also promotes cell differentiation.[20] A recent study by Laferrère et al showed early after Roux en-Y gastric bypass (RYGB), the greater GLP-1 and GIP release and improvement of incretin effect are related not to weight loss but rather to the surgical procedure itself,[20] suggesting that this could contribute to improved glycemic control after RYGB even in patients with less obesity.

The ghrelin hormone (GH) is a 28 amino acid peptide presenting a unique n-octanoylation modification on its serine in position three, catalyzed by ghrelin O-acyl transferase. Ghrelin is mainly produced by a subset of stomach cells and also by the hypothalamus, the pituitary and other tissues. Transcriptional, translational, and post-translational processes generate ghrelin and ghrelin-related peptides. Homo- and heterodimers of growth hormone secretagogue receptor, and as yet unidentified receptors, are assumed to mediate the biological effects of acyl ghrelin and desacyl ghrelin, respectively. Ghrelin exerts wide physiological actions throughout the body, including growth hormone secretion, appetite and food intake, gastric secretion and gastrointestinal motility, glucose homeostasis, cardiovascular functions, anti-inflammatory functions, reproductive functions and bone formation.

Ghrelin hormone its produced in parietal cells of the fundus of the stomach, thus, in patients that undergo SG, the fundus its removed, improving the weight loss effect and gut hormonal response to GH suppression.

It is been described that GH levels after SG are lower than in patients with RYGB, and the overall evaluation after 12 months, ghrelin levels maintained suppressed and significant suppression after food intake was observed.[22]

BACKGROUND

Several studies and have been performed to establish long-term outcomes for metabolic changes in bariatric surgery, and the main body mass index (BMI) weight loss in different procedures for morbid obese patients.[1,8] And several meta-analysis and randomized trials, have showed that complete and partial remission of diabetes, in morbid obese patients (defined as completely no diabetes medication intake and maintained normalized glucose levels), after 5 years follow-up, its 78%[10] and the reduction of overall death, in this group of patients, its more than 90%.[11]

The effects on weight loss, and metabolic changes between the different bariatric procedures will depend on the patient selection for each procedure, and an adequate preparation and follow-up, regardless of the main BMI of the patient before surgery. And adequate selection of patients to undergo bariatric procedures will improve the patient's outcomes. Therefore, the American Association of Clinical Endocrinologists, The Obesity Society, and American Society for Metabolic and Bariatric Surgery, have already suggested guidelines for bariatric procedures, and suggested that bariatric procedures could be performed in patients ranging from 30 to 34.9 BMI,

with diabetes, and quoting the lack of long-term data to stablish complete and long-term resolution.[9]

The importance of metabolic changes with bariatric procedures have being reported in some studies, such as De Paula[12] et al that have demonstrated an 82% of diabetes resolution, even in normal and overweight patients, with a mean BMI of 23.1 and 28.3 respectively.

There are two main anatomical mechanisms in which bariatric surgery takes its effects. The first it is creating anatomical change to minimize the space of food intake, and creating a hormonal effect, directly changing hunger stimulation by hormones that are produced in specific cells in gastric fundus, such as GH. And the second, it is creating secreting limbs for the gastric and biliopancreatic digestive juices, to bypass a specific gastrointestinal segment that it is responsible of absorptive mechanisms.

There are procedures that are created to stablish this two anatomophysiological effects at the same time, like duodenal switch with pancreatobiliary diversion. And all of this mechanisms have proved to produce adequate glycemic control, with weight loss effects, depending on each procedure, in nonmorbid obese patients and in patients only with overweight patients.[12,14]

Based on this findings the medical-surgical field has encountered a new perspective of clinical outcome. The treatment of metabolic disorders, without obese morbidity.

Several studies have evaluated different types of bariatric procedures. Performed in patients under 35 BMI, even in patients with normal weight, all of them have achieved glycemic control, regardless of weight control mechanisms (Table 1).[13] In some of them, the role of gastric hormones and the relation between gastric anatomy and insulin resistance have been analyzed and described.[3,6,14]

Results in insulin resistance and β-cell dysfunction tests, showed different type of improvements with different procedures. Not all studies have evaluated this variables. But, it described that the nonweight loss effect of bariatric surgery in nonobese patients has an direct impact on the incretin pancreatic-stimulation.[19] Therefore, weight loss has a very important effect on improving insulin sensitivity and reversing MS, even in patients with BMI <30%.

Table 1: Glycemic control in patients that overcome bariatric procedures

Case study	*Cases*	*Female*	*Male*	*Mean BMI*	*% Glycemic control*
M Frenken[15]	16	8	8	32	100
Kwang Yeol Paik[16]	12	4	8	27.9	66
Wu Q, Xiao Z, Cheng Z, Tian H[6]	8	5	3	31.5	83
M Cerci, MI Bellini, F Russo[7]	25	15	10	33.2	86
Ricardo V Cohen[3]	66	40	26	32.5	88
Aureo L DePaula[17]	202	59	143	29.7	86.40
Total	358	131	198	31.13	85

The procedures described in different studies includes RYGB, sleeve gastrectomy, bilio-pancreatic diversion with duodenal switch, and Ileal interposition with sleeve gastrectomy. In Table 1 shows an overall percentage of glycemic control at 12 months period after the procedure have being performed. And some of them describe that patients had achieved glycemic control without medication even before the hospital discharge and 72 hours after surgery.[7] The main percentage of patients that acquire glycemic control, after the procedures, varies from 60 to 100%, with a mean 85%. And the studies vary in the description of DM remission as some authors describe partial remission as main HbA1 <6.5% without diabetes medication, and others <7.0%, and complete remission if HbA1 <5.6%. But the findings in each study have showed, overall, that bariatric procedures are better treatment of long-term patients with DM that medical therapy alone,[21] and surgical treatment will have a direct effect on other comorbidities, resolving hypertension in 58%, sleep apnea in 80%, hypertriglyceridemia resolved in 58%, hypercholesterolemia resolved in 64%,[3] and a prediction of 10 years risk of cardiovascular disease for each patient, calculated using the United Kingdom Prospective Diabetes Study (UKPDS) risk engine,[18] fell substantially after surgery 71%.[3] This are comorbidities of mild obesity that medical therapy for DM itself will not cure.

METHODOLOGY

Source of Data

This study was carried out in Guatemala city in a nutrition, bariatric and metabolic clinic, Metabolik, and the patients that were selected for surgery where operated with minimal access approach in an advanced laparoscopy center. Patients were selected from a multispecialty clinic specialized in diabetes and diabetes complications and over 125 patients charts, 32 where selected as candidates for preoperative evaluation, and 10 patients were selected for surgery.

Study Period

Patients were preselected in a retrospective manner, collecting information in medical records from January 2010 to May 2014. Evaluation of patients preselected was performed during July 2014, and procedures where performed during August to September 2014.

Method of Collection of Data

Information of patients admitted and evaluated with diagnostic and treatment of DM where collected from files.

Patients were selected as candidates based on parameters previously standardized, and they were contacted to perform a re-evaluation of DM diagnostic and treatment. A total of 32 patients where re-evaluated by nutritionist, internal medicine, phycologist, and laparoscopic surgeon. Only 10 patients where candidates for surgery after multispecialty evaluation, surgery information and consent, and contraindication of procedure has being ruled out.

Patients where admitted 24 hours previous to the procedure and stapled sleeve gastrectomy was performed. Invagination of the stapled line was done in all the patients with absorbable continuous intracorporeal suture and drainage was placed in all the patients as well. Gastrography was performed 24 hours after the procedure in all the patients.

Inclusion Criteria

Diagnostic of MS as described above. Tree criteria of five of the NCEP-ATP III definition for the MS. According to the NCEP-ATP III definition, MS is present if three or more of the following five criteria are met: waist circumference over 40" in men or 35" in women, blood pressure over 130/85 mm Hg, fasting TG level over 150 mg/dl, fasting HDL cholesterol level less than 40 mg/dl in men or 50 mg/dl in women and fasting blood sugar over 100 mg/dl or hemoglobin alpha 1 (HbA1) ≥ 7.5%. Because this parameters are based on a different standard physiognomy type, diet, economical status and socioeconomically environment, for this study we used the body mass index (BMI) as parameter of inclusion, and were included patients ranging from BMI > 25 Kg/m² and < 35 Kg/m².

Exclusion Criteria

- Age over 55 years
- Diabetes diagnosed or treatment over 5 years
- Contraindications for surgery over evaluation by specialists.

Postoperative Follow-up

All patients were followed-up 2 weeks, 3, 6 and 12 months after the procedure, performing blood test and nutritional evaluation to gather the data of weight loss and MS criteria. Preoperative and postoperative data are presented.

DATA EVALUATION

Ten patients were operated, 60% (n = 6) male, 40% (n = 4) female (Graph 1). The overall mean age was 36.2 ± 17 years. All of the patients met criteria for MS, being fasting glucose plasma levels the criteria present in 100%, with a mean value of 242.5 mg/dl (f = 239 m = 248) and all the patients with preoperative HbA1 > 7.9 (mean 9.11 ± 1.7) (Graph 2). The mean weight was 52.79 Kg (f = 81.36 m = 82.95) with a BMI of 29.4 Kg/m² (f = 28.69, m = 30.07) (Graph 3). Dyslipidemia was present in 80% of cases with mean TGs and human leukocyte antigen (HLA) of 200.5 mg/dl and 39.3 mg/dl respectively. Diagnostic of hypertension was made with routine blood pressure and was present in 80% of the patients but only four (50%) of them were under treatment. After the procedure, patients were routinely evaluated and data gathered after 12 months period. The mean BMI achieved overall was 22.58 Kg/m² being the minimum 18.8 Kg/m² (f = 22.28, m = 22.44) (Table 3). The total mean weight loss overall was 64.95 ± 12.6 Kg, and the mean percentage of weight loss was 35% of initial weight (Table 2). The hemoglobin A1c below 7% was achieved by 80% of patients and below 6.5% by 60% (Graph 4). Fasting glucose levels decreased overall from 242.80 to 98.50 mg/dl. The overall HbA1 decreased from 9.1% to 6.6%. Triglycerides levels decreased from

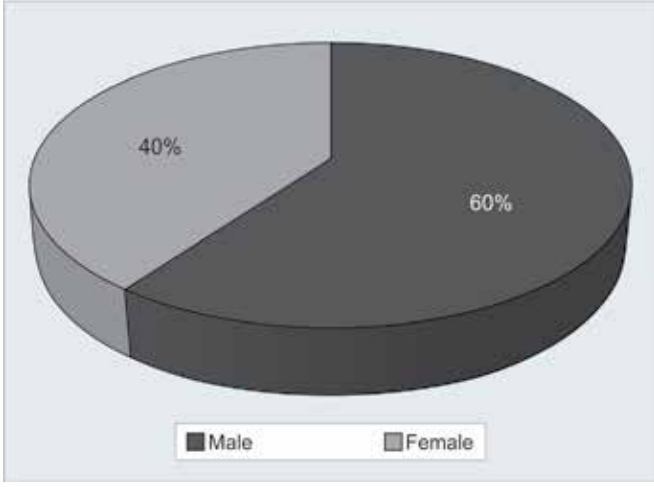

Graph 1: Gender of patients

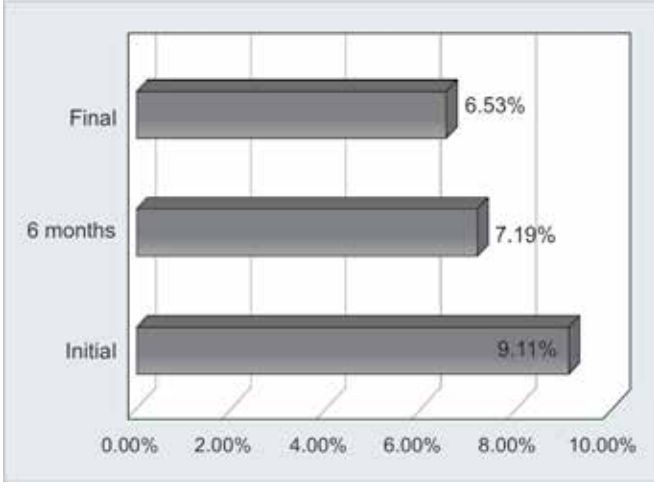

Graph 2: hemoglobin alpha 1 overall improvement after sleeve gastrectomy

Table 2: Total weight loss (kg)

Patient	*Initial*	*6 Months*	*12 Months*	*Total weight loss*	*Percentage*
1	45.45	38.18	27.49	17.96	39.52
2	35.54	28.79	22.45	13.08	36.82
3	38.22	30.96	26.94	11.29	29.53
4	35.95	29.12	21.84	14.11	39.25
5	35.54	28.43	21.61	13.93	39.20
6	32.64	28.07	23.02	9.62	29.48
7	33.47	30.79	25.87	7.60	22.72
8	38.22	30.88	20.07	18.15	47.48
9	40.91	31.09	21.76	19.15	46.80
10	38.22	34.02	28.92	9.31	24.35
Mean	37.42	31.03	24.00	13.42	35.87

Table 3: Body mass index reduction overall

	BMI reduction		
Patient	*Initial*	*6 Months*	*Final*
1	30.86	25.93	22.22
2	27.70	22.44	21.61
3	30.52	28.08	26.55
4	30.89	25.02	23.17
5	30.16	24.13	22.92
6	25.45	21.88	20.87
7	26.40	24.29	22.18
8	29.10	23.57	18.91
9	31.51	23.95	22.06
10	29.79	26.52	25.32
Mean	29.24	24.58	22.58

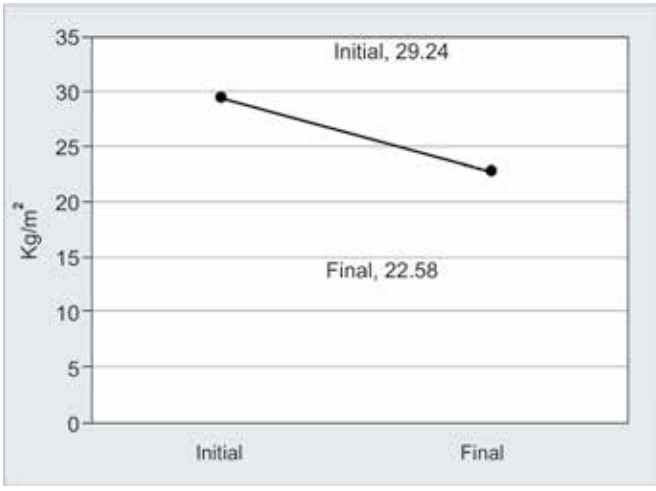

Graph 3: Mean BMI reduction overall

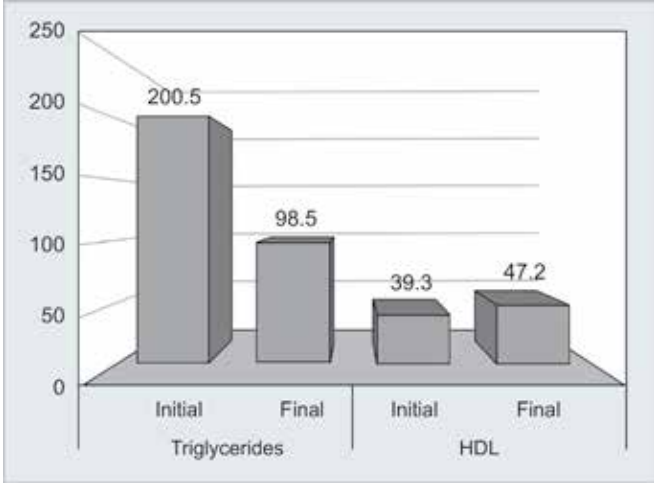

Graph 5: Lipids improvement overall after 12 months

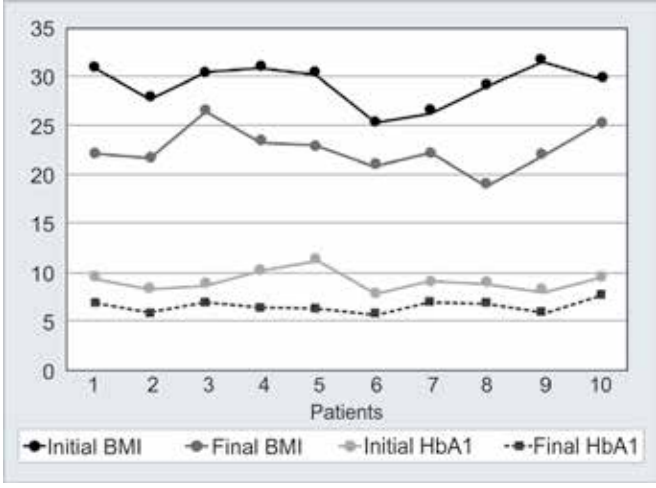

Graph 4: Body mass index and HbAI decrease over 12 months period after sleeve gastrectomy

a mean of 200.5 to 98.5 mg/dl, and mean HDL raised from 39.3 to 47.20 mg/dl (Graph 5). From the 80% of the patients that had hypertension, blood pressure had normalized (<140/90 mm Hg) in 90% of the patients without hypertension treatment. Only one patient continued with oral medication for hypertension and DM but had improvement in the overall clinical evaluation. One patient had gastric leak that was observed and treated with drainage and had to continue with special nutritional support and clinical evaluation during 3 weeks.

CONCLUSION

The MS was diagnosed in 10 patients according to the NCEP-ATP III definition. And the overall outcome of the patients was that 90% of the patients had less than three criteria out of five described to diagnose MS. The total temporary remission without medication of DM was achieved in 60% and no patient suffered from malabsorption complications or went underweight. The overall BMI reduction for nonobese patients with sleeve gastrectomy was 22.6 Kg/m² and the minimum achieved by one patient was 18.91 Kg/m² without complications and with an adequate nutritional evaluation and support. There is still a lot of information to be gathered, and it would make the surgical knowledge even wider, to make international general consensus about the procedures, processes and variables to be analyzed and measured during the surgical treatment of nonobese metabolic patients. But the data gathered so far, indicate that performing a restrictive,

malabsorptive gastrointestinal procedure, can cause a remission of one of the most worldwide challenging illness and improving the quality of life of the patients that undergo a metabolic surgical procedure.

REFERENCES

1. Hubbard VS, Hall WH. Gastrointestinal surgery for severe obesity. Obes Surg 1991;1(3):257-265.
2. Buchwald H, Avidor Y, Braunwald E, et al. 'Bariatric surgery: a systematic review and meta-analysis'. J Am Med Assoc 2004;292(14):1724-1737.
3. Cohen RV, Pinheiro JC, Schiavon CA, Salles JE, Wajchenberg Bl, Cummings DE. Effects of gastric bypass surgery in patients with type-2 diabetes and only mild obesity. Diabetes Care 2012 Jul;35(7):1420-1428.
4. Malapan K, Goel R, Tai CM, Kao YH, Chang PC, Huang CK. Laparoscopic Roux-en-Y gastric bypass for non-obese type II diabetes mellitus in Asian patients. Surg Obesity Related Dis 2014 Sep-Oct;10(5):834-840.
5. Cohen R, Pinheiro JS, Correa JL, Schiavon CA. Laparoscopic Roux-en-Y gastric bypass for BMI < 35 kg/m^2: a tailored approach. Surg Obes Related Dis 2006;2(3):401-404.
6. Wu Q, Xiao Z, Cheng Z, Tian H. Changes of blood glucose and gastrointestinal hormones 4 months after Roux-en-Y gastric bypass surgery in Chinese obese type-2 diabetes patients with lower body mass index. J Diabetes Investig 2013 Mar 18;4(2):214-221.
7. Cerci M, Bellini MI, Russo F, Benavoli D, Capperucci M, Gaspari AL, Gentileschi P. Bariatric surgery in moderately obese patients: a prospective study. Gastroenterol Res Pract 2013 2013;276183.
8. Mingrone G, Panunzi S, Gaetano AD, Guidone C, Iaconelli A. Bariatric surgery versus conventional medical therapy for type 2 diabetes. N Engl J Med 2012 Apr 26;366(17):1577-1585.
9. AACE/TOS/ASMBS guidelines. Clinical practice guidelines for the perioperative nutritional, metabolic, and nonsurgical support of the bariatric surgery patient—2013 update. American Association of Clinical Endocrinologists. The Obesity Society, and American Society for Metabolic and Bariatric Surgery. Endocr Pract 2013 Mar 26.
10. Buchwald H, Estok R, Fahrbach K, Banel D, Jensen MD, Pories WJ, Bantle JP, Sledge I. Weight and T2DM after bariatric surgery: systematic review and meta-analysis. Am J Med 2009 Mar;122(3):248-256.
11. Adams TD, Gress RE, Smith SC, Halverson RC, Simper SC, Rosamond WD, Lanonte MT, Stroup AM, Hunt HC. Long-term mortality after gastric bypass surgery. N Engl J Med 2007 Aug 23;357(8):753-761.
12. De Paula AL, Stival AR, Halpern A, DePaula CCL, Mari A, Muscelli E, Vencio S, Ferrannini E. Improvement in insulin sensitivity and B-cell function following ileal interposition with sleeve gastrectomy in type-2 diabetic patients: potential mechanisms. J Gastrointest Surg 2011 Aug;15(8):1344-1353.
13. De Paula AL, Macedo ALV, Rassi N, Machado CA, Schraibman V, Silva LQ, Halpern A. Laparoscopic treatment of type-2 diabetes mellitus for patients with a body mass index less than 35. Surg Endosc 2008;22:706-716.
14. Dixon JB. Obesity and diabetes: the impact of bariatric surgery on type-2 diabetes. World J Surg 2009 Oct;33(10):2014-2021.
15. Frenken M, Cho EY, Karcz WK, Grueneberger J, Kuesters S. Improvement of type-2 diabetes mellitus in obese and non-obese patients after the duodenal switch operation. J Obesity 2011 Mar 3;2011:860169.
16. Paik KY, Kim W, Song KH, Kwon HS, Kim MK, Kim E. The preliminary clinical experience with laparoscopic duodeno-jejunal bypass for treatment of type-2 diabetes mellitus in non-morbidly obese patients: the 1-year result in a single institute. Surg Endosc DOI: 10.1007/s00464-012-2341-1. 08 June 2012.
17. DePaula AL, Stival AR, DePaula CCL, Halpern A, Vencio S. Surgical treatment of type-2 diabetes in patients with BMI below 35: mid-term outcomes of the laparoscopic ileal interposition associated with a sleeve gastrectomy in 202 consecutive cases. J Gastrointest Surg 2012 May;16(5):967-976.
18. Stevens RJ, Kothari V, Adler AI, Stratton IM. United Kingdom prospective diabetes study (UKPDS) group. The UKPDS risk engine: a model for the risk of coronary heart disease in type-2 diabetes (UKPDS 56). Clin Sci (Lond) 2001;101: 671-679.
19. Ellacott KL, Halatchev IG, Cone RD. Interactions between gut peptides and the central melanocortin system in the regulation of energy homeostasis. Peptides 2006 Feb;27(2): 340-349. Epub 2005 Nov 22.
20. Drucker DJ. Glucagon-like peptides: regulators of cell proliferation, differentiation and apoptosis. Mol Endocrinol 2003 Feb;17(2):161-171.
21. Laferrère B, Teixeira J, McGinty J, et al. Effect of weight loss by gastric bypass surgery versus hypocaloric diet on glucose and incretin levels in patients with type-2 diabetes. J Clin Endocrinol Metab 2008 Jul;93(7):2479-2485.
22. Karamanakos SN, Vagenas K, Kalfarentzos F, Alexandrides TK. Weight loss, appetite suppression, and changes in fasting and postprandial ghrelin and peptide-YY levels after Roux-en-Y gastric bypass and sleeve gastrectomy: a prospective, double blind study. Ann Surg 2008 Mar;247(3):401-407.

10.5005/jp-journals-10033-1253

REVIEW ARTICLE

Efficacy and Safety of Laparoscopic Inguinal Hernia Repair

Michael Angelo L Suñaz

ABSTRACT

Background: Inguinal hernia results from a defect or weakness in the muscles in the inguinal region, through which the peritoneum protrudes, forming the sac. One of the most common operations that general surgeons perform to repair this defect is inguinal herniorrhaphy. Laparoscopic herniorrhaphy started being performed when laparoscopic cholecystectomy has shown definite benefits over the open technique. However, laparoscopic hernia repair is an advanced laparoscopic procedure and has a longer learning curve.[4]

Objectives: (1) To evaluate the efficacy and safety of three laparoscopic hernia repair techniques: Transabdominal preperitoneal (TAPP), totally extraperitoneal (TEP), and intraperitoneal onlay mesh (IPOM). (2) Specifically, this review aims to: (a) Determine which laparoscopic technique has lowest recurrence rate, (b) determine which laparoscopic technique has the least perioperative complications.

Materials and methods: The database used in this study was PubMed and MeSH. Search terms included: laparoscop*, inguinal, hernia, repair, TAPP, TEP and IPOM. Study designs included in this study were prospective clinical studies, and retrospective clinical studies.

Results: All three laparoscopic techniques had complication rates comparable to those of the open techniques. However, recurrence rates after laparoscopic repair was much lower. IPOM, although technically the easiest procedure to perform among the three laparoscopic techniques, is associated with the highest risk of adhesion formation and the lowest tensile strength. In comparison, the TEP and the TAPP techniques had the advantages of better tissue incorporation and tensile strength.

Conclusion: Laparoscopic inguinal herniorrhaphy is an effective method to correct an inguinal hernia but is not without complications nor risk for recurrences. The TAPP, IPOM, and TEP procedures appear to be equally effective. Training, experience, and proper operative technique will prevent some of these complications.

Keywords: Hernia, Inguinal, Laparoscop*, Repair, TAPP, TEP and IPOM.

Resident Fellow

World Laparoscopy Hospital, Cyber City, DLF Phase II, Gurgaon Haryana, India

Corresponding Author: Michael Angelo L Suñaz, Resident Fellow, World Laparoscopy Hospital, Cyber City, DLF Phase II, Gurgaon-122002, Haryana, India, e-mail: prettytiedup@gmail.com

How to cite this article: Suñaz MAL. Efficacy and Safety of Laparoscopic Inguinal Hernia Repair. World J Lap Surg 2015;8(3):81-84.

Source of support: Nil

Conflict of interest: None

INTRODUCTION

Inguinal hernia results from a defect or weakness in the muscles in the inguinal region through which the peritoneum protrudes, forming the sac. One of the most common operations that general surgeons perform to repair this defect is inguinal herniorrhaphy. Laparoscopic herniorrhaphy started being performed when laparoscopic cholecystectomy has shown definite benefits over the open technique. However, laparoscopic hernia repair is an advanced laparoscopic procedure and has a longer learning curve.[4]

In 1982, Ger attempted minimal access groin hernia repair by using Michel clips to close the opening of an indirect inguinal hernia sac. In 1989, Bogojavlensky modified the technique by plugging a polypropylene mesh into the sac and applying an intracorporeal suture on the deep ring. In 1991, Toy and Smoot described a technique of intraperitoneal onlay mesh (IPOM) placement. This involved placement of an intra-abdominal piece of polypropylene or e-PTFE mesh and stapling it over the myopectineal orifice without dissection of the peritoneum.[4]

Stoppa's concept of preperitoneal reinforcement of the transversalis fascia over the myopectineal orifice with its multiple openings by a prosthetic mesh brought about the evolution of the present day techniques of laparoscopic hernia repair. In the early 1990's, Arregui and Doin described the transabdominal preperitoneal (TAPP) hernia repair. During TAPP, the abdominal cavity is first entered followed by the incision of the peritoneum over the posterior wall of the inguinal canal, allowing access into the avascular preperitoneal plane. Adequate dissection is carried out along this plane to allow placement of a large (15 × 10 cm) mesh over the hernia orifices. The peritoneum is carefully sutured or stapled back into place after fixation of the mesh. Transabdominal

*Laparoscop stands for 'Laparoscopy' or 'Laparoscopic' for PubMed result.

preperitoneal (TAPP) repair has the advantage of identifying missed additional direct or femoral hernia during the initial operation.[4]

Phillips and McKernan described the totally extraperitoneal (TEP) technique of endoscopic hernioplasty. The peritoneal cavity is not breached when performing this technique and the entire dissection is performed bluntly in the preperitoneal space using a balloon device or the tip of the laparoscope itself. This procedure requires an advanced knowledge of the posterioranatomy of the inguinal region. Upon completion of dissection, a 15 × 10 cm mesh is stapled in place over the myopectineal orifice.[4]

The mesh is placed in direct contact with the fascia of the transversalis muscle in the preperitoneal space in both the TAPP and TEP repairs, allowing tissue in growths which lead to the fixation of the mesh. This is opposed to the IPOM technique wherein the mesh is merely being brought in contact to the peritoneum and is prone to migrate.[4]

Depending on the type of repair and expertize of the surgeon, recurrence after primary open inguinal herniorrhaphy occurs in approximately 10% of patients. Open repair of the recurrence is challenging because of already weakened tissues and obscured and distorted anatomy leading to a failure rate of as high as 36%. Because of this, focus has been given on repairing these difficult recurrent hernias laparoscopically using a tension-free approach. Some of the earlier reports suggested a low recurrence rate of 0.5 to 5% when a laparoscopic approach was used.[3]

OBJECTIVES

- To evaluate the efficacy and safety of three laparoscopic hernia repair techniques: TAPP, TEP and IPOM
- Specifically, this review aims to:
  - Determine which laparoscopic technique has lowest recurrence rate
  - Determine which laparoscopic technique has the least perioperative complications.

MATERIALS AND METHODS

The database used in this study was PubMed and MeSH. Search terms included: laparoscop*, inguinal, hernia, repair, TAPP, TEP and IPOM.

Study designs included in this study were prospective clinical studies and retrospective clinical studies.

DEFINITION OF TERMS

Transabdominal Preperitoneal Laparoscopic Inguinal Herniorrhaphy

Laparoscopic hernia repair wherein the peritoneum then is incised transversely above the hernia defect, and a complete dissection of the preperitoneal space is accomplished using instruments placed intra-abdominally via accessory ports. Direct sacs are reduced and indirect sacs are either dissected from the cord structures and reduced or divided circumferentially at the internal ring, leaving the distal sac in place. These were accomplished during the course of the preperitoneal dissection. An appropriately sized prosthetic mesh is placed in the preperitoneal space over the hernia defect, overlapping it widely and is either slit to accommodate the cord structures or placed over them. The mesh is then fixed in place using the following landmarks: the symphysis pubis medially, transversalis fascia above the internal ring superiorly, an arbitrary point approximately 1 cm medial to the anterior superior iliac spine laterally, the iliopubic tract inferolaterally, and Cooper's ligament inferomedially before peritoneal closure over the mesh using either staples or sutures, thereby preventing the mesh from coming in contact with intra-abdominal viscera.[2]

Intraperitoneal Onlay Mesh Laparoscopic Herniorrhaphy

Laparoscopic hernia repair wherein the a prosthetic mesh was placed directly onto the peritoneum overlapping the hernia defect widely rather than the preperitoneal space, leaving the hernia sac in place. The same landmarks as described with the TAPP procedure were used for fixing the prosthetic mesh in place.[2]

Totally Extraperitoneal Laparoscopic Herniorrhaphy (Extra)/(TEP)

Laparoscopic hernia repair wherein the skin and fascia at the umbilicus are incised using an open laparoscopic technique, leaving the underlying peritoneum intact. The preperitoneal space is dissected beginning at the umbilicus and continuing inferiorly, creating a 'pneumoextraperitoneum' using CO_2 gas. Additional ports were placed into the extraperitoneal space once the space was sufficiently enlarged, allowing introduction of laparoscopic instrumentation. The abdominal cavity is not entered. Dissection is performed until the hernia defect is encountered and the procedure continued in an identical fashion to the TAPP operation.[2]

DISCUSSION

Catani et al[1] reported their experience on laparoscopic hernioplasty using the IOPM repair in 56 patients. Thirty patients had a monolateral hernia, nine of which were recurrent. Twenty-six had bilateral hernias, six of which were recurrent. A total of 90 hernias were treated. The first 32 cases were repaired with the 'GORETEX Dual Mesh Plus biomaterial with holes'. The 'Corduroy' type was used

to repair the following 24 cases. Meshes were fixed with titanium spiral tacks (Protack, Auto Suture, Tyco Healthcare). There were no noted intraoperative complications and no conversion was necessary. There were five minor postoperative complications (5.5%): Two seromas and three transient paresthesias. Analgesics were needed in four patients (7.1%) after the first 24 hours. Mean hospital stay was 36 hours with a minimum of 24 and a maximum of 48. Resumption of normal activity was within a mean of 8 days with return to work in 2 weeks. Three recurrences were recorded (3.3%) within an average of 18 months of follow-up.

Fitzgibbons et al[2] conducted a multicenter trial to determine if laparoscopic inguinal herniorrhaphy represented a viable alternative to the conventional repair and to assess whether a prospective randomized controlled trial comparing both procedures is warranted. Three types of laparoscopic inguinal herniorrhaphies TAPP, IPOM and TEP (EXTRA) were studied in a phase II design. A total of 21 investigators from 19 institutions participated. There were 686 patients with 869 hernias; 366 (42.1%) were direct, 414 (47.6%) were indirect, 22 (2.5%) were femoral, and 67 (7.7%) were combination hernias. Five hundred and sixty-two hernias underwent TAPP, 217 hernias underwent IPOM, and 87 hernias underwent EXTRA. The overall recurrence rate was 4.5%, with a minimum follow-up of 15 months. Complications were divided into the following three groups: (1) those related to laparoscopy, (2) those related to the patient and (3) those related to the herniorrhaphy. Laparoscopy related complications were noted in 5.4% of patients; there were 31 cases of bleeding or abdominal wall hematomas with two patients requiring transfusions; there was one case of bowel perforation, which was sutured laparoscopically; one bladder injury was managed with open surgery. Patient complications occurred in 6.7% with 5.8% involving the urinary tract. Secondary abdominal procedures had to be performed on two patients for adhesions, one for pain in the right lower quadrant and the other for adhesive small bowel obstruction. The sole mortality (0.1%) was due to a myocardial infarction on postoperative day 5. Complications related to the herniorrhaphy itself were noted in 17.1% of the cases, most of which were minor: transient groin pain (3.5%), seroma (3.5%), transient leg pain (3.3%), hematoma (1.5%), or transient cord or testicular problems (0.9%). As surgeons became more familiar with the anatomy of the nerve supply to the groin when viewed laparoscopically, the incidence of leg pain decreased dramatically. Ninety-three percent of patients were discharged within 24 hours postoperatively.

A study by Phillips et al[5] reported on the complications of 3,229 laparoscopic hernia repairs performed by the authors in 2,559 patients. The TAPP technique was performed 1,944 times (60%), the totally preperitoneal technique was performed 578 times (18%) and the IPOM repair was performed 345 times (11%). The plug-and-patch technique was used 286 times (9%) while simple closure of the hernia defect without mesh was performed 76 times (2%). There were a total 336 complications (10%): 17 major (0.5%) and 265 minor (8%). A total of 54 recurrences (1.6%) were noted, within a mean follow-up of 22 months. The TAPP technique had 19 recurrences (1%) and 141 (7%) complications including four bowel obstructions due to herniation of small bowel through the peritoneal closure and trocar sites. The totally preperitoneal technique had no noted recurrences and 60 complications (10%). Those who underwent IPOM had seven recurrences (2%) and 47 complications (14%). Patients who underwent the plug-and-patch technique had 26 recurrences (9%) and 24 complications (8%). Simple closure of the internal ring had two recurrences (3%) and 10 complications (13%).

Rasim et al[6] conducted a study to evaluate the incidence of adhesion formation and the tensile properties of the various techniques of laparoscopic inguinal herniorrhaphy. The techniques evaluated included laparoscopic extraperitoneal mesh repair (EXTRA), TAPP mesh repair and IPOM repair. Young male pigs underwent mesh placement using the above techniques and had a follow-up for 6 weeks. No trocar site adhesions were observed. In the group that underwent EXTRA technique, no intraperitoneal adhesions were noted. One case of filmy omental adhesions was noted with the TAPP technique. Two cases of adhesions were noted with the IPOM technique, one was minimal while the other was a case of dense adhesions to the bladder. Mesh tensile strength was compared for the three techniques and measured using a tensiometer. Both the EXTRA and TAPP were comparable and significantly stronger ($p < 0.05$), with tensiometric values of 0.69 ± 0.03 and 0.60 ± 0.02 Kg respectively. The IPOM technique resulted in the weakest tensile strength of 0.53 ± 0.01 Kg (mean ± SEM).

Sarli et al[7] conducted a study to evaluate the safety and efficacy of two techniques of laparoscopic hernia repair: the TAPP technique and the IPOM technique. From May 1992 to October 1994, 115 patients with 148 hernias were included in the trial, 59 of which underwent TAPP and 56 underwent IPOM. The TAPP took significantly longer to perform the IPOM. No intraoperative complications, conversions to open repair, nor postoperative deaths were noted in either group. There were 10 postoperative complications in the TAPP group (16.9% of patients) and 14 postoperative

complications in the IPOM group (25% of patients). The difference was not statistically significant. Neuralgias were noted in three cases of TAPP and 11 cases of IPOM ($p < 0.05$), local hematoma in six cases of TAPP and three cases of IPOM (NS), and urinary retention in one case of TAPP and in no case of IPOM (NS). There were no recurrences among those who underwent TAPP and eight recurrences among those who underwent IPOM ($p < 0.01$).

Tetik et al[8] conducted a study as a preliminary review of complications and recurrences associated with laparoscopic repair of groin hernias. Each investigator was given a questionnaire specific for complications. From December 1989 to April 1993, 1,514 hernias were repaired; 119 (7.8%) were bilateral and 192 (12.7%) recurrent. There was a total of 860 indirect, 560 direct, 43 pantaloon, 37 femoral, and six obturator hernias. Eight were not specified. A TAPP mesh technique was used to repair 553 hernias, 457 hernias were repaired with a TEP technique, 320 hernias were repaired with the IPOM technique, 102 hernias were repaired by ring closure, and 82 hernias were repaired using the plug and patch technique. A total of 18 intraoperative and 188 postoperative complications were seen. The total complication rate was 13.6 to 1.2% were intraoperative. Twelve of the intraoperative complications were related to the laparoscopic technique, three were related to the hernia repair, and one was related to anesthesia. The conversion rate to open surgery was 0.8%. Postoperatively, there were 95 local, 25 neurologic, 23 testicular, 23 urinary, 10 mesh, and 12 miscellaneous complications. A total of 34 recurrences (2.2%) after the 1,514 hernia repairs were noted. A 22% recurrence rate was noted after the plug and patch repair *vs* 3, 2.2, 0.7, and 0.4% with the ring closure, IPOM, TAPP and TEP, respectively.

CONCLUSION

Laparoscopic inguinal herniorrhaphy is an effective method to correct an inguinal hernia but is not without complications nor risk for recurrences. The TAPP, IPOM and TEP procedures appear to be equally effective. Training, experience and proper operative technique will prevent some of these complications.

REFERENCES

1. Catani, Marco, Ritanna De Milito, Pietroletti R, Chiaretti M, Spaziani E, Leardi S, Simi M. Is There a Place for Intraperitoneal Onlay Mesh Repair (IPOM) of Inguinal Hernia among Laparoscopic Techniques? Hepatogastroenterol 2004 Oct; 51(59):1387-1392.
2. Fitzgibbons RJ, Camps J, Cornet DA, Nguyen NX, Litke BS, Annibali R, Salerno GM. Laparoscopic inguinal herniorrhaphy. Results of a multicenter trial. Ann Surg 1995 Jan; 221(1):3-13.
3. Memon MA, Feliu X, Sallent EF, Camps J, Fitzgibbons RJ. Laparoscopic repair of recurrent hernias. Surg Endosc 1999 Aug;13(8):807-810.
4. Mishra RK. Textbook of Practical Laparoscopic Surgery. 3 Har/Dvdr edition. New Delhi: Jaypee Brothers Medical Publisher (P) Ltd; 2013.
5. Phillips EH, Arregui M, Carroll BJ, Corbitt J, Crafton WB, Fallas MJ, Filipi C, Fitzgibbons RJ, Franklin MJ, McKernan B. Incidence of complications following laparoscopic hernioplasty. Surg Endosc 1995 Jan;9(1):16-21.
6. Rasim ZM, Alzahrani MA, Sigman HH, Meakins JL, Fried GM. Comparison of adhesion formation and tensile strength after three laparoscopic herniorrhaphy techniques. Surg Laparosc Endosc 1997 Apr;7(2):133-136.
7. Sarli L, Pietra N, Choua O, Costi R, Cattaneo G. Laparoscopic Hernia repair: a prospective comparison of TAPP and IPOM techniques. Surg Laparosc Endosc 1997 Dec;7(6):472-476.
8. Tetik C, Arregui ME, Dulucq JL, Fitzgibbons RJ, Franklin ME, McKernan JB, Rosin RD, Schultz LS, Toy FK. Complications and recurrences associated with laparoscopic repair of groin hernias. A multi-institutional retrospective analysis. Surg Endosc 1994 Nov;8(11):1316-1322.

10.5005/jp-journals-10033-1254

REVIEW ARTICLE

Pregnancy Outcomes following Robot-assisted Laparoscopic Myomectomy

Meghana Jetty

ABSTRACT

Review study question: What are the characteristics of the pregnancy outcomes in women undergoing robot-assisted laparoscopic myomectomy (RALM) for symptomatic leiomyomata uteri?

Summary answer: Despite a high prevalence of women with advanced maternal age, obesity and multiple pregnancy, the outcomes are comparable with those reported in the literature for laparoscopic myomectomy.

Study design: Review study.

Participants/material, setting, methods: An extensive search for articles related to the topic and review the studies.

Main results: The mean time to conception was 12 to 18 months. Assisted reproduction techniques were employed in 22 to 24% of these women. Spontaneous abortions occurred in 18 to 20%. Preterm delivery prior to 35 weeks of gestational age occurred in 17%. One uterine rupture was documented in all studies together. Pelvic adhesions were discovered in 11 to 16% of patients delivered by cesarean section. Higher preterm delivery rates were significantly associated with a greater number of myomas removed and anterior location of the largest incision. None of the myoma characteristics were related to spontaneous abortion.

Keywords: Myomectomy, Pregnancy outcomes, RALM, Robotic surgery.

How to cite this article: Jetty M. Pregnancy Outcomes following Robot-assisted Laparoscopic Myomectomy. World J Lap Surg 2015;8(3):85-89.

Source of support: Nil

Conflict of interest: None

INTRODUCTION

Uterine leiomyomata are common in women of reproductive age.[43] These benign neoplasms may become symptomatic and can result in subfertility among those trying to become pregnant.[31] While hysterectomy is the most frequent surgical treatment for symptomatic myomas,[6] myomectomy is the choice for women desiring uterine preservation or future pregnancies. Although several prospective RCTs have shown that laparoscopic myomectomy results in less postoperative morbidity and faster recovery than open procedures,[21,34,35,37] the majority of myomectomies are still performed by laparotomy. Reluctance to adopt conventional laparoscopy has been attributed to surgical difficulty in enucleating and extracting myomas, and in performing multilayer closure using this technique.[18,36] More recently, robot-assisted laparoscopic myomectomy (RALM) has been performed by surgeons with the expectation that it could improve on the shortcomings of traditional laparoscopy,[1,7] and thereby offer an approach more easily adoptable by gynecologic surgeons with access to a robot.[30] Accumulating evidence suggests that robot-assisted compared with open myomectomy results in less blood loss, fewer complications and faster recovery.[2,3,5] Several studies report that these short-term outcomes are similar for robot-assisted and conventional laparoscopic myomectomy.[7,19,25,26] Data also indicate that robotic techniques can provide a minimally invasive approach to removal of larger, more difficult myomas that are less often attempted with traditional laparoscopic surgery.[5,11] While these studies provide evidence that RALM has favorable short-term outcomes, long-term outcomes, including pregnancy outcomes, have not yet been reported in large series.[20] Pregnancy following myomectomy is usually considered at a higher risk of complications, such as uterine rupture and surgical obstetrical complications associated with the presence of peri-uterine adhesions.[17,24,28] The present article is designed to review the previous investigations to examine pregnancies and perinatal outcomes as they related to characteristics of the myomas in women who underwent RALM.

Junior Consultant

Department of Obstetrics and Gynecology, Apollo Speciality Hospitals, Nellore, Andhra Pradesh, India

Corresponding Author: Meghana Jetty, Department of Obstetrics and Gynecology, Apollo Speciality Hospitals, Nellore Andhra Pradesh, India, e-mail: meghareddy.smile@gmail.com

AIMS AND OBJECTIVES

To review various studies relating to robot-assisted laparoscopic myomectomy and pregnancy outcomes and make a comprehensive understanding of future of RALM.

MATERIALS AND METHODS

Extensive and thorough search was made in Google, PubMed, Highwire press, WALS website, SAGES website, daVinci community, Researchgate.net, Paperity.org, Ncbi

website to identify the papers on robotic surgery, laparoscopic surgery, robot-assisted laparoscopic myomectomy, conventional laparoscopic myomectomy, pregnancy outcomes following robot-assisted laparoscopic myomectomy. Forty-three articles were referred from all sources. Twelve articles were chosen based on following criteria:

- Contemporary articles,
- Published in journals with high impact factor and ranked best in scientific journal ratings,
- High sample size.

The results were tabulated and compared by multivariate model using Statistical Package for Social Sciences (SPSS) software.

RESULTS

During these studies, 872 women underwent robotic myomectomy. One hundred seven subsequently conceived resulting in 127 pregnancies and 92 deliveries through 2011 to 2013. One hundred eight RALM were performed in the 107 women who later conceived. Over 50% of patients were nulligravid and 88.5% were nulliparous. About 10% had undergone a previous myomectomy or a prior cesarean delivery. Thirty-three percent had prior gynecologic procedures (e.g. laparoscopy and dilatation and curettage). Operative time for the daVinci robotic procedure averaged just under 3 hours. Estimated blood loss was generally low, but three women received blood transfusions. The uterine size and the myoma size (greatest dimension) were 12.3 + 3.1 and 7.5 + 3.0 cm, respectively. The myoma weight was 191.7 + 144.8 gm. The number of myomas removed were 3.9 + 3.2 with the largest number being 14. The most common locations of the largest incision were the anterior portion of the uterus, posterior aspect and fundal region. Entry of the myoma into the endometrial cavity occurred in 20% of myomectomies. None of the robotic surgeries resulted in a conversion to laparotomy. A total of 127 pregnancies occurred in the 107 women including seven twin and two triplet pregnancies. The majority of conceptions were spontaneous. The remainder originated from assisted reproduction techniques (ART), with IVF being the most common.

The time to conception was 12 to 18 months. Spontaneous abortions up to 20 weeks occurred in 19% of pregnancies with very few after 14 weeks of gestation. Patient age was unrelated to this outcome. In addition, there were two ectopic pregnancies. Women became hypertensive in 12% of pregnancies. About two-thirds of the women delivered at age 35 years or older with only three women over the age of 43. The gestational age at delivery was 35 to 37 weeks. The majority delivered by cesarean section; 5% delivered vaginally. None required forceps or vacuum assistance. Premature preterm rupture of membranes occurred in seven women. A large proportion of babies were preterm deliveries (up to 35 weeks of gestational age) with 2 at, 28 weeks, 1 at 28 to 32 weeks and 13 from 33 up to 35 weeks. One pregnancy resulted in uterine rupture and fetal demise and another in uterine dehiscence. Abnormal placentation included one occurrence of placenta accreta and one of placenta previa. The placenta accreta did not occur at the site of the hysterotomy incision for the robotic myomectomy. Peri-uterine adhesions were observed in 11% of women who delivered by cesarean section. Malpresentation of the fetus occurred in 10% of births. Estimated blood loss during delivery was 700 to 900 ml. There were five cases of postpartum hemorrhage, two of them requiring blood transfusions. One of the patients requiring transfusion was the patient with a documented uterine rupture. The remaining patients had unremarkable postpartum courses. Birth weight was 2800 to 3100 gm. Apgar scores at 1 and 5 minutes were 8 and 9, respectively. Analysis of the relationship between myomectomy characteristics (number of myomas, myoma size, myoma weight, location, entry into the endometrial cavity and multiple myomectomies) and preterm delivery risk indicated a significantly higher number of myomas removed among women who later had preterm deliveries. Anterior location (of the largest incision) compared with all other sites also was associated with higher preterm delivery rates. Neither patient age nor the characteristics of the myomas were significantly associated with spontaneous abortion or time to conception following myomectomy. Table 1 summarizes the published medical literature on pregnancy outcomes after laparoscopic myomectomy identified through various searches.

DISCUSSION

Women in these series had obstetrical outcomes that were comparable with parameters described in the literature following laparoscopic myomectomy. This is especially reassuring given that the women in this group were generally of advanced maternal age and overweight, and had a high prevalence of infertility and multiple births, all factors that are associated with pregnancy complications.[4,9,13,42] Furthermore, findings at the time of cesarean section revealed a very low rate of pelvic adhesion formation (11%), providing additional evidence to support this minimally invasive approach for treatment of uterine fibroids. Major adverse outcomes were uncommon. However, one case of uterine rupture was reported in this series with a resultant rate of 1.1%. This uterine rupture occurred in a patient who conceived 18 weeks after myomectomy and had no history of prior

Table 1: Pregnancy outcomes following robot-assisted myomectomy identified through various searches

First author (year)	*No. of patients*	*Mean age (yrs)*	*Mean no. of myomas*	*Mean size of largest myoma (cm)*	*Entry into endometrial cavity (%)*	*No. of pregnancies*	*Mean time to pregnancy (months)*	*SAB <20 weeks (%)*	*Live preterm (%)*	*Live term (%)*	*C-section (%)*	*Uterine rupture (%)*
Robotic surgery												
Pritts et al (2013)[31]	107	34.8	3.9	7.5	20.6	127	13.9	18.9	12.6	59.8	95.7	1.1
Lönnerfors et al[20] (2011)	31	35	1	7	NR	18	10	16.7	0	55.6	50	0
Laparoscopic surgery												
Liu et al (2010 and 2011)[18,19]	83	32	NR	5.9	10.8	18	NR	11.1	44.4	44.4	NR	NR
Malzoni et al (2003 and 2010)[22,23]	350	34.3	2.5	6.3	NR	59	NR	13.6	5.1	81.4	55.9	0
Kumakiri et al (2008)[15]	111	NR	3.5	6.6	11.7	111	NR	NR	NR	NR	46.8	NR
Palomba et al (2006)[27]	68	28	1	7.6	NR	36	5	11.1	2.8	86.1	71.9	0
Sizzi et al (2007)[40]	2050	36.1	2.3	6.4	NR	386	NR	19.9	2.3	77.7	78	0.3
Paul et al (2006)[29]	115	30	1	5	7.8	141	8.9	19.9	2.1	73	82.1	0
Seracchioli et al (2003 and 2006)[38,39]	127	33.7	2.6	5.4	3.9	158	17.9	27.2	1.3	65.8	74.5	0
Kumakiri et al (2005)[14]	40	34.5	3.2	6.8	5	47	13	23.9	2.2	67.4	40.6	0
Campo et al (2003)[8]	68	34.3	2.9	4.4	NR	14	NR	7.1	0	92.9	30.8	0
Soriano et al (2003)[41]	88	36.1	1.7	6.2	0	44	7.5	13.6	0	77.3	23.5	0

NR: No result; C-section: Cesarean section; No: Number

abdominopelvic surgery. Ten myomas were removed weighing 256 gm, with the largest 10 cm in diameter on the anterior surface of the uterus. The endometrial cavity was not entered. Hysterotomies were performed using a monopolar electrosurgical instrument, and a multilayered closure was performed. The uterine rupture occurred on the posterior fundal aspect of the uterus at 33 weeks of gestation during precipitous labor. In addition, one uterine dehiscence was noted at the time of delivery as an incidental finding and occurred in a patient with no remarkable surgical history or myoma characteristics. In the series, 34% of myomectomies were performed using monopolar electrosurgical energy. The rate of uterine rupture in this study is consistent with data reported for laparoscopic and open myomectomy, and lower than the estimated risk of uterine rupture after a classical cesarean section.[12,43,44] In a recent review of risk factors for uterine rupture after laparoscopic myomectomy, Parker et al (2010)[28] identified minimizing the use of electrosurgery and performing multilayered closures as techniques that could decrease the risk of rupture. An advantage of RALM is the ability to perform an identical multilayer closure to the abdominal approach that controls hemostasis without the need for significant use of electrosurgical instruments. Owing to the risks of electrosurgery, ultrasonic energy can be utilized with the robot to perform the hysterotomy.[45,46] The robotic harmonic shears are unable to articulate in a similar manner to all other robotic instruments, thus losing 2 of the 7° of freedom in movement. The observed miscarriage rate (19%) was in the range of rates reported in the conventional laparoscopic myomectomy literature and was lower than the 28% shown by Lonnerfors and Persson (2011)[20] in their prospective study of pregnancy in 31 women following robotic surgery for deep intramural myomas: results in the latter report also indicated that all miscarriages occurred in pregnancies resulting from IVF. In contrast, the data show that miscarriages up to 20 weeks were about evenly divided among those who conceived spontaneously and those who used ART. Myoma number and anterior location were significantly associated with preterm delivery up to 35 weeks of gestational age, even after adjustment for other risk factors for preterm delivery. The published myomectomy literature has limited comparable data but Roemisch et al (1996)[33] reported that women who delivered at term had significantly fewer myomas than the group of women who delivered preterm, miscarried or had ectopic pregnancies. Given that this population often desires fertility and that adhesions are known to cause infertility,[10] it is an advantageous finding that the risk of adhesions may be lower than has been reported in both abdominal myomectomy and laparoscopic myomectomy patients.[16,32,33,47] Since adhesion formation following myomectomy may reduce fertility, formal second-look laparoscopic studies in non-pregnant women following RALM may be needed for a more definitive measure of postoperative adhesion formation. A limitation of our study is the inability to generalize these findings to other practices. The use of magnetic resonance imaging (MRI) to determine the exact location of the myomas removed and also suturing of the hysterotomy defect in a multilayered fashion help to minimize excessive bleeding, which typically results in conversions. In addition, the women in these studies

were generally of advanced maternal age, overweight and obese, and had a high prevalence of infertility treatment and multiple births. These risk factors have been associated with higher rates of miscarriage, hypertensive complications, gestational diabetes and preterm delivery.[4,9,13,42] Furthermore, women who have IVF pregnancies are also at a higher risk for having preterm deliveries and infants of low birthweight.[13,48] Additionally, given the absence of pregnancy outcome data after robotic myomectomy in the literature, obstetricians conservatively managed these pregnancies as if they had prior classical cesarean sections. The present review observed pregnancy outcomes after RALM that were comparable with those reported in the conventional laparoscopic literature. Robotic surgical techniques can overcome some of the shortcomings of traditional laparoscopy,[5] thus facilitating the use of minimally invasive surgery over laparotomy for more gynecologic surgeons.[30] This enabling treatment modality may offer a minimally invasive alternative for uterine preservation for women with uterine fibroids.

CONCLUSION

Robot-assisted laparoscopic myomectomy is a safe route of myomectomy. It is superior in terms of lesser tissue trauma, better suturing, better hemostatsis. Pregnancy outcomes are also comparable to laparoscopic myomectomy. There is actually lower adhesion rate and better pregnancy outcome when compared to laparoscopic and abdominal myomectomy. But further studies are needed to know the long-term effects. Presently, it is the safest method of myomectomy.

REFERENCES

1. Advincula AP, Song A, Burke W, Reynolds RK. Preliminary experience with robot-assisted laparoscopic myomectomy. J Am Assoc Gynecol Laparosc 2004;11(4):511-518.
2. Advincula AP, Xu X, Goudeau S, Ransom SB. Robot-assisted laparoscopic myomectomy: a comparison of short-term surgical outcomes and immediate costs. J Minim Invasive Gynecol 2007;14(6):698-705.
3. Ascher-Walsh CJ, Capes TL. Robot-assisted laparoscopic myomectomy with a limited number of myomas. J Minim Invasive Gynecol 2010;17(3):306-310.
4. Baetan JM, Buskusi EA, Lambe M. Pregnancy complications and outcomes among overweight and obese nulliparous women. Am J Public Health 2001;91(3):436-440.
5. Barakat EE, Bedaiwy MA, Zimberg S, Nutter B, Nosseir M, Falcone T. Robotic-assisted, laparoscopic, and abdominal myomectomy: a comparison of surgical outcomes. Obstet Gynecol 2011;117(2 pt 1):256-265.
6. Becker ER, Spalding J, Duchane J, Horowitz IR. Inpatient surgical treatment patterns for patients with uterine fibroids in the United States, 1998-2002. J Natl Med Assoc 2005;97(10): 1336-1342.
7. Bedient CE, Magrina JF, Noble BN, Kho RM. Comparison of robotic and laparoscopic myomectomy. Am J Obstet Gynecol 2009;201(6):566e1-566e5.
8. Campo S, Camp V, Gambadauro P. Reproductive outcomes before and after laparoscopic or abdominal myomectomy for subserous or intramural myomas. Eur J Obstet Gynecol Reprod Biol 2003;110(2):215-219.
9. Cleary-Goldman J, Malone FD, Vidaver J, Ball RH, Nyberg DA, Comstock CH, Saade GR, Eddleman KA, Klugman S, Dugoff L, et al. Impact of maternal age on obstetric outcome. Obstet Gynecol 2005;105(5 pt 1):983-990.
10. Diamond MP, Freeman ML. Clinical implications of postsurgical adhesions. Hum Reprod Update 2001;7(6):567-576.
11. Dubuisson JB, Chapron C, Chavet X, Gregorakis SS. Fertility after laparoscopic myomectomy of large uterine myomas: preliminary results. Hum Reprod 1996;11(3):518-522.
12. Dubuisson JB, Fauconnier A, Deffarges JV, Norgaard C, Kreiker G, Chapron C. Pregnancy outcome and deliveries following laparoscopic myomectomy. Hum Reprod 2000;15(4): 869-873.
13. Jackson RA, Gibson KA, Wu YW, Croughan MS. Perinatal outcomes in singletons following in vitro fertilization: a meta-analysis. Obstet Gynecol 2004;103(3):551-563.
14. Kumakiri J, Tekeuchi H, Kitade M, Kikuchi I, Shimanuki H, Itoh S, Kinoshita K. Pregnancy and delivery after laparoscopic myomectomy. J Minim Invasive Gynecol 2005;12(3):241-246.
15. Kumakiri J, Takeuchi H, Kitade M, Kikuchi I, Takeda S. Prospective evaluation for the feasibility and safety of vaginal birth after laparoscopic myomectomy. J Minim Invasive Gynecol 2008;15(4):420-424.
16. Kumakiri J, Kikuchi I, Kitade M, Matsuoka S, Kono A, Ozaki R, Takeda S. Association between uterine repair at laparoscopic myomectomy and postoperative adhesions. Acta Obstet Gynecol Scand 2012;91(3):331-337.
17. Landi S, Fiaccavento A, Zaccoletti R, Barbieri F, Syed R, Minelli L. Pregnancy outcomes and deliveries after laparoscopic myomectomy. J Am Assoc Gynecol Laparosc 2003;10(2): 177-181.
18. Liu G, Zolis L, Kung R, Melchoir M, Singh S, Cook EF. The laparoscopic myomectomy: a survey of Canadian gynecologists. J Obstet Gynaecol Can 2010;32(2):139-148.
19. Liu L, Li Y, Xu H, Chen Y, Zhang G, Liang Z. Laparoscopic transient uterine artery occlusion and myomectomy for symptomatic uterine myoma. Fertil Steril 2011;95(1):254-258.
20. Lonnerfors C, Persson J. Pregnancy following robot-assisted laparascopic myomectomy in women with deep intramural myomas. Acta Obstet Gynecol Scand 2011;90(9):972-977.
21. Mais V, Ajossa S, Guerriero S, Mascia M, Solla E, Benedetto G. Laparoscopic versus abdominal myomectomy: a prospective, randomized trial to evaluate benefits in early outcome. Am J Obstet Gynecol 1996;174(2):654-658.
22. Malzoni M, Rotondi M, Perone C, Labriola D, Ammaturo F, Panariello S, Reich H. Fertility after laparoscopic myomectomy of large uterine myomas: operative technique and preliminary results. Eur J Gynecol Oncol 2003;24(1):79-82.
23. Malzoni M, Tinelli R, Cosentino F, Iuzzolino D, Surico D, Reich H. Laparoscopy versus minilaparotomy in women with symptomatic uterine myomas: short-term and fertility results. Fertil Steril 2010;93(7):236-273.
24. Miller CE, Johnston M, Rundell M. Laparoscopic myomectomy in the infertile woman. J Am Assoc Gynecol Laparosc 1996;3(4):525-532.

25. Nezhat CH, Nezhat F, Roemisch M, Seidman DS, Takuke SI, Nezhat CR. Pregnancy following laparoscopic myomectomy: preliminary results. Hum Reprod 1999;14(5):1219-1221.
26. Nezhat C, Lavie O, Hsu S, Watson J, Barnett O, Lemvre M. Robotic-assisted laparoscopic myomectomy compared with standard laparoscopic myomectomy—a retrospective matched control study. Fertil Steril 2009;91(2):556-559.
27. Palomba S, Zupi E, Falbo A, Russo T, Marconi D, Tolino A, Manguso F, Mattei A, Zullo F. A multicenter randomized, controlled study comparing laparoscopic versus minilaparotomic myomectomy: reproductive outcomes. Fertil Steril 2007;88(4):933-941.
28. Parker WH, Einarsson J, Istre O, Dubuisson JB. Risk factors for uterine rupture after laparoscopic myomectomy. J Minim Invasive Gynecol 2010;17(5):551-554.
29. Paul PG, Koshy AK, Thomas T. Pregnancy outcomes following laparoscopic myomectomy and single-layer myometrial closure. Hum Reprod 2006;21(12):3278-3281.
30. Payne TN, Pitter MC. Robotic-assisted surgery for the community gynecologist: can it be adopted? Clin Obstet Gynecol 2011;54(3):391-411.
31. Pritts EA, Parker WH, Olive DL. Fibroids and infertility: an updated systematic review of the evidence. Fertil Steril 2009;91(4):1215-1223.
32. Ribeiro SC, Reich H, Rosenberg J, Guglielminetti E, Vidali A. Laparoscopic myomectomy and pregnancy outcome in infertile patients. Fertil Steril 1999;71(3):571-574.
33. Roemisch M, Nezhat FR, Nezhat A. Pregnancy after laparoscopic myomectomy. J Am Assoc Gynecol Laparosc 1996; 3(4-Suppl):S42.
34. Rossetti A, Sizzi O, Soranna L, Mancuso S, Lanzone A. Fertility outcome: long-term results after laparoscopic myomectomy. Gynecol Endocrinol 2001;15(2):129-134.
35. Seinera P, Farina C, Todros T. Laparoscopic myomectomy and subsequent pregnancy: results in 54 patients. Hum Reprod 2000;15(9):1993-2000.
36. Senapati SS, Advincula AP. Surgical techniques: robot-assisted laparoscopic myomectomy with the da Vinciw surgical system. J Robotic Surg 2007;1(1):69-74.
37. Seracchioli R, Rossi S, Govoni F, Rossi E, Venturoli S, Bulletti C, Flamigni C. Fertility and obstetric outcome of large myomata: a randomized comparison with abdominal myomectomy. Hum Reprod 2000;15(12):2663-2668.
38. Seracchioli R, Colombo FM, Bagnoli A, Govoni F, Missiroli S, Venturoli S. Laparoscopic myomectomy for fibroids penetrating the uterine cavity: is it a safe procedure? Br J Obstet Gynaecol 2003;110(3):236-240.
39. Seracchioli R, Manuzzi L, Vianello F, Gualerzi B, Savelli L, Paradisi R, Venturoli S. Obstetric and delivery outcome of pregnancies achieved after laparoscopic myomectomy. Fertil Steril 2006;86(1):159-165.
40. Sizzi O, Rossetti A, Malzoni M, Minelli L, La Grotta F, Soranna L, Panunzi S, Spagnolo R, Imperato F, Landi S, et al. Italian multicenter study on complications of laparoscopic myomectomy. J Minim Invasive Gynecol 2007;14(4):453-462.
41. Soriano D, Dessolle L, Poncelet C, Benifla JL, Madelanat P, Darai E. Pregnancy outcome after laparoscopic and laparo-converted myomectomy. Eur J Obstet Gynecol Reprod Biol 2003;108(2):194-198.
42. Spellacy WN, Handler A, Ferre CD. A case-control study of 1253 twin pregnancies from a 1982–1987 perinatal data base. Obstet Gynecol 1990;75(2):168-171.
43. Stewart EA. Uterine fibroids. Lancet 2001;357(9252):293-298.
44. Stotland N, Lipschitz L, Caughey A. Delivery strategies for women with a previous classic cesarean delivery: a decision analysis. Am J Obstet Gynecol 2002;187(5):1203-1208.
45. Stringer NH, Walket JC, Meyer PM. Comparison of 49 laparoscopic myomectomies with 49 open myomectomies. J Am Assoc Gynecol Laparosc 1997;4(4):457-464.
46. Stringer NH, Strassner HT, Lawson L, Oldham L, Estes C, Edwards M, Stringer EA. Pregnancy outcomes after laparoscopic myomectomy with ultrasonic energy and laparoscopic suturing of the endometrial cavity. J Am Assoc Gynecol Laparosc 2001;8(1):129-136.
47. Tinelli A, Malvasi A, Guido M, Tsin DA, Hudelist G, Hurst B, Stark M, Mettler L. Adhesion formation after intracapsular myomectomy with or without adhesion barrier. Fertil Steril 2011;95(5):1780-1785.
48. Tomic V, Tomic J. Neonatal outcome of IVF singletons versus naturally conceived in women aged 35 years and over. Arch Gynecol Obstet 2011;284(6):1411-1416.

10.5005/jp-journals-10033-1255

REVIEW ARTICLE

Surgical Approaches for Rectal Prolapse and their Comparative Study

Inamull Hasan SA Shaikh

ABSTRACT

Rectal prolapse is a distressing condition often affecting elderly patients. Open rectopexy has a proven track record in the treatment of this condition but may be complicated by significant morbidity. The benign nature of the disease and reduced pain and pulmonary complications of the laparoscopic approach makes this an attractive operation in this patient group. Laparoscopic prosthesis fixation rectopexy and lateral ligament suspension with and without colectomy have been described with low recurrence rates, good patient acceptability, symptom improvement, on both radiological and physiological assessments. Currently, the laparoscopic approach with ventral mesh rectopexy or resection rectopexy is the two most commonly used techniques. As high quality evidence is missing, an individualized approach is recommend for every patient considering age, individual health status and the underlying morphological and functional disorders.

Keywords: Laparoscopy, Mesh rectopexy, Rectal prolapse, Resection rectopexy, Suture rectopexy.

How to cite this article: Shaikh IHSA. Surgical Approaches for Rectal Prolapse and their Comparative Study. World J Lap Surg 2015;8(3):90-95.

Source of support: Nil

Conflict of interest: None

INTRODUCTION

Complete rectal prolapse is defined as protrusion of all layers of the rectum through the anal canal, full thickness rectal prolapse (FRP). A protrusion of mucosa only is called mucosa prolapse (MP).

A common classification divides three grades as follows:

1. *Rectal prolapse I°:* Inner (recto-rectal) intussusception of the rectum proximal of the anal canal;
2. *Rectal prolapse II°:* Inner (recto-anal) intussusception into the anal canal;
3. *Rectal prolapse III°:* Prolapse of the rectum beyond the anus (external prolapse).

Private Practitioner

Department of General Surgery, Shaikh Polyclinic and Imad Nursing Home, Raigad, Maharashtra, India

Corresponding Author: Inamull Hasan SA Shaikh, Private Practitioner, Department of Surgery, Shaikh Polyclinic and Imad Nursing Home, Mahad, Raigad, Maharashtra, India, Phone: 09970564719, e-mail: surgeongroup@gmail.com

The etiology is unclear. Rectal prolapse is often associated with obesity, pregnancy, chronic constipation and other conditions that lead to increased abdominal pressure.

The most common anatomic varieties in patients with rectal prolapse are redundant sigmoid, diastases of the elevator ani, loss of the vertical position of the rectum and its sacral attachments and a deep cul-de-sac.[1,2] A rectal prolapse I° is seen in 20 to 50% of healthy individuals.[3,4]

OPERATION PROCEDURES

Multiple operations have been described for the rectal prolapse. In the following section, techniques and results of operations as far as they are performed laparoscopically are explained and rated (Table 1).

The aim of the operation generally is to correct the morphologic alteration, and thereby treat the symptoms of the patient, e.g. improve incontinence or constipation and incomplete emptying, depending on what major symptoms the patient is suffering from. This can be achieved by three ways:

1. Fixation of the rectum (rectopexy);
2. Resection or plication of redundant bowel; and
3. Mobilization of the rectum. Most operations combine the two principles of rectal mobilization and rectopexy, some operations add bowel resection.

The approach can be trans anal/perineal or transabdominal. Abdominal operations seem to result in lower recurrence rates but there are no randomized controlled trials substantiating this.[5,6] Perineal procedures avoid laparotomy/laparoscopy, and therefore, may have a lower operative risk and morbidity. They may, therefore, be more suitable for older or high-risk patients with a relevant co-morbidity, although again there are no adequately powered RCTs to back these recommendations up.

Virtually all abdominal procedures that were originally described via laparotomy can also be performed laparoscopically. The laparoscopic surgery of rectal prolapse was first introduced in 1992 and consisted of a sutureless rectopexy with staples without bowel resection. In the meantime, besides the conventional laparoscopic approach, there are new reports of a robotic-assisted approach with the da Vinci system.[7,8] The transabdominal operations differ mainly in the extent of rectal mobilization, the method of rectal fixation and the additional sigmoid resection.

Table 1: Abdominal procedures for rectal prolapse

Type of procedure	*Operation technique*
Suture rectopexy (Sudeck)	Complete rectal mobilization to level of levators
	Suture of rectum to presacral fasica
Anterior sling rectopexy (Ripstein)	Complete rectal mobilization to level of levators circular wrapping of mesh around rectum and attachment to the promontory
Lateral mesh rectopexy (Orr-Loygue)	Anterior + posterior complete rectal mobilization fixation by two lateral mesh strips to promontory
Ventral mesh rectopexy (D'Hoore)	Strictly anterior rectal dissection to level of levators
	Fixation of mesh strip on distal rectum and to promontory
Posterior mesh rectopexy (Wells)	Complete rectal mobilization to level of levators
	Semicircular mesh around rectum posterior, fixation to promontory
Resection rectopexy (Frykman-Goldberg)	Complete rectal mobilization to level of levators sigmoid resection and suture fixation of rectum to promontory
Rectal mobilization without rectopexy	Complete rectal mobilization to level of levators no fixation

RECTOPEXY

The fixation of the rectum to the sacrum is supposed to restore the physiological position of the rectum, and thereby also correct the descensus of the pelvic floor either by simple stitching, stapling or by meshes.

SUTURE RECTOPEXY (SUDECK) (1922)

The operation includes a complete mobilization of the rectum down to the level of the levators. The rectum is then attached to the promontory by suture or staples. The dorsal mobilization induces fibrosis which helps to fixate and hold the rectum in place.[9]

RECTOPEXY WITH MESH OR GRAFT

A mesh or graft is used to achieve a broader fixation and induce more fibrosis. Used materials include fascia lata, synthetic meshes and bio-meshes.[10] The mesh can be placed anteriorly, posteriorly, laterally or around the rectum.

ANTERIOR MESH RECTOPEXY (RIPSTEIN SLING RECTOPEXY) (1952)

After complete mobilization of the rectum a graft constructed out of the fascia lata was wrapped around the rectum and sutured to the promontory. Later instead of a fascia lata graft, synthetic meshes are used.

There is only one case report on this procedure using a laparoscopic approach which found a good clinical outcome (no morbidity, no recurrence).[11]

LATERAL MESH RECTOPEXY (ORR-LOYGUE)

In this procedure, the rectum is completely mobilized anteriorly and posteriorly. Two mesh strips are sutured laterally to the rectum on both sides. The mesh strips are then sutured under tension to the promontory.[12]

POSTERIOR MESH RECTOPEXY (WELLS)

After a complete mobilization of the rectum a mesh is placed around the posterior circumference of the rectum (2/3), and then fixed to the promontory. The ventral third of the rectal circumference is spared to avoid fibrosis and stenosis by shrinking of the mesh.

VENTRAL MESH RECTOPEXY (D'HOORE) (2004)

It's a novel, autonomic nerve-sparing rectopexy technique. The dissection in this operation is strictly ventral in the rectovaginal space down to the pelvic floor without lateral or dorsal mobilization. The rectum is attached to the sacrum by a mesh which is sutured to the anterior side of the rectum. The ventral dissection and position of the mesh has several advantages:

- A supra-anal rectocele can be corrected
- The rectovaginal septum is reinforced which prevents an anterior recto-rectal intussusception which may be one of the relevant mechanisms to a full rectal prolapse
- A colpopexy is performed. The avoidance of any lateral or posterior mobilization preserves the autonomic nerves.[13]

Although laparoscopic ventral rectopexy (LVR) is a comparably new method it was rapidly adopted and up to now, more than 30 retro- and prospective series have reported outcome and postoperative function. Two systematic reviews have summarized the data.

Indications for the procedures were intussusception as well as overt rectal prolapse, rectocele, obstructive defecation syndrome (ODS) and vaginal vault prolapse.

RESECTION RECTOPEXY (FRYKMAN-GOLDBERG)

A sigmoid resection is combined with a rectopexy, mostly a sutured rectopexy. The resection results in the following morphologic changes:

- An area of fibrosis develops around the anastomosis and the sacrum which leads to a rectal fixation to the sacrum
- The colon lies in a straighter course which avoids torsion and sigmoidocele.[14]

Especially in patients with an elongated sigmoid and slow-transit constipation it is postulated that constipation improves through the resection of redundant colon (Table 2).

ROLE OF ABDOMINAL PROCEDURES AND LAPAROSCOPY

A recent survey asked 391 surgeons over 50 countries for their preferred method for the treatment of rectal prolapse. It revealed that 60% of surgeons would treat healthy patients with an external prolapse with a laparoscopic abdominal procedure, 20% would chose an abdominal method via laparotomy and only 20% favored a perineal approach. For internal prolapse still 40% of the surgeons preferred laparoscopy. While in Europe LVR is the most popular treatment for external prolapse, surgeons in North America favor laparoscopic resection rectopexy (LRR).[15]

An expert consensus paper published in 2013 explicitly recommends a laparoscopic or robotic approach for ventral rectopexy.[16]

But, the learning curve for laparoscopic colorectal surgery has been found to be around 150 to 200 cases for achieving a constant level of proficiency.[17,18] This also seems to apply to laparoscopic rectopexy.

COMPARISON OF LAPAROSCOPIC AND OPEN PROCEDURES

Evidence from randomized studies that compared laparoscopic with open rectopexy is rare. A Cochrane systematic review from 2008 found that the laparoscopic approach resulted in fewer postoperative complications and a shorter hospital stay compared to the open approach. But, these findings are based on only two randomized studies comprising altogether 60 patients. Both studies used a ventral mesh fixation without resection (Table 3).[19-21]

DISCUSSION

Postoperative major complications were only cardiorespiratory and occurred only in the group with an open operation. A faster recovery (return to solid diet) and a reduced requirement for morphine were found for the laparoscopic group, which altogether resulted in a shorter hospital stay. But, no difference was found for functional parameters (incontinence, constipation, rectal capacity, anal squeeze pressure) and recurrence rates.

Table 2: Outcome of laparoscopic procedures for pelvic floor disorders

	Minor compl. (%)	*Major compl. (%)*	*Mortality (%)*	*Conversion (%)*	*Incontinence (%)*	*Constipation (%)*	*Recurrence (%)*
LSR	0–16	2–11	0	0–5	48–82 (+)	11(–)–70% (+)	2–20
LMR	0–5	0–3	0	0–5	76–92 (+)	38(–)–36% (+)	1.3–6
LVR	0–36	0–5	0–0.4	0–7.4	70–90 (+)	60–80% (+)	0–14
LRR	11–21	0–4	0–0.8	0–6	62–94 (+)	53–80% (+)	0–11

Table 3: Comparative rectopexy studies (open *vs* laparoscopic, different procedures)

Study	*Procedure*	*Patients*	*Results*
Sajid (2009)	LR	330	No difference in Mort, Morb, Inc, Cons, recurrence shorter hospital stay for LR
Meta-analysis (12 studies) different procedures	OR	358	Shorter operation times for OR
Caddedu (2012)	LR	192	No difference in Mort, Morb, Inc, Cons, recurrence
Meta-analysis (8 studies) different procedures	OR	275	
Senapeti (2013)	SR	38	No difference in morbidity, recurrence and functional outcome
Randomized	RR	40	
Forminje (2014)	LVR	40	More minor complications in LRR
Retrospective	LRR	28	No difference in major complications, recurrence and functional outcome
Sahoo (2014)	LPR	38	No differences in morbidity, recurrence and functional outcome
Retrospective	LSR	32	
Lechaux (2004)	LRR	13	Significant more patients with worsening of constipation in the LMR-group (26 *vs* 8%)
Prospective	LMR	35	No differences in morbidity and improvement of continence
Madbouly (2002)	LRR	12	No difference in complications and functional outcome
Prospective	LPR	12	

Data from studies that compare open *vs* laparoscopic rectopexies or studies that compare different procedures, Mort: Mortality; Morb: Morbidity; Incontinence: Fecal incontinence; Cons: Constipation; LR: Laparoscopic rectopexy; OR: Open rectopexy; SR: Suture rectopexy; RR: Resection rectopexy; LPR: Laparoscopic posterior mesh rectopexy; HS: Hospital stay; OT: Operation time

Two case controlled studies compared open and laparoscopic surgery for rectal prolapse. Kairaluoma et al[22] used different procedures in 106 patients (LRR, suture rectopexy, Wells rectopexy). A longer operation time (170 *vs* 100.5 min) but a shorter hospital stay (5 *vs* 7 days) was found for laparoscopy. Functional outcome, recurrence rates and complications did not differ between case- and control-group. Kariv et al[23] found similar results. In this study, also different techniques were applied. One third of patients in each group had resection rectopexy respectively suture rectopexy respectively mesh rectopexy (predominantly Ripstein anterior rectopexy for open surgery, Well's procedure in laparoscopic surgery). Incontinence and constipation improved in all patients, with a significant higher improvement in the laparoscopic group (74 *vs* 54%). A likely explanation for this finding was the much more frequent use of the Ripstein procedure in the open surgery group where the circular anterior mesh placement can result in a stenosis which obviously in turn contributes to the occurrence of constipation.[24] For this reason, a circular mesh placement is now considered obsolete by most authors.

de Hoog et al[25] compared open rectal prolapse surgery to a conventional laparoscopic and a robot-assisted approach in a prospective non-randomized setting. Half of the patients were operated with the Well's procedure, the other half with a ventral rectopexy. While the functional outcome (incontinence, constipation) improved significantly in all three groups, the recurrence rates during a 2-year follow-up were significantly increased in the robot-assisted (20%) and the conventional laparoscopic group (27%) *vs* 2% in the open group.

In a recent meta-analysis, 12 comparative studies comprising 688 patients (330 with laparoscopic rectopexy) were analyzed.[26] A drawback of this meta-analysis was that only one study was randomized and that several different procedures (resection, non-resection) were used even within studies. Nevertheless a significant shorter hospital stay was found for the laparoscopic group, while no differences between the open and laparoscopic approach were found for complication rates, postoperative functional outcome, recurrence rates and mortality. A meta-analysis from 2012 showed the same results.[27]

LAPAROSCOPIC RECTOPEXY IN ELDERLY PATIENTS

It is thought that the group of elderly patients especially profits from laparoscopic surgery. A recent systematic review showed significant advantages in short-term outcome in laparoscopic colorectal surgery for elderly people.[28] As the incidence of rectal prolapse and pelvic floor disorders increases with age it is important to know if laparoscopic procedures are safe for this group of patients and if they offer a good alternative to perineal procedures.

For ventral rectopexy, a recent French study evaluated 4303 patients from a national database. Patients aged more than 70 years were compared to patients younger than 70 years. Elderly patients had more minor complications (urinary, wound complications) and a longer hospital stay, but major complication rate and mortality were not different.[29] Another study used a modified laparoscopic Orr-Loygue technique in 46 elderly patients (median age 83 years) with rectal prolapse. A significant cardiac morbidity was observed. Two patients died of cardiac arrest. Two patients were re-operated for recurrent prolapse after 2 months. The reasons for the recurrences were mesh dislocations. Faecal incontinence improved significantly (Wexner-Score decreased from 19 to 5 points after 1 year). Constipation did not improve. Most patients were satisfied with the operation, but there was no association seen between satisfaction and functional result.[30]

A German study from 2012 studied the outcome of LRR in elderly patients (>75 years). The complication rate was slightly increased compared to the younger population. Incontinence and constipation improved in half of the patients irrespectively of age.[31]

Dyrberg used a laparoscopic dorsal mesh rectopexy in 81 older patients with FRP.[32] A remarkable major complication rate of 14.8% was reported. Port site hernias with consecutive ileus and postoperative hemorrhage each occurred in 5% of patients. The 13.5% of recurrences were observed at a median follow-up of 2 years.

TYPICAL COMPLICATIONS AND THEIR MANAGEMENT

A study in a tertiary referral center analyzed the typical complications after mesh rectopexy: Mesh fistulation or erosion of the rectum, vagina or the bladder, rectovaginal fistula, early symptomatic recurrence, rectal stricture and chronic pelvic pain were observed. In this study, all complications could be managed laparoscopically.[33]

The reasons for early recurrence were in all 27 cases, an inadequate technique during the prior operation (only limited or no ventral dissection, no sutures in the rectovaginal space, detachment or incorrect position of the staples, wrong placement of the mesh to the lateral instead the anterior rectal wall with development of an enterocele). These cases were treated by placement of a new mesh and fixation with staples and sutures. Rectovaginal fistulas were treated with removal of the mesh and abdominal or transvaginal fistula repair. Rectal injuries and strictures were operated by anterior resection and a placement of a bio-mesh. In all patients with rectal

strictures the mesh had been stapled to the mid-sacrum rather than to the promontory. Erosions of the vagina or the bladder were managed by mesh removal, defect repair and insertion of a bio-mesh. All women with this complication were postmenopausal and had previous hysterectomy. In patients that complained about chronic pain unresponsive to pain medication, the mesh showed an excessive inflammation. A replacement of the mesh by a teflon-coated mesh improved symptoms. After revisional surgery, quality of life and bowel function improved significantly.

Two case reports describe a mesh fistulation in the rectum.[34,35] Typical symptoms were recurrent fever, pelvic pain and rectal bleeding. Diagnosis was made by flexible sigmoidoscopy. In one case, therapy was anterior rectum resection, in the other case, the mesh was extracted laparoscopically and a loop-ileostomy was performed.

Tranchart et al[36] observed six rectal mesh migrations after 312 laparoscopic ventral mesh rectopexies (1.9%). The median time interval between surgery and onset of symptoms was 53 months (4–124 months). The treatment was transanal partial mesh resection, in one case where a recto-cutaneous fistula was present, a deviating colostomy was added. A recurrent mesh migration was again treated with partial mesh resection. After a median follow-up of 40 months all patients were free of complaints and showed no recurrent mesh, migration.

As a rare but serious complication lumbosacral discitis at the site of rectal fixation was observed after ventral rectopexy and resection rectopexy. Only four cases are reported in literature. Patients presented typically 1 to 3 months after the initial operation with severe lower back pain, fever and malaise. An magnetic resonance imaging (MRI) revealed the diagnosis. A contrast enema was helpful to rule out a rectal fistula. Broad spectrum iv-antibiotics covering colonic flora are the treatment of first choice. In some cases, antibiotic treatment was not sufficient, and removal of mesh or suture material was necessary, in one case with a deviating colostomy.[37,38] A gynecological review found 26 cases of discitis after sacrocolpopexy or rectopexy in a 50-year period.[39] Although this complication is rare it should always be considered in patients complaining of persisting back pain after any type of rectopexy.

FINANCIAL CONSIDERATIONS

An Australian study from 2004 conducted a cost-effectiveness analysis for posterior mesh rectopexy in a randomized setting. When costs for theater time, staff, laparoscopic equipment and hospital stay were included, the laparoscopic operation was less costly than the open operation. The shorter hospital stay in the laparoscopic group accounted for this saving.[40]

CONCLUSION

The evaluation of the different operation techniques is difficult, as the quality of available studies is low and outcome parameters are not defined consistently.

The laparoscopic approach for rectal prolapse is equivalent to the open approach in terms of functional and clinical outcome. The recurrences rates do not seem to differ, although single studies suggest higher recurrence rates after laparoscopic surgery. Advantages are a shorter hospital stay. It has to be remarked that the evidence is based on only two randomized and a few prospective and comparative case-controlled studies with significant heterogeneity in patient characteristics and in applied surgical procedures, making a relevant selection bias very probably.

Regarding complications and conversion rates all laparoscopic procedures provide similar good results with each having their typical complications (anastomotic leakage, mesh complications). Recurrence rates for all methods are below 10% within a follow-up of up to 5 years but studies that extended follow-up to 10 years found recurrence rates of up to 20%.

Laparoscopic resection rectopexy and LVR improve both constipation and faecal incontinence in a similar degree, but randomized studies are missing. Laparoscopic suture rectopexy (LSR) and Laparoscopic posterior rectopexy (LPR) have about the same effect on incontinence, but they tend to have a lesser effect on constipation, in some studies these operations even worsened constipation in a relevant number of patients.

As high quality evidence is missing, an individualized approach is recommend for every patient considering age, individual health status and the underlying morphological and functional disorders. Moreover, as most operations actually show acceptable results, the choice of procedure also depends on the experience and learning curve of the surgeon.

REFERENCES

1. Bordeianou L, Hicks CW, Kaiser AM, Alavi K, Sudan R, Wise PE. Rectal prolapse: an overview of clinical features, diagnosis, and patient-specific management strategies. J Gastrointest Surg 2014;18:1059-1069.
2. Goldstein SD, Maxwell PJ. Rectal prolapse. Clin Colon Rectal Surg 2011;24:39-45.
3. Shorvon PJ, McHugh S, Diamant NE, Somers S, Stevenson GW. Defecography in normal volunteers: results and implications. Gut 1989;30:1737-1749.
4. Palit S, Bhan C, Lunniss PJ, Boyle DJ, Gladman MA, Knowles CH, Scott SM. Evacuation proctography: a reappraisal of normal variability. Colorectal Dis 2014;16:538-546.
5. Madiba TE, Baig MK, Wexner SD. Surgical management of rectal prolapse. Arch Surg 2005;140:63-73.

6. Senapati A, Gray RG, Middleton LJ, Harding J, Hills RK, Armitage NC, Buckley L, Northover JM. Prosper: a randomised comparison of surgical treatments for rectal prolapse. Colorectal Dis 2013;15:858-868.
7. Berman IR. Sutureless laparoscopic rectopexy for procidentia. Technique and implications. Dis Colon Rectum 1992;35: 689-693.
8. Rondelli F, Bugiantella W, Villa F, Sanguinetti A, Boni M, Mariani E, Avenia N. Robot-assisted or conventional laparoscoic rectopexy for rectal prolapse? Systematic review and meta-analysis. Int J Surg 2014;12 Suppl 2:S153-S159.
9. Matzel KE, Heuer S, Zhang W. Rectal prolapse. Abdominal or local approach. Chirurg 2008;79:444-451.
10. Smart NJ, Pathak S, Boorman P, Daniels IR. Synthetic or biological mesh use in laparoscopic ventral mesh rectopexy: a systematic review. Colorectal Dis 2013;15:650-654.
11. Kusminsky RE, Tiley EH, Boland JP. Laparoscopic ripstein procedure. Surg Laparosc Endosc 1992;2:346-347.
12. Loygue J, Huguier M, Malafosse M, Biotois H. Complete prolapse of the rectum. A report on 140 cases treated by rectopexy. Br J Surg 1971;58:847-848.
13. Van Geluwe B, Wolthuis A, D'Hoore A. Laparoscopy for pelvic floor disorders. Best Pract Res Clin Gastroenterol 2014;28:69-80.
14. Frykman HM, Goldberg SM. The surgical treatment of rectal procidentia. Surg Gynecol Obstet 1969;129:1225-1230.
15. Formijne Jonkers HA, Draaisma WA, Wexner SD, Broeders IA, Bemelman WA, Lindsey I, Consten EC. Evaluation and surgical treatment of rectal prolapse: an international survey. Colorectal Dis 2013;15:115-119.
16. Mercer-Jones MA, D'Hoore A, Dixon AR, Lehur P, Lindsey I, Mellgren A, Stevenson AR. Consensus on ventral rectopexy: report of a panel of experts. Colorectal Dis 2014;16:82-88.
17. Miskovic D, Ni M, Wyles SM, Tekkis P, Hanna GB. Learning curve and case selection in laparoscopic colorectal surgery: systematic review and international multicenter analysis of 4852 cases. Dis Colon Rectum 2012;55:1300-1310.
18. Kayano H, Okuda J, Tanaka K, Kondo K, Tanigawa N. Evaluation of the learning curve in laparoscopic low anterior resection for rectal cancer. Surg Endosc 2011;25:2972-2979.
19. Boccasanta P, Venturi M, Reitano MC, Salamina G, Rosati R, Montorsi M, Fichera G, Strinna M, Peracchia A. Laparotomic vs. laparoscopic rectopexy in complete rectal prolapse. Dig Surg 1999;16:415-419.
20. Solomon MJ, Young CJ, Eyers AA, Roberts RA. Randomized clinical trial of laparoscopic versus open abdominal rectopexy for rectal prolapse. Br J Surg 2002;89:35-39.
21. Tou S, Brown SR, Malik AI, Nelson RL. Surgery for complete rectal prolapse in adults. Cochrane Database Syst Rev 2008;4:CD001758.
22. Kairaluoma MV, Viljakka MT, Kellokumpu IH. Open vs laparoscopic surgery for rectal prolapse: a case-controlled study assessing short-term outcome. Dis Colon Rectum 2003;46: 353-360
23. Kariv Y, Delaney CP, Casillas S, Hammel J, Nocero J, Bast J, Brady K, Fazio VW, Senagore AJ. Long-term outcome after laparoscopic and open surgery for rectal prolapse: a case-control study. Surg Endosc 2006;20:35-42.
24. Schultz I, Mellgren A, Dolk A, Johansson C, Holmström B. Long-term results and functional outcome after ripstein rectopexy. Dis Colon Rectum 2000;43:35-43.
25. de Hoog DE, Heemskerk J, Nieman FH, van Gemert WG, Baeten CG, Bouvy ND. Recurrence and functional results after open versus conventional laparoscopic versus robot-assisted laparoscopic rectopexy for rectal prolapse: a case-control study. Int J Colorectal Dis 2009;24:1201-1206.
26. Sajid MS, Siddiqui MR, Baig MK. Open vs laparoscopic repair of full-thickness rectal prolapse: a re-meta-analysis. Colorectal Dis 2010;12:515-525.
27. Cadeddu F, Sileri P, Grande M, De Luca E, Franceschilli L, Milito G. Focus on abdominal rectopexy for full-thickness rectal prolapse: meta-analysis of literature. Tech Coloproctol 2012;16:37-53.
28. Seishima R, Okabayashi K, Hasegawa H, Tsuruta M, Shigeta K, Matsui S, Yamada T, Kitagawa Y. Is laparoscopic colorectal surgery beneficial for elderly patients? A systematic review and meta-analysis. J Gastrointest Surg 2015;19:756-765.
29. Gultekin FA, Wong MT, Podevin J, Barussaud ML, Boutami M, Lehur PA, Meurette G. Safety of laparoscopic ventral rectopexy in the elderly: results from a nationwide database. Dis Colon Rectum 2015;58:339-343.
30. Bjerke T, Mynster T. Laparoscopic ventral rectopexy in an elderly population with external rectal prolapse: clinical and anal manometric results. Int J Colorectal Dis 2014;29: 1257-1262.
31. Laubert T, Bader FG, Kleemann M, Esnaashari H, Bouchard R, Hildebrand P, Schlöricke E, Bruch HP, Roblick UJ. Outcome analysis of elderly patients undergoing laparoscopic resection rectopexy for rectal prolapse. Int J Colorectal Dis 2012;27: 789-795.
32. Dyrberg DL, Nordentoft T, Rosenstock S. Laparoscopic posterior mesh rectopexy for rectal prolapse is a safe procedure in older patients: a prospective follow-up study. Scand J Surg 2015.
33. Badrek-Al Amoudi AH, Greenslade GL, Dixon AR. How to deal with complications after laparoscopic ventral mesh rectopexy: lessons learnt from a tertiary referral centre. Colorectal Dis 2013;15:707-712.
34. Mathew MJ, Parmar AK, Reddy PK. Mesh erosion after laparoscopic posterior rectopexy: a rare complication. J Minim Access Surg 2014;10:40-41.
35. Adeyemo D. Mesh fistulation into the rectum after laparoscopic ventral mesh rectopexy. Int J Surg Case Rep 2014;5: 152-154.
36. Tranchart H, Valverde A, Goasguen N, Gravié JF, Mosnier H. Conservative treatment of intrarectal mesh migration after ventral laparoscopic rectopexy for rectal prolapse. Int J Colorectal Dis 2013;28:1563-1566.
37. Propst K, Tunitsky-Bitton E, Schimpf MO, Ridgeway B. Pyogenic spondylodiscitis associated with sacral colpopexy and rectopexy: report of two cases and evaluation of the literature. Int Urogynecol J 2014;25:21-31.
38. Vujovic Z, Cuarana E, Campbell KL, Valentine N, Koch S, Ziyaie D. Lumbosacral discitis following laparoscopic ventral mesh rectopexy: a rare but potentially serious complication. Tech Coloproctol. 2015;19:263-265.
39. Probst P, Knoll SN, Breitenstein S, Karrer U. Vertebral discitis after laparoscopic resection rectopexy: a rare differential diagnosis. J Surg Case Rep 2014;2014:pii:rju075.
40. Salkeld G, Bagia M, Solomon M. Economic impact of laparoscopic versus open abdominal rectopexy. Br J Surg 2004;91: 1188-1191.

10.5005/jp-journals-10033-1256

REVIEW ARTICLE

Role of Minimally Invasive Surgery in Gynecological Cancers

Rajendra Shitole

ABSTRACT

Background: Presently due to technological advances, operative laparoscopy now plays a crucial role in the management of pelvic malignancies. With newly developed techniques to complete both pelvic and para-aortic lymph node dissection, the use of the laparoscope has increased in patients with pelvic malignancies. Gynecological oncologists are currently incorporating the techniques of operative laparoscopy in the management of patients with cervical, endometrial, and ovarian cancer.

Aim: To review literature on the role of minimal invasive surgery in various gynecological cancers.

Materials and methods: These were drawn from previous research materials online in PubMed, Cochrane library, Wikipedia.

Conclusion: Minimal invasive surgical approaches to the management of gynecologic malignancies are feasible and provide exciting alternatives. However, the safety and efficacy of these techniques compared to laparotomy in this setting has not been carefully studied. Potential advantages include shorter operative time for some procedures, shorter recovery times, and less adhesion formation. These new surgical techniques need to be evaluated critically and compared to more traditional approaches.

Keywords: Gynecological cancers, Laparoscopy, Lymphadenectomy, Minimally invasive surgery.

How to cite this article: Shitole R. Role of Minimally Invasive Surgery in Gynecological Cancers. World J Lap Surg 2015;8(3): 96-100.

Source of support: Nil

Conflict of interest: None

INTRODUCTION

In the past, the laparoscope has been used for few procedures like diagnostic and sterilization procedures. Due to technologic advances, operative laparoscopy and other minimal invasive surgical techniques now play a important role in the management of a wide variety of benign gynecological conditions including ectopic pregnancy, endometriosis, pelvic pain, leiomyomata and adnexal masses. Similarly, the role of minimal invasive surgery in the management of malignant disease has expanded. With newly developed techniques to complete both pelvic and para-aortic lymph node dissection, the use of minimal invasive surgical techniques has increased in patients with pelvic malignancies. Gynecologic oncologists are currently incorporating the techniques of minimal invasive surgery in the management of patients with cervical, endometrial and ovarian cancer.

Radical vaginal trachelectomy with laparoscopic pelvic lymphadenectomy has emerged as a safe, reasonable option for women with early-stage cervical cancer desiring fertility preservation. Similarly, laparoscopic radical hysterectomy with pelvic lymphadenectomy has been systematically described, is feasible, and can be offered to women with early-stage cervical cancer who do not desire future childbearing. In the treatment of early stage endometrial cancer, the surgical approach of laparoscopic hysterectomy, peritoneal washings, and pelvic and para-aortic lymph node dissection, with or without an omentectomy, is being compared with the same surgery performed via laparotomy in the cooperative gynecologic oncology group (GOG) LAP 2 study, which has completed accrual, and appears to be a reasonable surgical option. In ovarian cancer, minimally invasive surgery has been incorporated to manage early-stage, advanced-stage, and recurrent disease, as well as second-look procedures. Hand-assisted laparoscopy has also recently been described in managing larger volume primary and recurrent gynecologic cancers.

AIMS AND OBJECTIVES

To review literature on the role of minimal invasive surgery in various gynecological cancers.

MATERIALS AND METHODS

An extensive literature search online was done through PubMed, Wikipedia, Cochrane and videos via YouTube.

REVIEW OF ART ICLES

Cervical Cancer

The issue of laparoscopy in the management of locally advanced cervical cancer has been addressed by several authors. In particular, researchers from Korea, Chung et al,[1]

Senior Resident

Department of Obstetrics and Gynecology, Dr DY Patil Medical College, Hospital and Research Centre, Pune, Maharashtra India

Corresponding Author: Rajendra Shitole, Senior Resident Department of Obstetrics and Gynecology, Dr DY Patil Medical College, Hospital and Research Centre, Pimpri, Pune-411018 Maharashtra, India, e-mail: raj110785@gmail.com

evaluated the feasibility and safety of pretreatment laparoscopic surgical staging in the treatment of locally advanced cervical cancer. The authors contended that pretreatment laparoscopy is the best guideline for individualized concurrent chemoradiation. When compared with magnetic resonance imaging, laparoscopic surgical staging was superior in detecting microscopic lymph node metastases.

Various studies summarized in Tables 1 to 3 respectively at various places.

Thus, while abdominal radical hysterectomy remains the standard of care for early-stage cervical cancer, laparoscopic radical hysterectomy appears to be a safe, reasonable alternative. Operative laparoscopy has also been used as a means of determining a patient's eligibility for pelvic exenteration for recurrent cervical cancer, removal of diseased adnexae, and ovarian transposition. It has been proven to be a valuable step in the workup and management of patients with locally recurrent cervical cancer.

Endometrial Cancer

Operative laparoscopy is also useful in the management of patients with malignancies of the uterine corpus. In 1988, endometrial cancer became a surgically staged malignancy according to FIGO. The importance of pelvic and para-aortic lymph node status documented by a large GOG study was instrumental in motivating the change to surgical staging.

Various studies are summarized in Table 2:

Patients managed with a laparoscopic approach had the same number of lymph nodes removed, but had less complications, a shorter hospital stay and quicker recovery than the laparotomy group. In addition to surgical staging in the primary management of endometrial carcinoma patients, the technique can be utilized in patients with incomplete staging of disease at their primary surgery.

Ovarian Cancers

Epithelial ovarian cancer is one of the leading causes of death in gynecological malignancies and the seventh most common cancer in the world among women. Minimally invasive surgery for patients with ovarian cancer can be incorporated in different ways depending on the stage of disease and surgical goals of the procedure. In advanced stage disease, laparoscopy in general can be used to confirm diagnosis and determine resectability. In early-stage disease, patients can be comprehensively staged via the laparoscopic approach. The laparoscopic

Table 1: Various studies comparing laparoscopic approach *vs* conventional approach for management of cervical cancer

Sl. no.	*Name*	*Type of study*	*Intervention*	*Participants*	*Result*
1	Roy et al[2]	Retrospective	Laparoscopic pelvic lymphadenectomy and radical vaginal hysterectomy with abdominal radical hysterectomy	52	Both procedures were equally safe and efficacious
2	Spirtos et al[3]	Prospective	Laparoscopic radical hysterectomy	78	94% of the procedures were com-pleted laparoscopically. The average operative time was 205 minutes. The average EBL was 225 ml, with only one patient requiring a blood transfusion. There were three cystotomies and one ureterovaginal fistula noted. The average lymph node count was 34, with 11.5% of patients having positive nodes. Three patients had close or positive surgical margins, and 5.1% of patients recurred with at least a 3-year follow-up[3]
3	Abu-Rustum et al[4]	Prospective	Compared patients undergoing laparoscopic radical hysterectomy with pelvic lymphadenectomy with patients with abdominal radical hysterectomy with pelvic lymph node dissection	Not available	The laparoscopic approach for radical hysterectomy was safe, feasible, and associated with low morbidity. The median operative time was longer for the laparoscopic approach, while the hospital stay and EBL were significantly less in the laparoscopic group.
4	Marnitz et al[5]	Prospective	Patients with locally advanced cervical cancer who were selected for laparoscopic staging for primary chemoradiation.	84	They found that removal of more than five pelvic and/or more than five para-aortic lymph nodes was associated with significantly longer overall survival. The authors concluded that debulking of tumor-involved lymph nodes should be performed prior to primary chemoradiation in patients with locally advanced cervical cancer.
5	Kohler et al[6]	Prospective	Patients undergoing explorative laparoscopy to determine eligibility for exenteration	41	Almost half (48.7%) of the patients avoided unnecessary exenteration for unresectable disease or intra-abdominal spread of disease.

Table 2: Various studies comparing laparoscopic approach *vs* conventional approach for management of endometrial cancer

Sl. no.	*Name*	*Type of study*	*Intervention*	*Participants*	*Results*
1	Gemignani et al[7]	Prospective	Laparoscopically assisted vaginal hysterectomy with pelvic and para-aortic lymph node dissection, peritoneal washings, and an omentectomy in patients with serious malignancies of the endometrium with total abdominal hysterectomy (TAH)/ BSO with surgical staging	Not available	LAVH was associated with a shorter hospital stay, fewer complications, and lower overall hospital charges
2	Tozzi et al[8]	Randomized controlled trial	Laparoscopy *vs* laparotomy in endometrial cancer	122	The overall survival rate was 86.3 *vs* 89.7%, respectively. The authors recommend that laparoscopic procedures be included in the routine treatment options for patients with endometrial cancer
3	Janda 2010[9]	Multicenter randomized controlled trials	Total laparoscopic hysterectomy, bilateral salpingo-oophorectomy, peritoneal washings, +/- pelvic lymph node dissection +/-para-aortic lymph node dissection *vs* conventional laparotomy approach	332	Laparoscopic approach is associated with equivalent disease free survival rate when compared with the standard laparotomy approach for women with Stage I endometrial cancer
4	Mourits 2010[10]	Multicenter randomized controlled trial conventional laparotomy approach	Total laparoscopic hysterectomy, bilateral salpingo-oophorectomy, peritoneal washings, +/- pelvic lymph node dissection +/-para-aortic lymph node dissection *vs* laparotomy approach	283	TLH was associated with significantly less blood loss ($p < 0{\cdot}0001$), less use of pain medication ($p < 0{\cdot}0001$), a shorter hospital stay ($p < 0{\cdot}0001$), and a faster recovery ($p = 0{\cdot}002$), but the procedure took longer than TAH ($p < 0{\cdot}0001$).
5	Walker 2012[11]	Multicenter randomized controlled trial	Laparoscopic hysterectomy included laparoscopic assisted techniques, total laparoscopic approaches, and rarely robotics." Washings, extrafascial hysterectomy and bilateral salpingo-oophorectomy, + pelvic lymph node sampling + para-aortic lymph node sampling *vs* Laparotomy, washings, extrafascial hysterectomy and bilateral salpingo-oophorectomy, + pelvic lymph node sampling + para-aortic lymph node sampling	2616	Laparoscopy had fewer moderate to severe postoperative adverse events than laparotomy (14 *vs* 21%, respectively; $p < 0.0001$) but similar rates of intraoperative complications, despite having a significantly longer operative time (median, 204 *vs* 130 minutes, respectively; $p < 0.001$).

second-look procedure is a reasonable approach to assessing disease status at completion of adjuvant chemotherapy in selected patients.

Various studies are summarized in Table 3.

The rates of negative evaluations and recurrence rates were comparable between patients undergoing laparoscopy and those undergoing laparotomy for ovarian cancers.

DISCUSSION

It is clear that minimally invasive surgery approaches to the management of gynecologic malignancies are feasible and provide exciting alternatives. Operating times intuitively have improved with greater surgical experience. In addition, adequacy of the procedure being performed needs to be assured. Comparison of recurrence rates and survival provide some insight. Schlaerth et al[16] evaluated women with cervical cancer undergoing laparoscopic retroperitoneal lymphadenectomy followed-by imme-diate laparotomy to assess the adequacy of lymph node removal. In that study, the investigators reported that laparoscopic aortic lymph node sampling could be performed safely and adequately. Laparoscopic pelvic lymphadenectomy was noted at the time of laparotomy to have residual tissue lateral to the common iliac vessel and distal external iliac vessels in 15% of patients. Because none of the laparoscopic surgeons were aware of the pre-

Table 3: Various studies comparing laparoscopic approach *vs* conventional approach for management of ovarian cancer

Sl. no.	*Name*	*Type of study*	*Intervention*	*Participants*	*Results*
1	Chi et al[12]	Prospective	Laparoscopic staging *vs* staging via laparotomy for apparent stage I ovarian or fallopian tube cancers	50	The authors concluded that patients with apparent stage I ovarian and fallopian tube cancers can safely and adequately undergolaparoscopic surgical staging
2	Leblanc et al[13]	Prospective	Laparoscopic staging of incompletely staged invasive adnexal tumors	42	They found it to be safe, accurate, and with a low incidence of complications, particularly in the group of patients who had already undergone prior abdominal surgery. They found that the rates of negative evaluations and recurrence rates were comparable between patients undergoing laparoscopy and those undergoing laparotomy.
3	Hua 2005[14]	Prospective case-control	Laparoscopic surgical staging *vs* open surgical staging of early ovarian cancer	21	Significantly fewer postoperative complications with laparoscopy compared with laparotomy
4	Angioli 2005[15]	Retro- or prospective enrolment not known	Open diagnostic laparoscopy; examination of the whole abdominal cavity, biopsies for frozen section, performed by gynecological oncologist. If judged resectable direct cytoreduction was done	87	53 where indicated to be operable. Of these 51 had operable disease at laparotomy and 2 not. The other 34 patients were treated with NACT and 25 received an interval debulking surgery after 3 courses of chemotherapy

sence of this residual tissue, awareness should allow for correction of this potential surgical shortcoming. Also, there was concern that tumor implantation might be more commonly associated with laparoscopy. Abu-Rustum et al[17] noted that subcutaneous tumor implantation is not limited to laparoscopy. In a 12-year period, 1,288 patients had 1,335 transperitoneal laparoscopies. Laparoscopy-related subcutaneous tumor implantation was noted to be rare (0.97%) in women undergoing transperitoneal laparoscopy with malignant disease. Patients with advanced intra-abdominal or pelvic metastatic disease and progressive carcinomatosis appeared at greatest risk. Abu-Rustum et al[17] concluded that the risk for subcutaneous tumor implantation should not preclude laparoscopy in women with gynecologic malignancies managed by gynecologic oncologists. Frequently, obesity can present a challenge in managing early endometrial cancer via a minimally invasive approach. Eltabbakh et al[18] prospectively studied 42 obese women with clinical stage I endometrial cancer over a 2-year period. Forty patients were offered laparoscopic surgery. The procedure was converted to open laparotomy in three (7.5%) of the patients. Holub et al also reported on peri- and postoperative outcomes in obese *vs* nonobese patients using a minimally invasive surgical approach. They reported no statistical difference in operating time, lymph node counts, blood loss, or hospital stay. However, in a group of 33 obese and 32 nonobese patients, there was a higher number of major complications in obese patients than in nonobese patients (eight *vs* five). In the obese subgroup, complications included pulmonary microembolism, injury to the epigastric artery, injury to the bladder, uncontrolled bleeding, and conversion to laparotomy. Holub et al[19] concluded that the expected outcome should be balanced with risks, but emphasized that laparoscopic surgery in obese women, much like in nonobese women, is safe, feasible, and should be considered in patients with endometrial cancer. Injuries to the bladder and epigastric artery, as reported by Holub et al,[19] highlight the difficulties of trocar placement in patients who are morbidly obese. Childers et al[20] also found that, in patients with endometrial cancer, obesity was the limiting factor in performing lymphadenectomies. Eltabbakh et al were unable to perform para-aortic lymph node samplings in two patients because of poor visualization secondary to obesity. However, they did report higher pelvic lymph node yields laparoscopically when compared with laparotomy. Finally, assessment of complications and conversion rate need to be addressed as the role of minimally invasive surgery increases in the management of gynecologic cancers. In evaluating their initial 10-year experience with laparoscopy, Chi et al[21] noted a low complication rate (2.5% grade 3–5) and a low conversion rate of 7%. They identified older age, malignancy, previous radiation, and previous abdominal surgery as significant risk factors for complications or conversion to laparotomy, which should help guide patient selection and surgical planning.

CONCLUSION

After a literature search, it seems that minimal invasive surgical staging operation is a safe and effective therapeutic procedure for management of gynecological cancers, with an acceptable morbidity compared to the

laparotomic approach, and is characterized by far less blood loss and shorter postoperative hospitalization time. Recently, some reports demonstrated that robotic surgery is superior to laparoscopy in surgical staging of endometrial cancer.[22,23] However, the high cost limits universal use. Further multicenter randomized trials with longer follow-up should be necessary to evaluate the overall oncologic outcomes of this procedure.

REFERENCES

1. Chung HH, Lee S, Sim JS, et al. Pretreatment laparoscopic surgical staging in locally advanced cervical cancer: preliminary results in Korea. Gynecol Oncol 2005;97(2):468-475.
2. Roy M, Plante M, Renaud MC, et al. Vaginal radical hysterectomy vs abdominal radical hysterectomy in the treatment of early-stage cervical cancer. Gynecol Oncol 1996;62(3): 336-339.
3. Spirtos NM, Eisenkop SM, Schlaerth JB, et al. Laparoscopic radical hysterectomy (type III) with aortic and pelvic lymphadenectomy in patients with stage I cervical cancer: surgical morbidity and intermediate follow-up. Am J Obstet Gynecol 2002;187(2):340-348.
4. Abu-Rustum NR, Gemignani ML, Moore K, et al. Total laparoscopic radical hysterectomy with pelvic lymphadenectomy using the argon-beam coagulator: pilot data and comparison to laparotomy. Gynecol Oncol 2003;91(2):402-409.
5. Marnitz S, Kohler C, Roth C, et al. Is there a benefit of pretreatment laparoscopic transperitoneal surgical staging in patients with advanced cervical cancer? Gynecol Oncol 2005;99(3):536-544.
6. Kohler C, Tozzi R, Possover M, et al. Explorative laparoscopy prior to exenterative surgery. Gynecol Oncol 2002;86(3): 311-315.
7. Gemignani ML, Curtin JP, Zelmanovich J, et al. Laparoscopic-assisted vaginal hysterectomy for endometrial cancer: clinical outcomes and hospital charges. Gynecol Oncol 1999;73(1): 5-11.
8. Tozzi R, Malur S, Koehler C, et al. Laparoscopy vs laparotomy in endometrial cancer: first analysis of survival of a randomized prospective study. J Minim Invasive Gynecol 2005;12(2):130-136.
9. Janda M, Gebski V, Brand A, Hogg R, Jobling TW, Land R, et al. Quality of life after total laparoscopic hysterectomy vs total abdominal hysterectomy for stage I endometrial cancer (LACE): a randomised trial. Lancet Oncol 2010;11(8): 772-780.
10. Bijen CB, Briët JM, de Bock GH, Arts HJ, Bergsma-Kadijk JA, Mourits MJ. Total laparoscopic hysterectomy vs abdominal hysterectomy in the treatment of patients with early stage endometrial cancer: a randomized multi center study. BMC Cancer 2009;9(1):23.
11. Walker JL, Piedmonte M, Spirtos N, Eisenkop S, Schlaerth J, Mannel RS, et al. Surgical staging of uterine cancer. Randomized phase III trial of laparoscopy vs laparotomy: a gyneclogic oncology group study (GOG): preliminary results. J Clin Oncol: ASCO annual proceedings part 1 2006;24(18S):5010
12. Chi DS, Abu-Rustum NR, Sonoda Y, et al. The safety and efficacy of laparoscopic surgical staging of apparent stage I ovarian and fallopian tube cancers. Am J Obstet Gynecol 2005;192(5):1614-1619.
13. Leblanc E, Querleu D, Narducci F, et al. Laparoscopic restaging of early stage invasive adnexal tumors: a 10-year experience. Gynecol Oncol 2004;94(3):624-629.
14. Hua KQ, Jin FM, Xu F, Zhu ZL, Lin JF, Feng YJ. Evaluations of laparoscopic surgery in the early stage malignant tumor of ovary with lower risk. Zhonghua Yi Xue Za Zhi 2005; 85(3):169-172.
15. Angioli R, Palaia I, Zullo MA, Muzii L, Manci N, Calcagno M, et al. Diagnostic open laparoscopy in the management of advanced ovarian cancer. Gynecol Oncol 2006;100(3):455-461.
16. Schlaerth JB, Spirtos NM, Carlson LF, et al. Laparoscopic retroperitoneal lymphadenectomy followed by immediate laparotomy in women with cervical cancer: a gynecologic oncology group study. Gynecol Oncol 2002;85(1):81-88.
17. Abu-Rustum NR, Rhee EH, Chi DS, et al. Subcutaneous tumor implantation after laparoscopic procedures in women with malignant disease. Obstet Gynecol 2004;103(3):480-487.
18. Eltabbakh GH, Shamonki MI, Moody JM, et al. Hysterectomy for obese women with endometrial cancer: laparoscopy or laparotomy? Gynecol Oncol 2000;78(3):329-335.
19. Holub Z, Bartos P, Jabor A, et al. Laparoscopic surgery in obese women with endometrial cancer. J Am Assoc Gynecol Laparosc 2000;7(2):83-88.
20. Childers JM, Spirtos NM, Brainard P, et al. Laparoscopic staging of the patient with incompletely staged early adenocarcinoma of the endometrium. Obstet Gynecol 1994;83(4): 597-600.
21. Chi DS, Abu-Rustum NR, Sonoda Y, et al. Ten-year experience with laparoscopy on a gynecologic oncology service: analysis of risk factors for complications and conversion to laparotomy. Am J Obstet Gynecol 2004;191(4):1138-1145.
22. Lowe MP, Johnson PR, Kamelle SA, Kumar S, Chamberlain DH, Tillmanns TD. A multiinstitutional experience with robotic-assisted hysterectomy with staging for endometrial cancer. Obstet Gynecol 2009;114(2):236-243.
23. Cardenas-Goicoechea J, Adams S, Bhat SB, Randall TC. Surgical outcomes of robotic-assisted surgical staging for endometrial cancer are equivalent to traditional laparoscopic staging at a minimally invasive surgical center. Gynecol Oncol 2010;117(2):224-228.

10.5005/jp-journals-10033-1257

REVIEW ARTICLE

Comparison between Different Entry Techniques in Performing Pneumoperitoneum in Laparoscopic Gynecological Surgery

Mandavi Rai

ABSTRACT

Background: The main challenge facing the laparoscopic surgery is the primary abdominal access, as it is usually a blind procedure associated with vascular and visceral injuries. Laparoscopy is a very common procedure in gynecology. Complications associated with laparoscopy are often related to entry. The life-threatening complications include injury to the bowel, bladder, major abdominal vessels, and anterior abdominal-wall vessel. Other less serious complications can also occur, such as postoperative infection, subcutaneous emphysema and extraperitoneal insufflation. There is no clear consensus as to the optimal method of entry into the peritoneal cavity. It has been proved from studies that 50% of laparoscopic major complications occur prior to the commencement of the surgery. The surgeon must have adequate training and experience in laparoscopic surgery before intending to perform any procedure independently. He should be familiar with the equipment, instrument and energy source he intends to use.

Materials and methods: A Literature review was performed using PubMed, MedSpace, Springer Link and search engines like Google and Yahoo. Following search terms were used: trocar, laparoscopy, complications and pneumoperitoneum, entery technique. A total of 10,000 citations were found. Selected papers were screened for further references. Publications that featured illustrations and statistical methods of analysis are selected.

Results: Fifty-one articles were reviewed and the the operations included in our study were diagnostic laparoscopy for infertility and abdominal pathology, ovarian cyst, total laparoscopic hysterectomy, burch operation, myomectomy. The early complications recorded in our study are abdominal wall vascular injuries, visceral injuries, bradycardia, preperitoneal insufflations. The incidence of laparoscopic entry-related injuries in gynecological operations was 6.9%. Overall, there was no evidence of advantage using any single technique in terms of preventing major complications. However, there were two advantages with direct trocar entry when compared with Veress-needle entry, in terms of avoiding extraperitoneal insufflation and failed entry.

Conclusion: On the basis of evidence investigated in this review, there appears to be no evidence of benefit in terms of safety of one technique over another. However, the included studies are small and cannot be used to confirm safety of any particular technique. No single technique or instrument has been proved to eliminate laparoscopic entry-associated injury. Proper evaluation of the patient, supported by good surgical skills and reasonably good knowledge of the technology of the instruments remain to be the cornerstone for safe access and success in minimal access surgery.

Keywords: Complications, Laparoscopy, Pnumoperitoneum, Trocar.

How to cite this article: Rai M. Comparison between Different Entry Techniques in Performing Pneumoperitoneum in Laparoscopic Gynecological Surgery. World J Lap Surg 2015;8(3):101-106.

Source of support: Nil

Conflict of interest: None

Senior Resident

Department of Obstetric and Gynecology, Max Super Speciality Hospital, Saket, New Delhi, India

Corresponding Author: Mandavi Rai, Senior Resident Department of Obstetric and Gynecology, Max Super Speciality Hospital, Saket, New Delhi, India, Phone: 9910873175, e-mail: mandavirai@ymail.com

INTRODUCTION

The word laparoscopy originated from the Greek word (Lapro—abdomen, scopion—to examine). Laparoscopy is the art of examining the abdominal cavity and its contents. This is achieved by sufficiently distending the abdominal cavity (pneumoperitoneum) and visualizing the abdominal contents using illuminated telescope. Over the past 50 years, rapid advancement in technology in terms of electronics, optical equipments and other ancillary instruments, combined with improved surgical proficiency and expertize, laparoscopic surgery rapidly advanced from a gynecological procedure for tubal sterilization to one used in performing most of the surgical procedures in all surgical and gynecological discipline for a variety of indications.

The main challenge facing the laparoscopic surgery is the primary abdominal access, as it is usually a blind procedure associated with vascular and visceral injuries. It has been proved from studies that 50% of laparoscopic major complications occur prior to the commencement of the surgery.[1,2] If there is delay in diagnosis of visceral injuries or delay in reporting, the morbidity will increase and may lead to mortality.[3]

The surgeon must have adequate training and experience in laparoscopic surgery before intending to perform any procedure independently. He should be familiar with the equipment, instrument and energy source

he intends to use. This indicates that in spite of the improvement in the technology and experience, primary access complications were decreased but not completely eliminated.

The included techniques (Veress needle pneumopertonium, trocar/cannula system). Open (Hasson) technique. Direct trocar insertion without prior pneumoperitoneum. The use of shielded disposable trocars. Optical Veress needle and optical trocar. Radically expanding trocar and the trocarless, reusable visual access cannula.[4]

MATERIALS AND METHODS

A Literature review was performed using PubMed, Med Space, Springer Link and search engines like Google and Yahoo. Following search terms were used: trocar, laproscopy, complications and pneumoperitoneum, entry technique. Total of 10,000 citations were found. Selected papers were screened for further references. Publications that featured illustrations and statistical methods of analysis are selected.

Different Laparoscopic Entry or Access Techniques

Veress Needle and Pnemoperitoneum

Veress needle was first popularized by Roal Palmer of France 1947. The creation of pneumoperitoneum remains an essential step of successful laparoscopic surgery. Being a blind procedure, it is associated with injury to the vascular and visceral contents of the peritoneal cavity. It is the most popular technique used by most of the laparoscopic surgeons worldwide to achieve pneumoperitoneum. There are many sites for insertion for Veress needle to achieve pneumoperitoneum. In the usual circumstances in a patient with an average body mass index (BMI) and no history of previous or suspected intraperitoneal adhesions, the Veress needle is inserted through an incision at the base of the umbilicus. In obese patient with BMI > 30 or patient with history of previous midline incision, or failed pneumopertonium after three attempts alternative site for Veress needle insertion may be thought. The second common site for insertion of Veress needle is the Palmer's point which lies 3 cm below the left costal border in the midclavicular line.[5] This technique is recommended for obese or very thin patient, patient with history of previous midline surgery or suspected intraperitoneal adhesions, or failure to achieve pneumoperitoneum after three attempts. It is essential to decompress the stomach using nasogastric tube suction. This technique should be avoided in patient known to have hepatosplenomegally, history of previous gastric or splenic surgery or palpable gastropancreatic mass.[6] A 5 mm telescope can be introduced at the same site of Veress needle visualize the periumblical adhesions, then a 10 mm trocar can be introduced under direct vision, followed by additional trocar/cannula system inserted under direct vision as required. Therefore, the angle of Veress needle insertion should vary accordingly from 45° in nonobese women to 90° in very obese women.[7] Several tests have been recommended to ascertain correct placement of Veress needle in the peritoneal cavity.

These include:

- Double click sound of the Veress needle test
- Aspiration test
- Hanging drop of saline test
- Syringe test.[8]

A recent retrospective study evaluating these four tests reported that non of four tests proved confirmatory for the intraperitoneal placement of the Veress needle and concluded that the most valuable test is to observe actual insufflation pressure (intraperitoneal) to be 8 mm Hg or less, and the gas is flowing freely.[9] It has been shown that achieving high intraperitoneal pressure (HIP) entry ranging from 20 to 25 mm Hg will increase the gas bubble and produce greater splinting of the anterior abdominal wall and increase the distance between the umbilicus and bifurcation of the aorta from 0.6 cm (at pressure of 12 mm Hg) to 5.9 cm. This will allow easy entry of the primary trocar and minimize the risk of vascular injury.[10] The high pressure entry technique is recommended by the Royal College of Obstetricians and Gynaecologists (RCOG), London and The Society of Obstetricians and Gynaecologists of Canada (SOGC).[11,12] New modifications to the Veress needle have been introduced to minimize Veress needle associated injury. These include pressure sensor equipped Veress needle, optical Veress needle. However, none of these new modifications has been proved to be superior to the classic Veress needle and eliminated Veress needle-related injury. Controlled randomized trials are recommended to ascertain their safety and justify their extra cost (Fig. 1).[13]

Hassons Method

Hasson (open) entry technique was first described by Harrith Hasson in 1971. When first reported his technique Hasson claimed that his technique avoids Veress needle pneumoperitoneum and its associated complications (gas embolism and vascular injury). This technique involves incising the fascial layer and holding its edges by two lateral stay sutures, these will be used to stabilize the cannula. This will seal the abdominal wall incision to the coned-shape sleeve. The telescope is introduced and

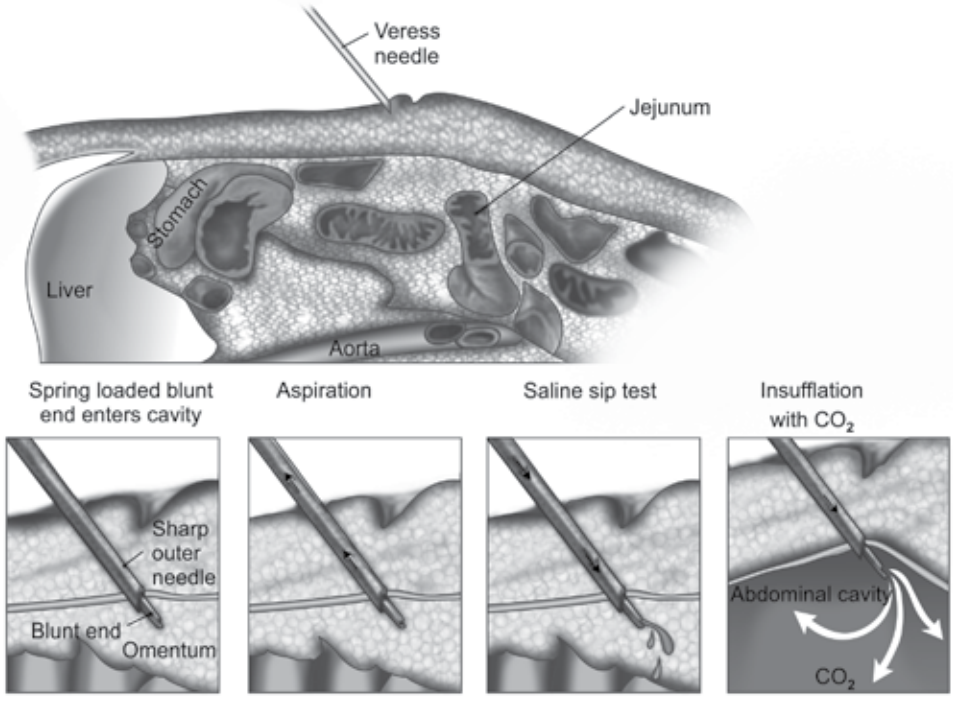

Fig. 1: Different access technique

insufflations commenced after visualizing omentum and bowel. Long standing controversy remains about the optimal primary access technique. Some authorities believe that Hasson open technique is superior to the classic closed entry technique defending their views in that it is faster, eliminate the risk of gas embolism, and significantly reduces the vascular and bowel injuries related to primary access. However, there is conflicting evidence between different studies and there is no unified opinion regarding this issue (Fig. 2).[14]

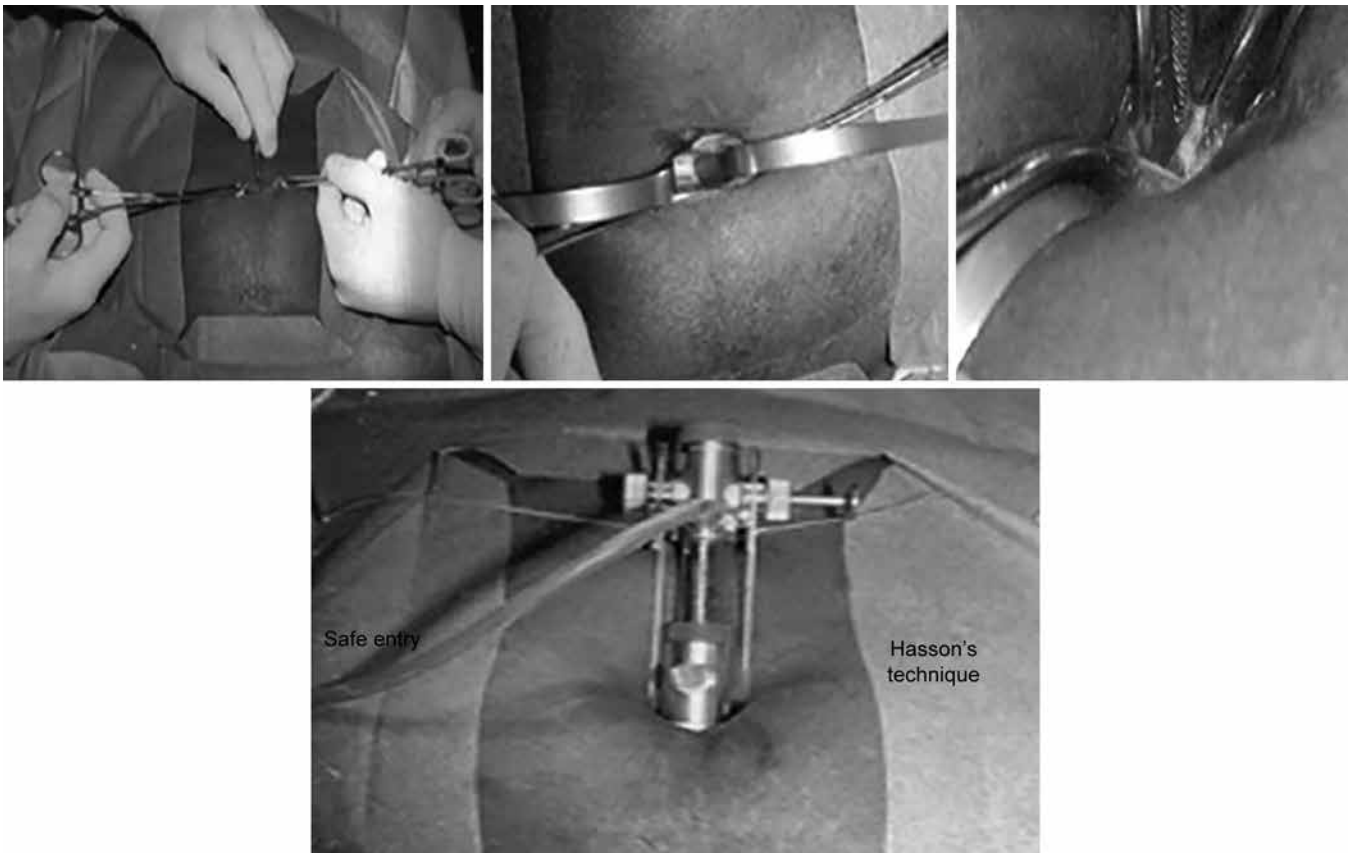

Fig. 2: Hasson's technique

Direct Trocar Entry Technique

This technique was introduced by Dingerfield in 1978. In his first publication, he suggested the advantages of his technique which eliminates Veress needle complications, these include failed pneumoperitoneum, preperitoneal insufflation and gas embolism. It is fast as it is a one-step pneumoperitoneum. However, being a blind procedure it does not eliminate the risk of bowel and vascular injuries.[15,16] Several studies were published stressing on safety of this method and recommending its use for primary access. Most of these studies were retrospective, only few studies were prospective. A retrospective review of 51 publications comparing the entry-related complications with the closed (Veress/trocar technique, open and direct trocar technique). Entry-related bowel injury rate were 0.04% (Veress/trocar), 0.11% (open), and 0.05% (direct). The corresponding vascular injury rates were 0.04, 0.01 and 0% respectively.[17] From the above studies, there is no clear evidence as to the optimal form of laparoscopy entry in low risk patient and it depends on the surgeon preference and experience with the individual technique.[17]

Disposable Shielded Trocar (Veress Trocar)

Disposable shielded 'safety' trocar when first introduced to the market in 1984, the manufacturer claimed that this trocar system works in a way that the sharp tip is and only becomes active and gets exposed when it encounter resistance through the abdominal wall. As it enters the abdominal cavity the sharp edge retract and the shield springs forward and cover the sharp tip of the trocar and the manufacturer wrote in the commercial label 'safety' trocars. These trocars were intended to avoid contact of the end of the trocar with the intra-abdominal content. However, it must be pointed out that even when this trocar was introduced correctly according to the recommended specification, there will be a moment when this trocar enters the peritoneal cavity and before its retraction, it will be in contact with abdominal content. This brief moment is sufficient to produce injury especially with its very sharp end. Disposable trocars require half the force required to introduce the classic reusable trocars. A retrospective study of 1,03,852 laparoscopy entry used the disposable shielded trocars and classic trocars showed the shielded trocars were responsible for 30% of serious injuries caused by laparoscopic entry, and two out of seven deaths caused by laparoscopic entry injury.[18] Many studies were done and all disputed the complete safety of these trocars. As it is very popular in the United States, most of these studies were published in the United States, this led the Federal Drug Association (FDA) to directly write to the manufacturers of shielded laparoscopic trocars requested that in the absence of clinical data showing reduced incidence of injuries, manufacturers and distributors voluntary eliminate safety claims from the label of shielded trocars (Fig. 3).[19]

Visual Entry Systems (Visiport)

These include the disposable optic trocars and the endo TIP visual cannula. These new technology aims to optimize the laparoscopic entry by facilitating entry under direct vision. Controlled randomized trials are required to assess their safety and proof their superiority to the traditional Veress needle and trocar/cannula system in order to justify their expensive cost (Fig. 4).[20]

Transversus Abdominis Plane Block

Abdominal field blocks have been around for a long time and have been extensively used as they are mostly technically unchallenging. They, however, provide limited analgesic fields, hence multiple injections are usually required. Traditionally, these blocks have blind

Fig. 3: Veress trocar



Fig. 4: Visiport

end points (pops) making their success unpredictable. The description of the landmark technique for performing transversus abdominis plane (TAP) block advocated a single entry point, the triangle of Petit, to access a number of abdominal wall nerves hence, providing more widespread analgesia.[21] More recently, ultrasound guided TAP block has been described with promises of better localization and deposition of the local anesthetic with improved accuracy.[22] The Journal of New York School of Regional Anaesthesia 2009;12:28-33 (Fig. 5).

DISCUSSION

Over the last two decades, rapid advances have made laparoscopic surgery a well-established procedure. However, because laparoscopy is relatively new, it still arouses controversy, particularly with regard to the best method for the creation of the pneumoperitoneum.

To establish the pneumoperitoneum, access to the peritoneal cavity can be gained through minilaparotomy and insertion of a laparoscopic trocar or Hasson trocar. Alternatively, an optical trocar can be blindly inserted into the peritoneal cavity, or a Veress needle may be inserted through the abdominal midline. The latter is the most frequently used technique.

Meta-analysis failed to reveal any safety advantage of an open technique when compared with a closed method of entry, in terms of both visceral and major vascular injury. It must be noted that the included randomized controlled trials had insufficient power to effectively demonstrate an advantage.[23]

Various studies have shown in Tables 1 to 7.

CONCLUSION

No single technique or instrument has been proved to eliminate laparoscopic entry-associated injury. Proper evaluation of the patient, supported by good surgical

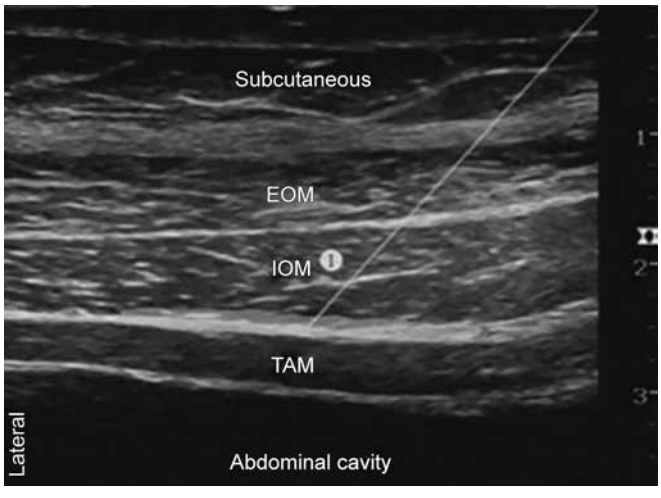

Fig. 5: Transversus abdominis plane block

Table 1: Incidence of laparoscopic complications according to Veress trocar (total no. 222)

Laparoscopic complications	*No. of patients*
Vascular injury	5
Visceral injury	0
Preperitoneal insufflations	5
Gas embolism	0
Bradycardia	2
Total	12 (5.40%)

Table 2: Incidence of laparoscopic complications according to Veress needle (total no. 31)

Laparoscopic complications	*No. of patients*
Vascular injury	0
Visceral injury	1 (omentum)
Preperitoneal insufflations	3
Gas embolism	0
Bradycardia	0
Total	4 (12.9%)

Table 3: Incidence of laparoscopic complication according to Visiport (total no. 20)

Laparoscopic complications	*No. of patients*
Vascular injury	1
Visceral injury	0
Preperitoneal insufflations	0
Gas embolism	0
Bradycardia	0
Total	1 (5%)

Table 4: Incidence of laparoscopic complications according to Hasson technique (total no. 10)

Laparoscopic complications	*No. of patients*
Vascular injury	1
Visceral injury	0
Preperitoneal insufflations	0
Gas embolism	0
Bradycardia	0
Total	1 (10%)

Table 5: Incidence of laparoscopic complications according to Palmer technique (total no. 20)

Laparoscopic complications	*No. of patients*
Vascular injury	1
Visceral injury	0
Preperitoneal insufflations	0
Gas embolism	0
Bradycardia	
Total	1 (5%)

Table 6: Incidence of laparoscopic complications according to sharp trocar (total no. 27)

Laparoscopic complications	*No. of patients*
Vascular injury	2
Visceral injury	1 (omentum)
Preperitoneal insufflations	0
Gas embolism	0
Bradycardia	
Total	3 (11.1%)

Table 7: Incidence of laparoscopic complications according to blunt trocar (total no. 30)

Laparoscopic complications	*No. of patients*
Vascular injury	2
Visceral injury	0
Preperitoneal insufflations	0
Gas embolism	0
Bradycardia	
Total	2 (10%)

skills and reasonably good knowledge of the technology of the instruments remain to be the cornerstone for safe access and success in minimal access surgery.

For initial peritoneal access, we suggest that surgeons should adhere to the technique with which they have the most experience. Overall, complication rates for laparoscopic access are not significantly difference between the Hasson and Veress needle techniques for abdominal insufflation when performed by experienced surgeons; however, the surgeon should be familiar with alternative technique.

REFERENCES

1. Jansen FW, Kolman W, Bakkum EA, Trimpos T, Trimpos JB. Complications of laparoscopy: an inquiry about closed *vs* open entry technique. Am J Obstet Gynecol 2004;190:634-638.
2. Yuzpe AA. Pneumoperitoneum needle and trocar injuries in laparoscopy: a survey on possible contributing factors and prevention. J Reprod Med 1990;35:485-490.
3. Garry R. Towards evidence based laparoscopic entry techniques: clinical problems and dilemma. Gynecol Endosc 1999;8:315-326.
4. Hakki-Siren, Kurki T. A nationwide analysis of laparoscopic complications. Obstet Gynecol 1997;89:108-112.
5. Palmer R. Safety in laparoscopy. J Reprod Med 1974;13:1-5.
6. Tulikangas RK, NIclas A, Falcone T, Price L. Anatomy of the left upper quadrant for cannula insertion. J Am Assoc Gynecol Laparosc 2000;7:21-24.
7. Hurd WW, Bude RO, DeLancey JO, Pearl ML. The relationship of the umbilicus to the aortic bifurcation: complications for laparoscopic technique. Obstet Gynecol 1992;80:48-51.
8. Wolfe WM, Pasic R. Trasuterine insertion of Veress needle in laparoscopy. Obset Gynecol 1990;75:456-457.
9. Tooh B, Sen R, Abbott J. An evaluation of four tests used to ascertain Veress needle placement at closed laparoscopy. J Minim Invasive Gynecol 2005;12:153-158.
10. Richardson RF, Sutton CJG. Complications of first entry: a prospective laparoscopic audit. Gynaecol Endosc 1999;8: 327-334.
11. Vilos GA, Artin T, Temamian A, Laberge PY. SOGC clinical practice guideline. J SOGC 2007;193:433-445.
12. Sutton CJG, Philip K. Preventing gynaecological injury. The Royal College of Obstetricians and Gynaecologist. Guideline No. 48 2007:1-10.
13. Audebert AJ, Gomel V. Role of microlaparoscopy in diagnosis of peritoneal and visceral adhesions and in prevention of bowl injury associated with blind trocar insertion. Fertil Steril 2000;73:631-635.
14. Hasson HM. A modified instrument and method for laparoscopy. Am J Obstst Gynecol 1971;110:886-887.
15. Catarci M, Carlini M, Santioro E. Major and minor injuries during creation of pneumopertoneum, a multicentre study of 12919 cases. Surg Endosc 2001;15:566-569.
16. Soper NJ, Swanstrom LL, Eubanks WS, editors. Mastery of endoscopic and laparoscopic surgry. 2nd ed. Philadelphia: Lippincott, Williams and Wilkins; 2005.
17. Molly D, Kalloo PD, Cooper M. Laparoscopy entry: a literature review and analysis of techniques and complications of primary port entry. Aust NZJ Obstet Gynaecol 2002;14:365-374.
18. Savill LE, Wood MS. Laparoscopy and major retroperitoneal vascular injuries. Surg Endosc 1995;9:1096-1110.
19. Wellis T. Shielded trocars and needles used for abdominal access during laparoscopy. Rockville MD; Department of Health and Human Services; 1996.
20. Mohamed AS. Laparoscopic entry: techniques complications and recommendations for prevention of laparoscopic injury. Laparoscopy Hospital, India. Thi-Qar Med J 2010;4(3):62-74
21. Rafi A. Abdominal field block: a new approach via the lumbar triangle. Anaesthesia 2001;56:102426.
22. Hebbard P, Fujiwara Y, Shibata Y, Royse C. Ultrasound-guided transversus abdominis plane block. Anaesth Inten Care 2007;35:616-617.
23. Ahmad G, Duffy JMN, Phillips K, Watson A. Laparoscopic entry techniques. Cochrane database of systematic reviews no. 162, Article ID CD006583, 2008.

10.5005/jp-journals-10033-1258

CASE REPORT

A Rare Case of Nocturnal Urinary Incontinence and Menouria after Lower Segment Cesarean Section

[1]Deepti Shrivastava, [2]SB Bhute, [3]S Jajoo, [4]Priyakshi Chaudhry

ABSTRACT

Misgav Ladach technique for lower segment cesarean section (LSCS) is considered advantageous universally but debate still continues about nonclosure in layers and further consequences, hence careful selection of cases and intraoperative decision of closure in layers is important if needed. The classical Youssef syndrome comprises of cyclic hematuria, amenorrhea, menouria, and complete urinary continence in a patient who had LSCS. Here by, we are presenting a case report of woman suffered with chronic pelvic pain, menouria, nocturnal enuresis after her LSCS done for obstructed labor, although not exactly same as Youssef syndrome but rare in occerence and relieved after adhesiolysis and gonadotropin release hormone (GnRH) analog therapy.

Keywords: Menouria, Nocturnal enuresis, Obstructed labor.

How to cite this article: Shrivastava D, Bhute SB, Jajoo S, Chaudhry P. A Rare Case of Nocturnal Urinary Incontinence and Menouria after Lower Segment Cesarean Section. World J Lap Surg 2015;8(3):107-109.

Source of support: Nil

Conflict of interest: None

INTRODUCTION

Lower segment cesarean section (LSCS) by Misgav Ladach technique is the most frequently performed surgery by obstetricians today.[1] Incidences of postoperative adhesions formation and urinary bladder endometriosis depend on indivisual immune response of patient and to a some extent on skill of operator and careful selection of patients. Recently peritoneal closure in two layers is documented by some studies to have lesser adhesion formation.[2,3]

Due to its fast and minimalist approach, it has been adopted by obstetricians worldwide but sometimes dense adhesions are presented as a complication afterward.[4] We are reporting one such case of overflow incontinence and menouria due to dense adhesions and bladder wall endometriosis following primary LSCS.

[1]Professor and Head, [2,3]Professor, [4]Resident

[1-4]Department of Obstetrics Gynecology, Jawaharlal Nehru Medical College and Acharya Vinoba Bhave Rural Hospital DMIMS, Wardha, Maharashtra, India

Corresponding Author: Deepti Shrivastava, Professor and Head, Jawaharlal Nehru Medical College and Acharya Vinoba Bhave Rural Hospital, DMIMS, Wardha, Maharashtra, India e-mail: deepti_shrivastava69@yahoo.com

CASE REPORT

A 23 years old, P1L1, was admitted with chronic pelvic pain, nocturnal bed wetting and cyclic hematuria during periods following her last cesarean section, performed 2 years earlier in view of prolonged second stage of labor. In day time she had frequency of urine but denied of any kind of incontinence. She was kept catheterized for 45 days postoperatively due to hematuria at the time of LSCS. She noticed menouria too, when she resumed her cycles after the LSCS. Her menstrual flow through the genital tract was average in volume.

Her general and systemic examination findings were normal. She had a transverse cesarean scar. Pelvic examination revealed a normal sized anteverted uterus with restricted mobility and induration felt through fornices. Ultrasonography (USG) revealed normal size uterus and normal urinary bladder and adnexae. Diagnostic hysterolaparoscopy with cystoscopy was planned. On cystoscopy, a small depression in posterior bladder wall was seen covered with clots, methylene blue was instilled through cervix to see any spillage from bladder wall but it was negative. From suspicious tissue, biopsy was sent for histopathological examination. On laparoscopy anterior surface of uterus was seen completely adherent to anterior abdominal wall and only upper surface of uterus was visualized surrounded by adhesions all over (Fig. 1).

To rule out any vesicouterine fistula and dissecting uterus, urinary bladder from anterior abdominal wall to make them free, laparotomy was done in same sitting. On laparotomy, after some adhesiolysis uterus was appeared sitting over the urinary bladder and densely fixed to anterior abdominal wall (Fig. 2). Even after complete separation of uterus and urinary bladder no fistulous track was observed in between, may be there was initial injury during primary LSCS which was healed up leaving behind some endometrial tissue in the bladder wall. Omental pad was kept in between uterus and urinary bladder. Postoperative period was uneventful. Biopsy from urinary bladder confirmed endometrial glands. She was discharged on injection Leuprolide 1.25 mg for 3 months.

Her urinary incontinence was totally resolved and when the patient resumed her cycles there was no menouria.

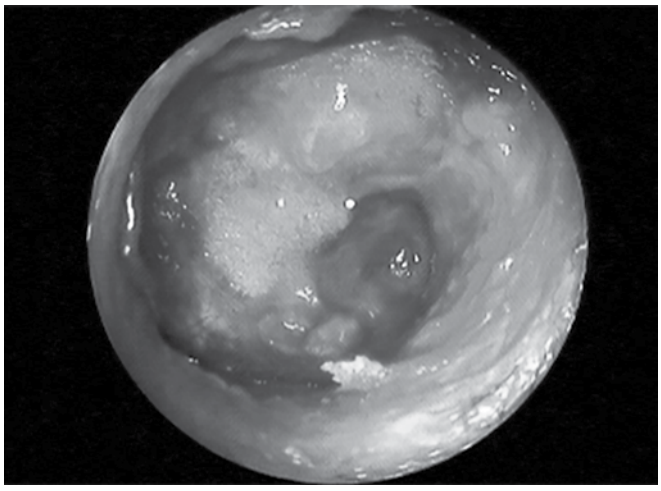

Fig. 1: Laparoscopy picture showing only upper surface of uterus was visualized surrounded all over by adhesions

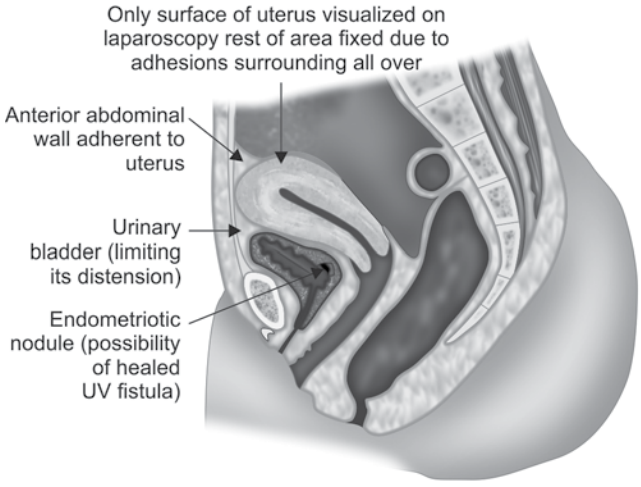

Fig. 2: Laparotomy picture, i.e. uterus adherent all around limiting distension of urinary bladder. Endometriotic nodule visualized on cystoscopy

DISCUSSION

Adhesion formation after cesarean section varies widely in incidence. Etiopathology of it is poorly understood. It is again debatable, whether peritoneal closure is beneficial or not.[2-4] endometriosis is defined as the presence of functional endometrial tissue outside the uterine cavity.[5,6] Endometriosis of the urinary bladder is an uncommon lesion and is seen in 1% of all cases of endometriosis.[7] It exists in two forms, primary and secondary. The primary form is generally a part of generalized pelvic disease, whereas the secondary is iatrogenic, that is, it occurs after pelvic surgery like cesarean section or hysterectomy.[7] In this case, it might had developed following prolonged second stage of labor or due to intraoperative trauma leading to Vesicouterine fistula, which was healed afterwards. Vesicouterine fistula is an uncommon urogenital fistula and accounts for 1 to 4% of all urogenital fistulas.[8] Cyclical hematuria or menouria is an important clinical feature of this fistula which may or may not be associated with urinary incontinence depending on the location of the fistulous tract.[6] The classical Youssef syndrome comprises of cyclic hematuria, amenorrhea, menouria, and complete urinary continence in a patient who had LSCS.[9] This is explained by the differential pressure gradient between the uterus and the bladder and the sphincteric action of the isthmus, which facilitates passage of blood from the uterus into the bladder.[9] Our case is not a classical Youssef's syndrome as the patient had incontinence. Dense adhesions between the anterior abdominal wall, uterus and bladder were noted on laparoscopy and confirmed on laparotomy. The anchoring effect of the uterus on bladder explains the overflow incontinence experienced by the patient. Total separation of uterus, urinary bladder and anterior abdominal wall by laparotomy relieved the urinary incontinence of the patient. The diagnosis of vesicouterine fistula (VUF) is often confirmed by imaging studies and cystoscopy.[7,9] Vesicouterine fistula following cesarean section may heal spontaneously with involution of the puerperal uterus. Spontaneous healing may occur in 5% of cases. When it does not, continuous hormonal therapy can be given to suppress menstruation for 3 to 6 months as first line of therapy. Suppression of menstruation can be tried with progestogens or GnRH analog[6] as is done in this case. The histopathology confirmed endometriosis of bladder wall.

CONCLUSION

Injuries to the bladder discovered at the time of cesarean section should be repaired immediately. If the diagnosis of a vesicouterine fistula is made in the early postoperative period, there have been a few reported cases of spontaneous closure of fistula with continuous urethral catheter drainage for 2 weeks with antibiotic cover.[8] Diagnosis of such cases are difficult due to nonspecific symptoms. High index of suspicion to all symptomatic women with a history of cesarean delivery or other gynecological surgery give a clue to the diagnosis.

Ultrasonography may be inconclusive. Cystoscopy and biopsy may give a clue to the diagnosis before surgery.[9] Treatment varies according to the severity and site of involvement of each case. Hormonal therapy does have a definite role in regressing the lesion.[6]

Although Misgav Ladach technique is advantageous in general for LSCS, care should be taken for proper selection of cases. Specially in cases of obstructed labor where bladder wall integrity is unpredictable, layerwise opening and closure is important to prevent postoperative complications.

REFERENCES

1. Shetty A, Fonseca M, Rao S, Badhwar VR. The Misgav Ladach Lower Segment Caesarean Section Experience at a Tertiary Hospital, Bombay Hospital Journal. Available at: www.bhj.org/journal/2003_4502_april/themisgav_294.htm.
2. Lyell, Deirdre J, Caughey, Aaron B, Hu, Emily, Daniels. Kay peritoneal closure at primary cesarean delivery and adhesions. Obstet Gynecol 2005 Aug;106(2):275-280.
3. Tulandi T, Al-Sunaidi M. Averting adhesions: surgical techniques and tools. Peritoneal closure at C-section reduces the risk of adhesions. J Family Practice 2007 Sep; 19(9):9.
4. Shi Z, Ma L, Yang Y, Wang H, Schreiber A, Li X, Tai S, Zhao X, Teng J, Zhang L, et al. Adhesion formation after previous caesarean section—a meta-analysis and systematic review. BJOG 2011 Mar;118(4):410-422.
5. Khetan N, Torkington J, Watkint A, Jamison MH, Humphreys WV. Endometriosis: presentation to general surgeons. Ann R Coll Surg Eng 1999;81(4):255-259.
6. Agarwal N, Kriplani A, Parul, Nabi G, Hemal AK, Karak AK. Intramural bladder endometriosis after cesarean section: diagnostic and Therapeutic Aspects. J Gynecol Surg 2002 Jun;18(2): 69-73.
7. Gupta S, Shah S, Motashaw ND, Shah N, Darshana V, Dave V. Case report: bladder wall endometrioma. Ind J Radiol Imaging 2001;11(1):23-24.
8. Abu J, Wong MYC, Foo KT, Yu SL. A case report on vesicouterine fistula: a very rare complication of the lower caesarean section. Singapore Med J 2000;41(11):554-556.
9. Shanmugasundaram R, Gopalakrishnan G, Kekre NS. Youssef's syndrome: is there a better way to diagnose? Indian J Urol 2008 Apr-Jun;24(2):269-270.