



# World Journal of Laparoscopic Surgery

*An Official Publication of the World Association of Laparoscopic Surgeons, UK*

*Editors-in-Chief*

**RK Mishra (India)**

**Jiri PJ Fronek (UK)**



**WJOLS**

Also available online at  
[www.jaypeejournals.com](http://www.jaypeejournals.com)  
[www.wjols.com](http://www.wjols.com)

Access Online Resources



For more details, visit  
[www.wjols.com](http://www.wjols.com)

*Bibliographic Listings:*

**ProQuest, Scopus, Journals Factor,  
EBSCO, Genamics JournalSeek, Emcare, HINARI, Embase,  
J Gate, Google Scholar, Ulrich, CiteFactor, SIS,  
OAJI, MIAR, SIF, COSMOS, ESJI, SJIF, SJR, IJIF, ICI**



**JAYPEE** Jaypee Journals

# Editorial

---

It is a recognized fact in surgical practice that randomized trials tend to be tougher to perform, thus many of the clinical research published in surgical treatment is carrying low level evidence. Practicing laparoscopic surgery as a minimal access surgeon seek evidence-based approaches to improve surgical outcomes of patient, but much of the current personalization of care remains largely empirical. Although substantial progress has been made in the field of laparoscopic and da Vinci Robotic Surgery, both anticipated and unanticipated barriers exist in integrating sequencing technologies into the care of patients who need minimal access surgery. Within the last decade there has been increasing enthusiasm for using evidence-based data to more precisely diagnose, predict outcomes, and prescribe 'targeted' therapies for surgical patients.



One of the important aims of the World Journal of Laparoscopic Surgery is to introduce individuals and the surgical community on the concepts of evidence-based surgery, to improve surgeon's interest in using an evidence-based approach in clinical practice and to reinforce the requirement for surgeons to get involved in surgical research. The top quality clinical research in surgery as well as the uptake of research that is certainly published are hampered because many surgeons have not developed the instruments or perhaps the methodology to critically appraise evidence.

In the coming issue of WJOLS, we will facilitate a platform which will help to transfer of these skills on the surgical community. In these series, articles will be focused around a surgical clinical scenario in the field of general surgery gynecology and urology with the appropriate methodology reviewed and discussed as it applies to using research in minimal access surgical practice. We are also going to make it online available as a series so, the surgeons and gynecologists have easy access of these evidence-based articles.

Once again I wish all the best to readers of WJOLS of this issue and seeking their valuable feedback.

**RK Mishra**  
Editor-in-Chief

# Laparoscopic Nissen-Rossetti Fundoplication: Possibility toward Day Care Antireflux Surgeries

Kaundinya Kiran Bharatam

## ABSTRACT

As we proceed towards more and more day care surgeries, we always need to choose patients and procedures within a great deal of safety margin. Antireflux surgeries are gaining more popularity and awareness and laparoscopic Nissen-Rossetti fundoplication is a safe and effective method of performing them. Our case series of 25 patients who underwent day care laparoscopic Nissen-Rossetti fundoplication done over a period of 3 years suggests the feasibility and safety of performing day care antireflux surgeries with no complications. Surgical outcomes of procedure are unaffected and the main challenge faced remains pain relief and which can be effectively tackled by local blocks or plain nonsteroidal anti-inflammatory drugs (NSAIDs). We encourage more studies in this regard with appropriate blinding to enforce its possibility as day care surgery and help patients with early recovery and decreasing cost of surgeries.

**Keywords:** Day care surgery, Gastroesophageal reflux disease, Laparoscopic Nissen-Rossetti fundoplication, Transversus abdominis plane block.

**How to cite this article:** Bharatam KK. Laparoscopic Nissen-Rossetti Fundoplication: Possibility toward Day Care Antireflux Surgeries. *World J Lap Surg* 2015;8(2):35-38.

**Source of support:** Nil

**Conflict of interest:** None

## INTRODUCTION

Antireflux problems and gastroesophageal reflux disease (GERD) have become common in the present day practice. The complications associated with GERD like stricture esophagus, adenocarcinoma of the esophagogastric junction (OGJ), pulmonary complications, etc. have prompted clinicians to adopt both medical and surgical options to treat this condition.<sup>1-4</sup> Proton pump inhibitors (PPIs) have been the mainstay of treatment in this condition and their usage can be up to 6 months continuously.

Assistant Professor, Consultant General and Surgeon

Department of General Surgery, Sri Ramachandra Medical College and Hospital; Department of Laparoscopy and Endoscopy, Mehta Hospitals, Chennai, Tamil Nadu, India

**Corresponding Author:** Kaundinya Kiran Bharatam, Assistant Professor, Consultant General and Surgeon, Department of General Surgery, Sri Ramachandra Medical College and Hospital; Department of Laparoscopy and Endoscopy Mehta Hospitals, Chennai, Tamil Nadu, India, e-mail: kaundinyakiran@gmail.com

pH measurement and esophageal manometry have also been supplemented by the Hill's grading system of GERD based on endoscopy to assess the severity of the disease.<sup>5</sup> Many studies have suggested that laparoscopic fundoplication is the most effective treatment in the long-term management of GERD.<sup>6</sup>

Laparoscopic Nissen-Rossetti fundoplication involves performing the fundic wrap after ensuring an adequate length of intra-abdominal esophagus, approximation of the crural hiatus and accentuation of the angle of His. This differs from the usual Nissen fundoplication by not having to divide the short gastric vessels along the gastrosplenic ligament. Thus, the procedure has an added advantage of decreasing operating time and minimizing intraoperative and postoperative blood loss.<sup>7</sup>

In the present article, we present 25 cases of GERD who underwent the laparoscopic Nissen-Rossetti fundoplication at our center during a period of around 3 years from 2012 to 2015 as a day care procedure (<24 hours stay). We would like to highlight the possibility of day care antireflux surgery using laparoscopic Nissen-Rossetti fundoplication.

## MATERIALS AND METHODS

For the period in observation, the following cases were selected for the day care fundoplication:

- Patients with GERD symptoms of more than 6 months duration
- Treatment given with PPIs for more than a month and patients being unresponsive to treatment
- Gastroesophageal reflux disease classification grade 3 to 4 based on Hill's system of classification of GERD using endoscopy
- Patients with American Society of Anesthesiologists (ASA) 1 to 2 fitness for surgery
- Patients consenting for the surgery as the choice of treatment for GERD.

Following patients were not selected for the day care procedure and underwent further evaluation or alternative treatment protocol:

- Patients unwilling for surgery as the choice of treatment for GERD
- Gastroesophageal reflux disease classification grade 1 to 2 based on Hill's system of classification of GERD using endoscopy

- Co-existent conditions like peptic ulcer disease or cholelithiasis as the causes for dyspepsia along with GERD symptoms
- Patient unfit for surgery.

## OBSERVATIONS

Following were the observations seen in the patient group:

- Total no. of cases—25
- Duration—2012 to 2015
- Study—retrospective analysis
- Center—single center and same team of surgeon, co-surgeon, and anesthetist
- Age of patients—from 25 to 65 years
- Sex of patients—predominantly females.

The patients once diagnosed were asked to undergo anesthesia fitness evaluation prior to surgery. Once fit for surgery, the patients were asked to come to the hospital early in the morning of the surgery on an empty stomach since the previous night after a short meal. The surgery was done within 2 to 3 hours of the admission.

The choice of procedure was laparoscopic Nissen-Rossetti fundoplication under general anesthesia and the procedure duration varied from 60 to 90 minutes. Postoperatively the patient was given pain relief by transversus abdominis plane (TAP) block intraoperative with sensorcaine (0.25%) and by nonsteroidal anti-inflammatory drugs (NSAIDs) like diclofenac sodium postoperative on a *si omni sit* (SOS) basis.<sup>8,9</sup> A pain score was chosen to subjectively assess the postoperative pain as a choice for the analgesia (>4). Postoperatively after 6 hours of surgery liquids were initiated to the patient and they were given liberally after an hour of tolerating the same. The patient was discharged for follow-up after having liquids.

Patients on follow-up day 3 were advised semisolid food and on day 7 were given soft diet. On day 7, the sutures were removed. Patient was given a choice of discharge in every instance and plan was to avoid discharge if the patient did not feel comfortable going home or if the pain was high.

Our observations during the postoperative period were as follows:

1. Average stay of patient in the hospital—12 to 16 hours
2. Postoperative pain score:
  - Score 1–4 20
  - Score 5–8 4
  - Score >8 1

All patients responded to oral NSAIDs if the pain score was high.

All the patients were willing for discharge postoperatively.

3. Postoperative complications:
  - Postoperative dysphagia/odynophagia 0
  - Postoperative bleeding 0
  - Postoperative respiratory complications 0
  - Postoperative wound complications 0
  - Postoperative complications unrelated to above 0
  - Readmission 0
  - Postoperative gas bloating symptoms 0
4. Follow-up relief in symptoms—100%

Our observations indicate that with a proper selection criterion, laparoscopic Nissen-Rossetti fundoplication can be offered as antireflux therapy to the patient as a day care procedure.

Laparoscopic Nissen-Rossetti fundoplication does not involve dividing the short gastric vessels, and thus allows a faster surgery with minimal bleeding. The fundic wrap is fashioned in a careful manner after creating a wide retroesophageal tunnel and ensuring that the wrap is not tight at all. Postoperative dysphagia, bleeding, gas bloating, etc. are usually not encountered but the patient is kept on a liquid diet for 3 days to allow the inflammation to subside along the wrap and prevent any discomfort to swallowing. Pain was the main challenge in the early discharge and was assessed using the pain score and it was found that patients usually were comfortable postoperatively with adequate local infiltration in the muscle planes during surgery at the port sites and also with one or two doses of NSAIDs like diclofenac sodium or paracetamol. None of the patients required readmission or felt the need to stay longer.

## DISCUSSION

A 360° fundoplication is the most common treatment for GERD presently especially for both acid and bile reflux in patients who respond poorly to the proton pump inhibitors. Even regression of Barrett's metaplasia after surgery has become the interest for physicians to advocate the procedure.<sup>10</sup>

Few papers have been published regarding the feasibility of laparoscopic Nissen fundoplication in day care setting and fewer are double cohort studies in this regard.<sup>11-13</sup>

Day care fundoplication was taken into consideration and the discharge criteria according to the postanesthesia discharge score system were: <20% deviation of pulse and blood pressure compared with preoperative values, balanced gait without dizziness, pain acceptable and pain regulated with oral analgesics, no excessive nausea and vomiting and minimal blood loss.<sup>14</sup> Other quality of life assessors were the EQ-5D—a simple questionnaire based on five dimensions: mobility, self-care, usual activity,

pain/discomfort, and anxiety/depression. Thus, highlighting that an approach toward day care fundoplication had begun whilst the possibility of day care cholecystectomy had already become evident and been brought into practice.

Simple acceptances of a procedure to be performed as day care needs to have no increased morbidity and mortality compared to in-patient procedure, high success rate of same day discharge and satisfied patients. Good pain relief can be brought in by local infiltration of the diaphragm as well as port site wounds supplemented by NSAIDs or likewise.<sup>14</sup>

Recently, new interventions to treat GERD have been developed like the magnetic sphincter positioned around the distal esophagus laparoscopically.<sup>15</sup> Here postoperative pain is almost negligible since the dissection is minimal. Thus, pain relief becomes a major criterion for deciding the feasibility of the surgical procedure to be considered as a day care procedure.

The Nissen-Rossetti fundoplication differs from the usual Nissen fundoplication in not having to divide the short gastric vessels during the fundic wrap creation. All the other operative steps are similar. This reduces the operative time and also decreases the blood loss in the surgery. In normal individuals this would even add to decreased postoperative pain since the dissection is less than the Nissen fundoplication procedure. The De Meester score postoperatively for the result of the procedure can assess the efficacy of the procedure. Symptomatic relief does remain the single best criteria for the outcome analysis of the procedure.<sup>16</sup>

Cost factor analysis also highlights the importance of choosing to perform the procedure in day care setting. Older concepts have changed when now the nasogastric tube is avoided in postoperative setting and early alimentation is also initiated for the patients. In elective setting of a clean surgery even prophylactic antibiotics are enough not necessitating long hospitalizations in view of medication administration or for parenteral alimentation. Pain relief and patient satisfaction remain the sole indices for the choice of continuing admission of the patient *vs* the day care procedure.

Dysphagia or odynophagia was another problem worrying the physician preventing early discharge of the patient. The procedure, differs in choosing the anterior or posterior gastric wall for the fundoplication. However, the dysphagia after the procedure did not differ in the choice of procedure and thus there was no harm done to the patient in choosing the Nissen-Rossetti procedure for the treatment of GERD for the patient. Other studies have also proposed that division of short gastric vessels is not necessary to perform a 'short and floppy' plication.<sup>17</sup>

## CONCLUSION

Laparoscopic Nissen-Rossetti fundoplication is effective for the treatment of GERD with severe grade or symptoms. It can be offered to the patient as day care procedure also but with proper selection criteria. More studies can be done prospectively and with appropriate blinding to prove the efficacy of this procedure as a day care option for antireflux surgery.

## ACKNOWLEDGMENTS

The authors acknowledge the efforts taken by the clinical staff at the hospital for their kind support for the cases operated and care given. We acknowledge the efforts of the doctors, anesthesiologist and surgical team for their contribution and efforts for successful recovery of the patient. Finally, we acknowledge the patients without whom this study would have not been possible and thank them for their kind informed consent.

## REFERENCES

1. De Meester SR, Campos GM, De Meester TR, et al. The impact of an antireflux procedure on intestinal metaplasia of the cardia. *Ann Surg* 1998 Oct;228(4):547.
2. De Meester TR, Bonavina L, Albertucci M. Nissen fundoplication for gastroesophageal reflux disease: evaluation of primary repair in 100 consecutive patients. *Ann Surg* 1986; 204(1):9.
3. De Meester TR, Bonavina L, et al. Chronic respiratory symptoms 1027 and occult gastroesophageal reflux. *Ann Surg* 1990 Mar;211(3):337.
4. De Meester SR, De Meester TR. Columnar mucosa and intestinal metaplasia of the esophagus: fifty years of controversy. *Ann Surg* 2000 Mar;231(3):303.
5. Hill LD, Kozarek RA, et al. The gastroesophageal flap valve. In vitro and in vivo observations. *Gastrointest Endosc* 1996; 44:541.
6. Korkolis DP, Kapritsou M, Konstantinou EA, Giannakopoulou M, Chrysi MS, Tsakiridou M, Kouloura A, Flamourakis M, Maricosu M, Gontikakis E, Plataniotis G. The impact of Laparoscopic Nissen fundoplication on the long-term quality of life in patients with gastroesophageal reflux disease. *Gastroenterol Nurs* 2015 Mar-Apr;38(2):111-115.
7. Bharatam KK, Maran M, Siva Raja PK. Laparoscopic Nissen Rossetti fundoplication in situs inversus totalis—a blessing in disguise. *Int J Surg Case Rep* 2014;5(12):1207-1209.
8. Gronnier C1, Desbeaux A, Piessen G, Boutillier J, Ruolt N, Triboulet JP, Mariette C. Day-case versus inpatient laparoscopic fundoplication: outcomes, quality of life and cost-analysis. *Surg Endosc* 2014 Jul;28(7):2159-2166.
9. Ripollés J, Mezquita SM, Abad A, Calvo J. Analgesic efficacy of the ultrasound-guided blockade of the transversus abdominis plane—a systematic review. *Braz J Anesthesiol* 2015 Jul-Aug;65(4):255-280.
10. Peyre CG, Watson TJ. Surgical management of Barrett's Esophagus. *Gastroenterol Clin North Am* 2015 Jun;44(2):459-471.
11. Milford MA, Paluch TA. Ambulatory laparoscopic fundoplication. *Surg Endosc* 1997;11(12):1150-1152.

12. NG R, Mullin EJ, Maddern GJ. Systematic review of day case laparoscopic Nissen fundoplication. *ANZ J Surg* 2005; 75(3):160-164.
13. Narain PK, Moss JM, DeMaria EJ. Feasibility of 23-hour hospitalization after laparoscopic fundoplication. *J Laproendosc Adv Surg Tech A* 2000;10(1):5-11.
14. Chung F. Recovery pattern and home-readiness after ambulatory surgery. *Anesth Analg* 1995;80(5):896-902.
15. Ganz RA. Long-term outcomes of patients receiving a magnetic sphincter augmentation device for gastroesophageal reflux. *Clin Gastroenterol Hepatol* 2015 Jun 1. pii:S1542-3565(15)00763-00766.
16. Moral MG, Reoyo PJ, León MR, Palomo LA, Rodríguez SS, Seco GJ. Laparoscopic Nissen fundoplication: results and prognostic factors. *Rev Gastroenterol Mex* 2012 Jan-Mar;77(1):15-25.
17. Tosato F, Marano S, Luongo B, Paltrinieri G, Mattacchione S, Bezzi M. Total fundoplication without division of the short gastric vessels: functional evaluation at 1 year and review of literature. *Minerva Chir* 2011 Apr;66(2):95-100.

# Veress Needle for Port-site Closure

<sup>1</sup>Balamurali Krishna Kotakala, <sup>2</sup>RK Mishra

## ABSTRACT

Port closure is essential after successful laparoscopic surgery to prevent incisional hernia. There are various devices like: fascial closure needle, Cobbler's needle and suture passer to close 10 mm ports in laparoscopic surgery. We have reported a novel technique for the closure of the ports after laparoscopic surgery. Using this simple technique, all the ports are closed under vision, thus preventing port herniation by using simple Veress needle.

**Keywords:** Laparoscopic port closure, Port closure technique, Veress needle.

**How to cite this article:** Kotakala BK, Mishra RK. Veress Needle for Port-site Closure. *World J Lap Surg* 2015;8(2):39-42.

**Source of support:** Nil

**Conflict of interest:** None

## INTRODUCTION

Minimal access surgery is a routine surgical practice due to its minimally invasive nature and associated advantages.<sup>1,2</sup> It has a lot of advantages but not devoid of complications, one of the major concerned complication is the trocar site herniation (TSH). Trocar site herniation is a serious complication often requiring emergency reoperation for repair. If unattended, TSH can lead to small bowel strangulation and incarceration.

The literature says that preventative measures should be taken to avoid the occurrence of herniation at the port-site.<sup>1,2</sup> Fascial closure has been recommended as a means of TSH prevention. One study reported a statistically higher frequency of hernias at 12 mm port-sites where the fascia was left open (8%) compared with those that were closed (0.22%) following laparoscopy.<sup>3</sup> There is a general consensus that all port-sites greater than or equal to 10 mm should be closed due to an increased risk of herniation.<sup>1,3,4</sup> For smaller ports fascial closure may not be necessary, except when manipulated extensively.<sup>5,6</sup>

Trocar site herniation is also associated with other technical factors other than the port-site. Port location is another factor. There are many reports suggesting that umbilical sites are at a greater risk of herniation when compared to lateral port-sites.<sup>1,7,8</sup> This is due to weakness of the fascia and absence of supporting muscle in this area.<sup>1,2</sup> Stretching or even extending the incision of a port-site during specimen extraction has a greater risk of hernia development.<sup>9,10</sup> Factors like high body mass index (BMI) are patient-related risk factors that are associated with TSH include.<sup>8,11-13</sup> Here it is related to the increased intra-abdominal pressure and increased abdominal wall thickness.<sup>2,14</sup> Studies show that wound infection is a predisposing factor to hernia development.<sup>15</sup> Therefore, closure of fascia is necessary for umbilical ports, port-sites that are stretched or enlarged for specimen retrieval, and trocar sites in obese patients.

There are a number of methods of port-site closure but there is no gold standard. Use of traditional suturing techniques are difficult due to blind closure of the fascial defect.<sup>16</sup> Varying degrees of success are achieved by modified hand suturing techniques.<sup>17-19</sup> Finding the rectus sheath and suturing through the layers of a thicker abdominal wall through a relatively small hole is challenging particularly in the obese.<sup>13,16</sup> In such cases, we need special instruments for efficient closure of the port-site. Veress needle is an instrument that is commonly used for creating pneumoperitoneum. In this study, veress needle has been used to close the port-site efficiently under vision.

## AIM OF THE STUDY

To show Veress needle is a safe, efficient and cost-effective tool for port-site closure.

## HISTORY OF VERESS NEEDLE

In 1938, Janos Veress of Hungary developed a specially designed spring-loaded needle. Interestingly, Veress did not promote the use of his Veress needle for laparoscopy purposes. He used Veress needle for the induction of pneumothorax.

But now Veress needle is the most important instrument today to create pneumoperitoneum.

## PARTS OF VERESS NEEDLE

Veress needle consists of an outer cannula with a beveled needle point for cutting through tissues. Inside the cannula of veress needle is an inner stylet, stylet is loaded

<sup>1,2</sup>Consultant

<sup>1</sup>Department of General Surgery, Kamala Nursing Home Marripalem, Visakhapatnam, Andhra Pradesh, India

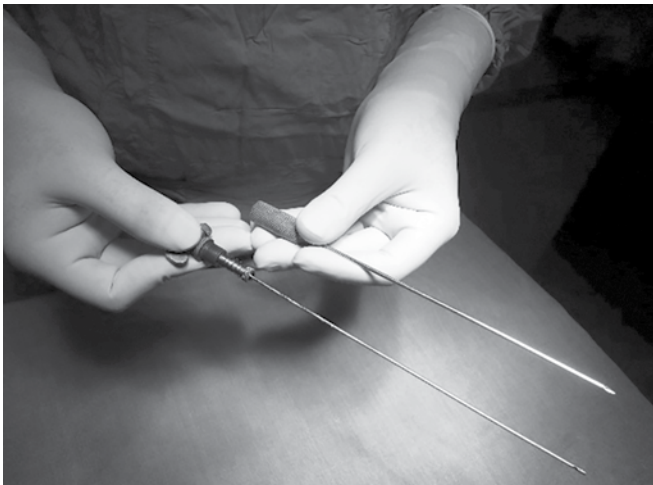
<sup>2</sup>Department of Minimal Access Surgery, World Laparoscopy Hospital, Gurgaon, Haryana, India

**Corresponding Author:** Balamurali Krishna Kotakala Consultant, Department of General Surgery, Kamala Nursing Home, Marripalem, Visakhapatnam, Andhra Pradesh India, Phone: +91-9885509966, e-mail: drbalamuralikrishna@gmail.com

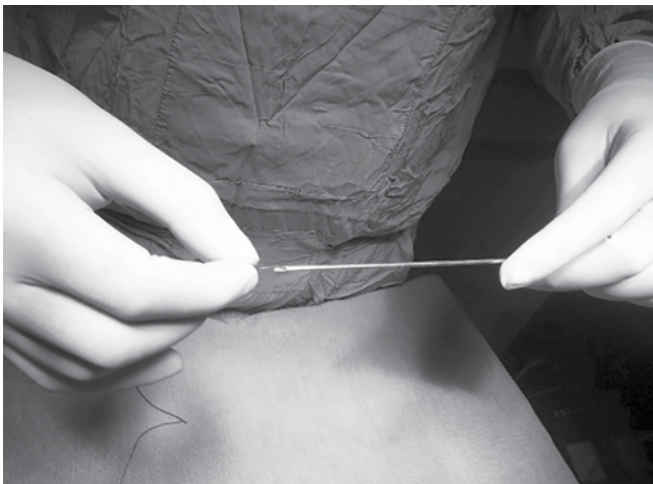
with a spring that spring forward in response to the sudden decrease in pressure encountered upon crossing the abdominal wall and entering the peritoneal cavity.

### TECHNIQUES

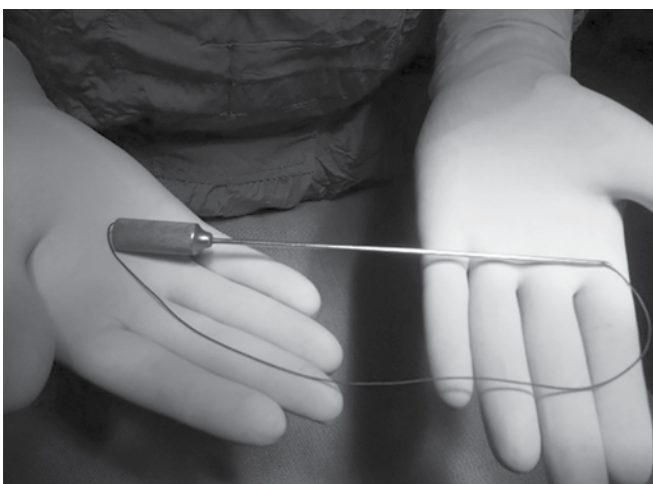
1. Remove the stylet from the cannula.



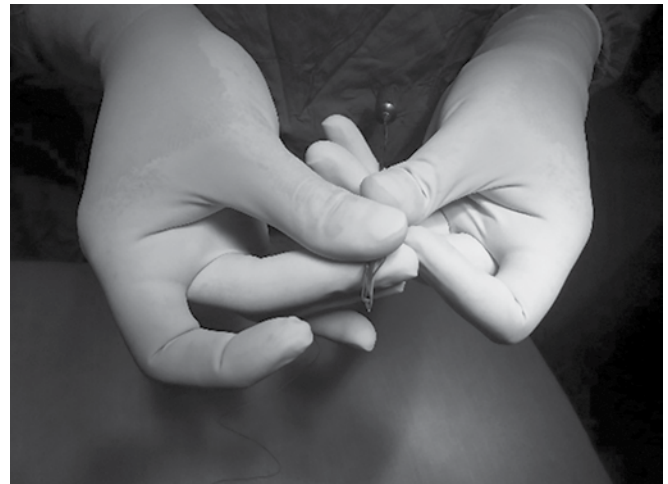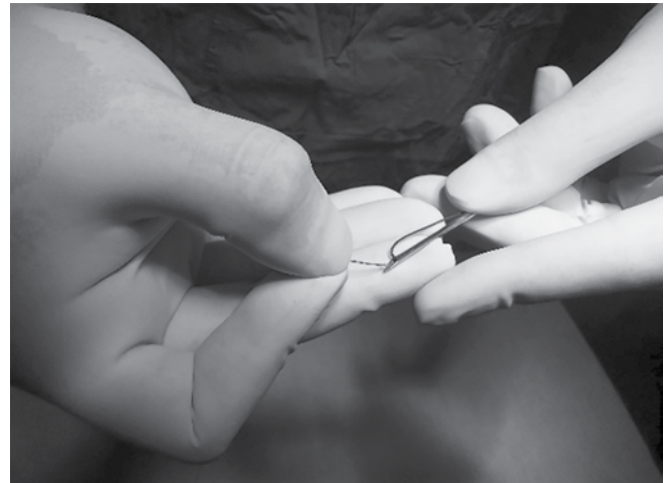2. Pass a suture material through the cannula from the tip



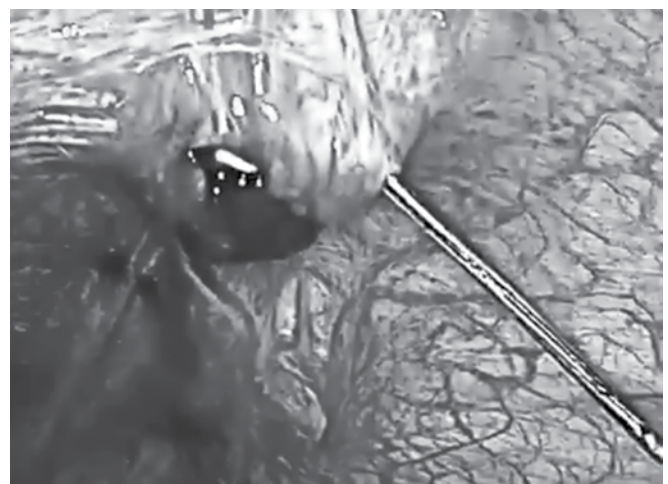
3. Tie the loop and hide the knot in the cannula



4. Insert the suture material (that should close the port-site) into the cannula tip about 2 cm deep and bend it so that it stays in place. Now it is ready.

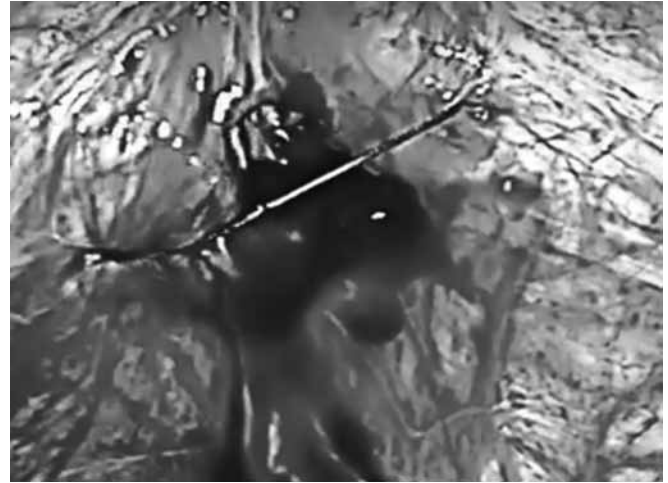
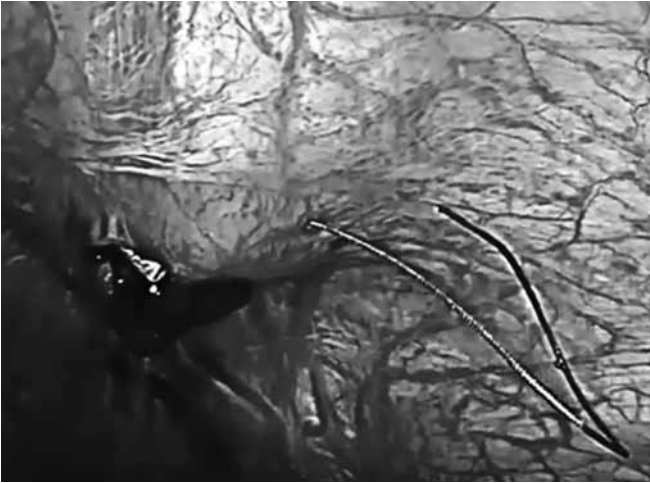
5. Occlude the port-site with a finger so that the pneumoperitoneum is maintained and pass the Veress beside the finger through all the layers except the skin and subcutaneous tissue under vision.






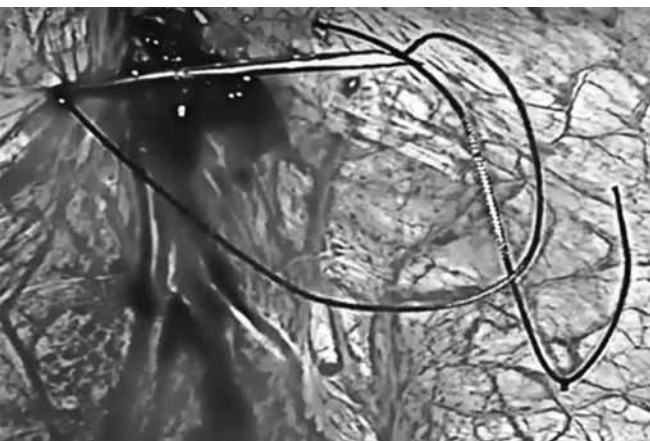
6. Retract the Veress and the suture is automatically retained inside.
9. Tighten the loop and retract the Veress along with the suture and tie the knot.



7. Insert the Veress from the other side of the defect



8. Entangle the suture in the loop of the Veress



Thus, the port-site is closed under vision and is a safe procedure.

#### **MATERIALS AND METHODS**

This is a retrospective study of 500 patients who underwent different laparoscopic procedures at World Laparoscopic Hospital, Gurgaon, from 2006 to till date.

#### **DISCUSSION**

Minimal access surgeries are the present and future of surgical procedures and no surgery is complete without port-site closure. There are a lot of methods to close the port-site but no gold standard. This study is

to evaluate the safety, efficacy and cost-effectiveness of the procedure.

One of the preventable complications is port-site incisional hernias (PIHs), which could develop at any port-site, most frequently at the midline, possibly because of the absence of supporting muscle. The incidence of PIH is variable from center to center, depending on several factors including surgical technique and, of course, surgical experience.

The trocar diameter, trocar design, pre-existing fascial defects, and some operation and patient-related factors, direction of the port insertion, use of a drain, and the site of the port are the risk factors for development of PIH.<sup>20</sup> In obese and bariatric patients because of the larger preperitoneal space and elevated intra-abdominal pressure, the risk of formation of trocar-site hernia is greater.<sup>21</sup> Size of the port is another major risk factor, and some authors advise closure of holes > 5 mm at the fascial level.<sup>22</sup>

In our study, all the port-sites of size 10 mm or greater were closed using a Veress needle and a through follow-up was done and there has been no incidences of port-site hernia.

## CONCLUSION

The meticulous closure of laparoscopic ports is important to prevent and reduce the chances of formation of port-site incisional hernia. Port-site closure by Veress needle is an efficient and safe technique done under vision and there is no need to buy additional equipment to close the port-site, thus cost-effective.

## REFERENCES

1. Owens M, Barry M, Janjua AZ, Winter DC. A systematic review of laparoscopic port-site hernias in gastrointestinal surgery. *Surg JR Coll Surg Edinb Irel* 2011;9:218-224.
2. Swank HA, et al. Systematic review of trocar-site hernia. *Br J Surg* 2012;99:315-323.
3. Kadar N, Reich H, Liu CY, Manko GF, Gimpelson R. Incisional hernias after major laparoscopic gynecologic procedures. *Am J Obstet Gynecol* 1993;168:1493-1495.
4. Lajer H, Widecrantz S, Heisterberg L. Hernias in trocar ports following abdominal laparoscopy: a review. *Acta Obstet Gynecol Scand* 1997;76:389-393.

5. Romagnolo C, Minelli L. Small-bowel occlusion after operative laparoscopy: our experience and review of the literature. *Endoscopy* 2001;33:88-90.
6. Yamamoto M, Minikel L, Zaritsky E. Laparoscopic 5 mm trocar site herniation and literature review. *J Soc Laparoendosc Surg* 2011;15:122-126.
7. Azurin DJ, Go LS, Arroyo LR, Kirkland ML. Trocar site herniation following laparoscopic cholecystectomy and the significance of an incidental pre-existing umbilical hernia. *Am Surg* 1995;61:718-720.
8. Uslu HY, et al. Trocar site hernia after laparoscopic cholecystectomy. *J Laparoendosc Adv Surg Tech A* 2007;17:600-603.
9. Shalhav AL, et al. Transperitoneal laparoscopic renal surgery using blunt 12 mm trocar without fascial closure. *J Endourol Soc* 2002;16:43-46.
10. Skipworth JRA, Khan Y, Motson RW, Arulampalam TH, Engledow AH. Incisional hernia rates following laparoscopic colorectal resection. *Int J Surg Lond Engl* 2010;8:470-473.
11. Parker HH 3rd, Nottingham JM, Bynoe RP, Yost MJ. Laparoscopic repair of large incisional hernias. *Am Surg* 2002;68:530-533.
12. Bowrey DJ, et al. Risk factors and the prevalence of trocar site herniation after laparoscopic fundoplication. *Surg Endosc* 2001;15:663-666.
13. Sanz-López R, et al. Incisional hernias after laparoscopic vs open cholecystectomy. *Surg Endosc* 1999;13:922-924.
14. Hussain A, et al. Long-term study of port-site incisional hernia after laparoscopic procedures. *J Soc Laparoendosc Surg* 2009;13:346-349.
15. Crist DW, Gadacz TR. Complications of laparoscopic surgery. *Surg Clin North Am* 1993;73:265.
16. Shaher Z. Port closure techniques. *Surg Endosc* 2007;21:1264-1274.
17. Lasheen AE, Elzeftawy A, Ahmed AHM, Lotfy WE. Anatomical closure of trocar site by using tip hole needle and redirecting suture hook. *Surg Endosc* 2010;24:2637-2639.
18. Su WH, et al. Port wound closure assisted by Foley catheter: an easier way to provide fascia security. *J Obstet Gynaecol Res* 2009;35:725-731.
19. Stringer NH, et al. New closure technique for lateral operative laparoscopic trocar sites: a report of 80 closures. *Surg Endosc* 1995;9:838-840.
20. Holzinger F, Klaiber C. Trocar site hernias: a rare but potentially dangerous complication of laparoscopic surgery. *Chirurg* 2002;73(9):899-904.
21. Eid GM, Collins J. Application of a trocar wound closure system designed for laparoscopic procedures in morbidly obese patients. *Obes Surg* 2005 Jun-Jul;15(6):871-873.
22. Baldassarre GE, Valenti G, Torino G, Prosperi Porta I, Valenti V, Campisi C. Small bowel evisceration after laparoscopic cholecystectomy: report of an unusual case. *Minerva Chir* 2006 Apr;61(2):167-169.

# Anastomotic Leak in Laparoscopic Colorectal Surgery: Risk Factors and Prevention

Abdullah Badawi

## ABSTRACT

**Background:** Anastomotic leakage (AL) is a common complication and still is a significant problem following laparoscopic colorectal surgery. Risk factors and prevention for AL are not well-defined.

**Methods:** A systematic search of electronic databases. Cohort, case-control studies and randomized controlled trials that examined clinical risk factors and prevention for AL were included.

**Conclusions:** In conclusion, tumor location  $\leq 6$  cm from the anal verge, tumor size  $> 5$  cm, preservation of the left colic artery, male gender, severe malnutrition, body mass index (BMI)  $\geq 25$ , preoperative Neoadjuvant therapy and steroid therapy, American Society of Anesthesiologists (ASAs) score  $\geq 3$ , tobacco abuse, operating time  $\geq 180$  minutes, precompression before stapler firing and multiple firing of the stapler are associated with increase the risk of developing AL. On the other hand, Improve nutritional status, control comorbidities, stop smoking at least 2 weeks before surgery and preoperative use of mechanical bowel preparation, assessment and subsequent adaptation of operative technique without multiple firings of stapler or precompression before stapler firings and the use of transanal tube postoperatively, showed decrease in the AL rate following laparoscopic colorectal procedures.

**Keywords:** Anastomotic leak, Colon cancer, Colorectal cancer, Laparoscopic colorectal surgery, Laparoscopy, Prevention of anastomotic leakage, Risk factor of anastomotic leakage.

**How to cite this article:** Badawi A. Anastomotic Leak in Laparoscopic Colorectal Surgery: Risk Factors and Prevention. *World J Lap Surg* 2015;8(2):43-47.

**Source of support:** Nil

**Conflict of interest:** None

## BACKGROUND

Anastomotic leakage (AL) is a common complication and still is a significant problem following laparoscopic colorectal surgery. Risk factors for AL are not well-defined. Herein, data analysis and systematic review to quantify the predictive risk factors for AL and prevention in

patients who underwent laparoscopic colorectal surgeries were collected.

## METHODS

A systematic search of electronic databases (PubMed, NCBI, Annals journal, WJOLS, SLS journal, WJGS, Medscape and UpToDate) for 31 studies published from January 2009 to September 2015 was performed. Cohort, case-control studies and randomized controlled trials that examined clinical risk factors and prevention for AL were included.

## INTRODUCTION

Since the beginning of laparoscopic surgery, minimally access techniques have been used by surgeons and gynecologists for multiple elective procedures, some emergency procedures, benign and malignant tumors. In 1987, big step toward the minimally invasive techniques and away from more invasive open techniques, after the promising outcome of the laparoscopic cholecystectomy.<sup>40</sup> The first laparoscopic colectomy was reported in 1991 by Jacobs et al and showed better outcome and less recovery period.<sup>41</sup>

Many surgeons performed laparoscopic colectomy for benign diseases, oncologic concerns made the application of minimally access surgery (MAS) to malignant colorectal disease slow.<sup>42</sup> By the time, after numerous studies (randomized controlled trials) comparing laparoscopic to open surgery for colon cancer were published, were showed that in experienced hands, appropriate oncologic resections can be performed and the results of laparoscopic techniques equivalent to the open techniques.<sup>43-46</sup> After the minimally access procedures became widely accepted, many surgical innovators and industries develop new technology with even less invasive approaches. Single-incision laparoscopic surgery (SILS) allows the surgeons to operate through single incision.<sup>48</sup> Robotic procedures at the beginning was popular in other specialties, such as urology, and some surgeries for rectal cancer to overcome the limitations of conventional laparoscopy in the confined working space of the pelvis.<sup>49,50</sup> In 2000, the da Vinci Surgery System broke new ground by becoming the first robotic surgery system approved by the FDA for general laparoscopic surgery.

Surgical Resident

Department of Surgery, King Abdulaziz General Hospital and Trauma Center, Jeddah, Saudi Arabia

**Corresponding Author:** Abdullah Badawi, Surgical Resident, Department of Surgery, King Abdulaziz General Hospital and Trauma Center, Jeddah, Saudi Arabia, Phone: 00966126375555, e-mail: dr.abdullah\_badawi@hotmail.com

Natural orifice transluminal endoscopic surgery (NOTES) to colorectal disease has not yet fully transpired, though there have been major advances as instrumentation improves and transitional techniques allow natural orifice specimen extraction following laparoscopic colorectal surgeries.<sup>51-54</sup>

## AIM

The aim of this paper is to review the published studies regarding the risk factors and the prevention of AL following MAS for colorectal cancer.

## CONTENT

Anastomotic fistula after colorectal surgery represents a major and potentially life-threatening postoperative complication. The incidence rate has been reported to be as high as 1 to 19%.<sup>6,36,37,38,55-58</sup> Mortality rate postoperatively associated with anastomotic complications ranges from 3 to 20%.<sup>6,56,58,59</sup> and accounts for approximately 30% of all deaths following colorectal surgery.<sup>60</sup> There is still three significant diversity between surgeons in what they define as AL. In a systematic review of gastrointestinal anastomotic leakage, 49 papers were found with 29 different definitions.<sup>61</sup> In 2010, specific guidelines on the definition of an anastomotic leak with a grading system of severity following rectal surgery were published by the International Study Group of Rectal Cancer.<sup>62</sup> According to that paper, AL should be defined as a defect of the intestinal wall at the anastomotic site (including suture and staple lines of neo-rectal reservoirs) leading to a communication between the intra- and extra-luminal compartments.

## MATERIALS

### Studies Population

From the 31 studies published from January 2009 to September 2015 involving 6,921 patients underwent elective laparoscopic colorectal procedures with stapling technique (ST) anastomosis.

## RESULT

### Tumor Location

The selected data showed that the overall AL rate was 6.21% (430/6921 patients). A total of 6,921 patients, male patients represented (63.2%) with a median age of 65 (50–74) years at the time of surgery were included. Data analysis showed that most common risk factor for leakage in all papers was distance of the anastomosis from the anal verge.<sup>1-4</sup> The lower the anastomosis (almost below 6 cm) the higher is the risk of developing fistula.

Vitali-Goriainov and Andrew J Miles showed in their study the height of anastomosis has been shown to affect the incidence of anastomotic leak and a life-threatening clinical AL occurred in anastomosis lower than (6 cm). Lopez-Kostner et al showed the rate of leak was 8.4% when it was below 10 cm from the anal verge, 5.4% when it was 10 to 15 cm from the anal verge and 0.14% when the anastomoses was above 15 cm, in a study performed on 819 patients with rectal or sigmoid cancers.<sup>5</sup> Rullier et al have shown that the leak rate was 6.5 times higher in anastomoses located <5 cm from the anal verge, with overall leak rate of 13% in a study of 272 patients with consecutive anterior resections and<sup>6</sup> a leak rate of 7.7% after low rectal stapling (<7 cm of the anal verge) compared with 1% for high stapling, reported by Vignali et al in a review of 1014 patients with stapled rectal anastomoses.<sup>7</sup> A study of laparoscopic anterior resection with intracorporeal rectal transection and double-stapling technique (DST) anastomosis for rectal cancer showed results suggest that tumor localization and preservation of the left colic artery are predictive factors for clinical AL.<sup>35</sup>

### Tumor Size

Multiple studies suggest that tumor size is risk factor for an anastomotic leak (tumor size >5 cm).<sup>38-63</sup>

### Transanal Tube

Transanal tube placement was effective for prevention of AL following laparoscopic low anterior resection and decreases the risk of reoperation after symptomatic leakage. In study performed on 96 patients, a transanal tube was placed after anastomosis, the frequency of leakage was 4.2% (4/96) in group with transanal tube and was 13.8% (15/109) in group without transanal tube. The rate of leakage was significantly lower in with transanal tube.<sup>34</sup>

### Mechanical Bowel Preparation

There is good evidence supporting the use of mechanical bowel preparation (MBP) in the preoperative management of patients undergoing elective right-sided and left-sided colorectal surgical resections. In another study showed no evidentiary indications for more severe complications in patients without preoperative bowel preparation.<sup>39</sup>

### Surgical Technique

Important risk factor for anastomotic leak was precompression before stapler firings. Study of 154 rectal cancer patients who underwent laparoscopic LAR with DST showed precompression before stapler firings and

multiple firings of the linear stapler, were significantly associated with AL.<sup>37</sup> Most probably, it will affect the blood supply to the anastomotic site.

Several studies confirmed that laparoscopic colorectal surgery improved early postoperative outcomes in terms of reduced intraoperative blood loss, postoperative pain, ileus and hospital stay.<sup>8-10</sup>

### Men vs Women

Anastomotic leakage after colorectal anastomosis was reported to be more common for men. Law et al reported in their study male gender as a risk factor for AL after low anterior resection.<sup>11</sup> Rullier et al have showed that fistula was 2.7 times higher in men compared to women after analyzing variables associated with AL in 272 consecutive anterior resections.<sup>6</sup> A systematic review and meta-analysis of 4,580 patients and an analysis of 753 patients showed that men more to have anastomotic leak than women.<sup>36,38</sup> Lipska et al also showed in a study of 541 patients that men are at a higher risk. The rate of AL increases in men with previous abdominal surgery, rectal cancer lower than 12 cm from the anal verge or prolonged operating time. The risk of AL increased when two or more risk factors were present.<sup>12</sup>

### Body Mass Index

Most of studies reported that body mass index (BMI)  $\geq 25$  is risk factor for AL.<sup>38</sup>

### Malnutritions

Malnutrition can affect the healing process of the anastomosis. A study showed that significant effects on colonic AL and wound infection can occur only with severe degrees of malnutrition.<sup>13</sup> Malnutrition exerts an adverse effect on tissue healing by affecting processes, such as collagen synthesis or synthesis of sulfated mucopolysaccharides or affecting fibroblast proliferation. Some studies have showed a relationship between preoperative serum albumin level and the occurrence of anastomotic fistulas and the reduction of value of serum albumin in 5th POD were the factors that were associated significantly with the development of clinical AL.<sup>6</sup>

Study reported a rate of 6.9% of fistula in patients with albumin level less than 3 mg/dl, and 2.8% incidence of fistulae for the patients with the level of serum albumin higher.<sup>14</sup> Several studies reported a preoperative serum albumin level less than 3.5 g/dl to be a significant risk factor for anastomotic leaks.<sup>15-18</sup>

### Hemoglobin and Blood Transfusion

The level of hemoglobin preoperatively and in 5th POD was not significant risk factors. Recent studies have

suggested a negative role of blood transfusions in the outcome of patients with cancer.<sup>19-22</sup> Blood transfusions lead to depression of the immune system increasing the risk of postoperative infectious complications and the incidence of anastomotic fistulas. Study showed that blood transfusions increase the incidence of anastomotic abscess and poor healing of anastomoses.<sup>23</sup> Study also found that postoperative blood transfusion is an independent predictive factor for anastomotic leakage.<sup>24</sup>

### American Society of Anesthesiologists (ASAs) Score

Most authors, the American Society of Anesthesiologists (ASAs) score  $\geq 3$  was associated with an increased risk for anastomotic leak.<sup>25-28</sup> Around the 2.5 times increased risk of anastomotic leak with every unit increase in the ASA score.<sup>29</sup> Another author confirmed high ASA grade as independent risk factor for anastomotic leak.<sup>30</sup> Medical comorbidities (pulmonary, cardiac, renal) are risk factor for AL.

### Operation Time

Operating time  $\geq 180$  minutes identified as a risk factor.

### Neoadjuvant Therapy and Steroid Therapy

Neoadjuvant therapy tended to be associated with the development of AL. Preoperative chemotherapy reported as risk factor for anastomotic leak.<sup>38</sup> Chronic steroid therapy was significantly associated with leaks.<sup>14,18,31,32</sup> In a study showed that, the incidence of AL was significantly higher in seven patients treated with long-term corticosteroids (50% leak) and in patients taking corticosteroids preoperatively (19% leak).<sup>33</sup>

### OTHER FACTORS

Data analysis demonstrated that AL was more common in patients with tobacco abuse. Not significant with Alcohol abuse.<sup>36</sup>

### CONCLUSION

Colorectal anastomotic leak is one of the most common complications of laparoscopic colorectal surgeries. In conclusion, tumor location  $\leq 6$  cm from the anal verge, tumor size  $> 5$  cm, preservation of the left colic artery, male gender, severe malnutrition, BMI  $\geq 25$ , preoperative Neoadjuvant therapy and steroid therapy, ASA score  $\geq 3$ , tobacco abuse, operating time  $\geq 180$  minutes, pre-compression before stapler firing and multiple firing of the stapler are associated with increase the risk of developing AL. On the other hand, Improve nutritional status, control comorbidities, stop smoking at least 2 weeks before surgery and preoperative use of mechanical bowel

preparation, assessment and subsequent adaptation of operative technique without multiple firings of stapler or precompression before stapler firings and the use of transanal tube postoperatively, showed decrease in the AL rate following laparoscopic colorectal procedures.

## REFERENCES

1. Heald RJ, Leicester RJ. The low stapled anastomosis. *Br J Surg* 1981;68(5):333-337.
2. Kockerling F, et al. Laparoscopic colorectal anastomosis: risk of postoperative leakage. Results of a multicenter study. Laparoscopic Colorectal Surgery Study Group (LCSSG). *Surg Endosc* 1999;13(7):639-644.
3. Boccola MA, et al. Risk factors and outcomes for anastomotic leakage in colorectal surgery: a single-institution analysis of 1576 patients. *World J Surg* 2011;35(1):186-195.
4. Damen N, et al. Anastomotic leaks in colorectal surgery. *ANZ J Surg* 2014;84(10):763-768.
5. Lopez-Kostner F, Lavery IC, Hool GR, Rybicki LA, Fazio VW. Total mesorectal excision is not necessary for cancers of the upper rectum. *Surg* 1998;124(4):612-617; discussion 617-618.
6. Rullier E, Laurent C, Garrelon JL, Michel P, Saric J, Parneix M. Risk factors for anastomotic leakage after resection of rectal cancer. *Br J Surg* 1998;85(3):355-358.
7. Vignali A, et al. Factors associated with the occurrence of leaks in stapled rectal anastomoses: a review of 1,014 patients. *J Am Coll Surg* 1997;185(2):105-113.
8. Lacy AM, et al. Laparoscopy-assisted colectomy vs open colectomy for treatment of nonmetastatic colon cancer: a randomised trial. *Lancet* 2002;359(9325):2224-2229.
9. Guillou PJ, et al. Short-term endpoints of conventional versus laparoscopic-assisted surgery in patients with colorectal cancer (MRC CLASICC trial): multicentre, randomised controlled trial. *Lancet* 2005;365(9472):1718-1726.
10. Veldkamp R, et al. Laparoscopic surgery vs open surgery for colon cancer: short-term outcomes of a randomised trial. *Lancet Oncol* 2005;6(7):477-484.
11. Law WI, Chu KW, Ho JW, Chan CW. Risk factors for anastomotic leakage after low anterior resection with total mesorectal excision. *Am J Surg* 2000;179(2):92-96.
12. Lipska MA, Bissett IP, Parry BR, Merrie AE. Anastomotic leakage after lower gastrointestinal anastomosis: men are at a higher risk. *ANZ J Surg* 2006;76(7):579-585.
13. Kwag SJ, Kim JG, Kang WK, Lee JK, Oh ST. The nutritional risk is a independent factor for postoperative morbidity in surgery for colorectal cancer. *Ann Surg Treat Res* 2014;86(4):206-211.
14. Golub R, Golub RW, Cantu R Jr, Stein HD. A multivariate analysis of factors contributing to leakage of intestinal anastomoses. *J Am Coll Surg* 1997;184(4):364-372.
15. Kumar A, et al. Anterior resection for rectal carcinoma-risk factors for anastomotic leaks and strictures. *World J Gastroenterol* 2011;17(11):1475-1479.
16. Kingham TP, Pachter HL. Colonic anastomotic leak: risk factors, diagnosis, and treatment. *J Am Coll Surg* 2009;208(2):269-278.
17. Ionescu D, Tibrea C, Puia C. Preoperative hypoalbuminemia in colorectal cancer patients undergoing elective surgery—a major risk factor for postoperative outcome. *Chirurgia (Bucur)* 2013;108(6):822-828.
18. Suding P, Jensen E, Abramson MA, Itani K, Wilson SE. Definitive risk factors for anastomotic leaks in elective open colorectal resection. *Arch Surg* 2008;143(9):907-911.
19. Alves A, Panis Y, Trancart D, Regimbeau JM, Pocard M, Valleur P. Factors associated with clinically significant anastomotic leakage after large bowel resection: multivariate analysis of 707 patients. *World J Surg* 2002;26(4):499-502.
20. Telem DA, Chin EH, Nguyen SQ, Divino CM. Risk factors for anastomotic leak following colorectal surgery: a case-control study. *Arch Surg* 2010;145(4):371-376.
21. Lai R, Lu Y, Li Q, Guo J, Chen G, Zeng W. Risk factors for anastomotic leakage following anterior resection for colorectal cancer: the effect of epidural analgesia on occurrence. *Int J Colorectal Dis* 2013;28(4):485-492.
22. Lujan JJ, Nemeth ZH, Barratt-Stopper PA, Bustami R, Koshenkov VP, Rolandelli RH. Factors influencing the outcome of intestinal anastomosis. *Am Surg* 2011;77(9):1169-1175.
23. Tadros T, Wobbes T, Hendriks T. Blood transfusion impairs the healing of experimental intestinal anastomoses. *Ann Surg* 1992;215(3):276-281.
24. Boccola MA, et al. Risk factors and outcomes for anastomotic leakage in colorectal surgery: a single-institution analysis of 1576 patients. *World J Surg* 2011;35(1):186-195.
25. Choi HK, Law WL, Ho JW. Leakage after resection and intraperitoneal anastomosis for colorectal malignancy: analysis of risk factors. *Dis Colon Rectum* 2006;49(11):1719-1725.
26. Alves A, Panis Y, Pocard M, Regimbeau JM, Valleur P. Management of anastomotic leakage after nondiverted large bowel resection. *J Am Coll Surg* 1999;189(6):554-559.
27. Biondo S, et al. Anastomotic dehiscence after resection and primary anastomosis in left-sided colonic emergencies. *Dis Colon Rectum* 2005;48(12):2272-2280.
28. Makela JT, Kiviniemi H, Laitinen S. Risk factors for anastomotic leakage after left-sided colorectal resection with rectal anastomosis. *Dis Colon Rectum* 2003;46(5):653-660.
29. Buchs NC, Gervaz P, Secic M, Bucher P, Mugnier-Konrad B, Morel P. Incidence, consequences, and risk factors for anastomotic dehiscence after colorectal surgery: a prospective monocentric study. *Int J Colorectal Dis* 2008;23(3):265-270.
30. Bakker IS, Grossmann I, Henneman D, Havenga K, Wiggers T. Risk factors for anastomotic leakage and leak-related mortality after colonic cancer surgery in a nationwide audit. *Br J Surg* 2014;101(4):424-432.
31. Konishi T, Watanabe T, Kishimoto J, Nagawa H. Risk factors for anastomotic leakage after surgery for colorectal cancer: results of prospective surveillance. *J Am Coll Surg* 2006;202(3):439-444.
32. Tresallet C, Royer B, Godiris-Petit G, Menegaux F. Effect of systemic corticosteroids on elective left-sided colorectal resection with colorectal anastomosis. *Am J Surg* 2008;195(4):447-451.
33. Sliker JC, et al. Long-term and perioperative corticosteroids in anastomotic leakage: a prospective study of 259 left-sided colorectal anastomoses. *Arch Surg* 2012;147(5):447-452.
34. Hidaka E, et al. Efficacy of transanal tube for prevention of anastomotic leakage following laparoscopic low anterior resection for rectal cancers: a retrospective cohort study in a single institution. *Surg Endosc* 2015 Apr;29(4):863-867.
35. Yao HH, et al. Nomogram to predict anastomotic leakage after laparoscopic anterior resection with intracorporeal rectal transection and double-stapling technique anastomosis for rectal cancer. *Hepatogastroenterology* 2014 Jul-Aug;61(133):1257-1261.

36. Yang L, Xin-En H, Jian-Nong Z. Risk assessment on anastomotic leakage after rectal cancer surgery: an analysis of 753 patients. *Asian Pac J Cancer Prev* 2013;14(7):4447-4453.
37. Kawada K, Hasegawa S, Hida K, Hirai K, Okoshi K, Nomura A, Kawamura J, Nagayama S, Sakai Y. Risk factors for anastomotic leakage after laparoscopic low anterior resection with DST anastomosis. *Surg Endosc* 2014 Oct;28(10):2996-2997.
38. Qu H, Liu Y, Dong-song B. Clinical risk factors for anastomotic leakage after laparoscopic anterior resection for rectal cancer: a systematic review and meta-analysis. *Surg Endosc*, 2015 Mar 6. [Epub ahead of print].
39. Gubler G, Dincler S, Steurer J, Buchmann P. Outcome of anastomotic leakage after colorectal surgery in patients with or without preoperative mechanical bowel irrigation: an observational study. *Surgical Science* 2012;3:105-110.
40. W Reynolds Jr. The first laparoscopic cholecystectomy. *J Soc Laparoendosc Surg* 2001;5(1). p. 89-94.
41. Jacobs M, Verdeja JC, Goldstein HS. Minimally invasive colon resection (laparoscopic colectomy). *Surgical laparoscopy and Endoscopy* 1991;1(3):144-150.
42. Berends FJ, Kazemier G, Bonjer HJ, Lange JF. Subcutaneous metastases after laparoscopic colectomy. *Lancet* 1994; 344(8914):58.
43. Buunen M, et al. Survival after laparoscopic surgery vs opensurgery for colon cancer long-term outcome of a randomised clinical trial. *Lancet Oncol* 2009;10(1):44-52.
44. Fleshman J, Sargent DJ, Green E, et al. Laparoscopic colectomy for cancer is not inferior to open surgery based on 5-year data from the COST Study Group trial. *Ann Surg* 2007;246(4):655-662.
45. Jayne DG, Guillou PJ, Thorpe H, et al. Randomized trial of laparoscopic-assisted resection of colorectal carcinoma: Three-year results of the UK MRC CLASICC trial group. *J Clin Oncol* 2007;25(21):3061-3068.
46. Lacy AM, Delgado S, Castells A, et al. The long-term results of a randomized clinical trial of laparoscopy-assisted vs open surgery for colon cancer. *Ann Surg* 2008;248(1):1-7.
47. Cima RR, Pattana-arun J, Larson DW, Dozois EJ, Wolff BG, Pemberton JH. Experience with 969 minimal access colectomies: the role of hand-assisted laparoscopy in expanding minimally invasive surgery for complex colectomies. *J Am College Surg* 2008;206(5):946-950.
48. Froghi F, Sodergren MH, Darzi A, Paraskeva P. Single-incision laparoscopic surgery (SILS) in general surgery: a review of current practice. *Surg Laparosc Endosc Percutan Techniq* 2010;20(4):191-204.
49. Pigazzi A, Luca F, Patrì A, et al. Multicentric study on robotic tumor-specific mesorectal excision for the treatment of rectal cancer. *Ann Surg Oncol* 2010;17(6):1614-1620.
50. Zimmern A, Prasad L, Desouza A, Marecik S, Park J, Abcarian H. Robotic colon and rectal surgery: a series of 131 cases. *World J Surg* 2010;34(8):1954-1958.
51. Dozois EJ, Larson DW, Dowdy SC, Poola VP, Holubar SD, Cima RR. Transvaginal colonic extraction following combined hysterectomy and laparoscopic total colectomy: a natural orifice approach. *Techniques in Coloproctology* 2008;12(3):251-254.
52. Knol J, D'Hondt M, Dozois EJ, Boer JV, Malisse P. Laparoscopic-assisted sigmoidectomy with transanal specimen extraction: a bridge to NOTES? *Techniques in Coloproctology* 2009;13(1):65-68.
53. Park JS, Choi GS, Lim KH, et al. Clinical outcome of laparoscopic right hemicolectomy with transvaginal resection, anastomosis, and retrieval of specimen. *Dis Colon and Rectum* 2010;53(11):1473-1479.
54. Wolthuis AM, Penninckx F, D'Hoore A. Laparoscopic sigmoid resection with transrectal specimen extraction has a good short-term outcome. *Surg Endosc* 2011;25(6):2034-2038.
55. Rickert A, Willeke F, Kienle P, Post S. Management and outcome of anastomotic leakage after colonic surgery. *Colorectal Dis* 2010;12(10 online):e216-223.
56. Buchs NC, Gervaz P, Secic M, Bucher P, Mugnier-Konrad B, Morel P. Incidence, consequences, and risk factors for anastomotic dehiscence after colorectal surgery: a prospective monocentric study. *Int J Colorectal Dis* 2008;23(3):265-270.
57. Yeh CY, et al. Pelvic drainage and other risk factors for leakage after elective anterior resection in rectal cancer patients: a prospective study of 978 patients. *Ann Surg* 2005;241(1):9-13.
58. Hyman N, Manchester TL, Osler T, Burns B, Cataldo PA. Anastomotic leaks after intestinal anastomosis: it's later than you think. *Ann Surg* 2007;245(2):254-258.
59. Karanjia ND, Corder AP, Bearn P, Heald RJ. Leakage from stapled low anastomosis after total mesorectal excision for carcinoma of the rectum. *Br J Surg* 1994;81(8):1224-1226.
60. Alberts JC, Parvaiz A, Moran BJ. Predicting risk and diminishing the consequences of anastomotic dehiscence following rectal resection. *Colorectal Dis* 2003;5(5):478-482.
61. Bruce J, Krukowski ZH, Al-Khairy G, Russell EM, Park KG. Systematic review of the definition and measurement of anastomotic leak after gastrointestinal surgery. *Br J Surg* 2001;88(9):1157-1168.
62. Rahbari NN, et al. Definition and 12 grading of anastomotic leakage following anterior resection of the rectum: a proposal by the International study group of rectal cancer. *Surg* 2010; 147(3):339-351.
63. Kawada K, Hasegawa S, Hida K, Hirai K, Okoshi K, Nomura A, Kawamura J, Nagayama S, Sakai Y. Risk factors for anastomotic leakage after laparoscopic low anterior resection with DST anastomosis. *Surg Endosc* 2014 Oct;28(10):2988-2995.

# Laparoscopic Liver Resection: Current Status and Techniques

Sasidhar Reddy

## ABSTRACT

Laparoscopy has forever changed the landscape of surgery. Although hepatobiliary surgery remained the last bastion of 'maximal invasiveness,' recently there has been a rise in the implementation of laparoscopy for complex liver operations. Liver surgeons have been slow to adopt the laparoscopic technique for liver resections. This new approach has offered the patient an alternative to the traditional bilateral subcostal incision, and thereby tendered the marked benefits of limited incisions inherent to minimally invasive surgery.

As efficiency pressures continue to rise, the laparoscopic approach for liver resection will likely be further embraced. To this end, we surmise that the hybrid technique will gain favor, as it more closely assimilates the skills that hepatobiliary surgeons already possess.

Moreover, this technique offers the most palatable setting of safety with the use of the hand for liver mobilization and prompt control of bleeding vasculature.

Liver surgery, although initially late to embrace laparoscopy, is now gaining momentum in this paradigm shift. The advent of innovative tools that mirror what is used conventionally have facilitated this transition.

**Keywords:** Hybrid technique, Laparoscopic liver resection, Laparoscopy.

**How to cite this article:** Reddy S. Laparoscopic Liver Resection: Current Status and Techniques. *World J Lap Surg* 2015;8(2):48-51.

**Source of support:** Nil

**Conflict of interest:** None

## INTRODUCTION

Laparoscopy has forever changed the landscape of surgery. Although hepatobiliary surgery remained the last bastion of 'maximal invasiveness,' recently there has been a rise in the implementation of laparoscopy for complex liver operations. Liver surgeons have been slow to adopt the laparoscopic technique for liver resections.

Understandably, they are concerned about the control of bleeding, difficulty in retraction and exposure, and

the risk of air embolism. For malignant tumors, many expressed concerns about compromising oncological clearance and tumor seeding in the peritoneal cavity.<sup>1,2</sup> Despite these difficulties, instruments have improved and surgical techniques have been refined to ensure that laparoscopic liver resection is not only feasible and safe, but also beneficial in terms of blood loss, length of hospital stay, and severity of wound pain. More than a thousand laparoscopic liver resections have been performed worldwide since 1992, after Gagner et al<sup>3</sup> performed the first nonanatomical resection of a liver tumor. Although most of these involved resections of only one or two liver segments,<sup>4-7</sup> major hepatectomies have also been achieved laparoscopically.<sup>8-10</sup> While some attempted the relatively straightforward left lateral segmentectomy laparoscopically, it was not until the advent of the hand-assisted technique that formal liver resection became feasible for many hepatobiliary surgeons. This divergence from the purely laparoscopic instrumentation of the liver had many distinct advantages. Practically, the hand is the most useful retractor, offering expedient conformational change and unmatched haptic feedback. As such, intracorporeal hand insertion during laparoscopic resection gives the surgeon enhanced tactile stabilization of the liver, allowing for more precise mobilization and dissection of the target lobe. In addition, the hand port serves as a retrieval site for the surgical specimen. This new approach has offered the patient an alternative to the traditional bilateral subcostal incision, and thereby tendered the marked benefits of limited incisions inherent to minimally invasive surgery. This laparoscopic advance has extended into all forays of surgery with an ensuing decrease in incision size, which translates into less pain for the patient. With less pain comes earlier mobility, which results in decreased morbidity and reduced length of stay. Secondly, direct costs may be reduced with the use of laparoscopic techniques as a result of the earlier hospital discharge.

Heretofore laparoscopic hepatic resection has seemed far afield, but the subsequent innovation has shifted the paradigm. To this end, laparoscopy as applied to hepatic surgery is germane to discussions of 'best practices' and offers a technical approach that should be considered for many patients with liver pathology.

Senior Registrar

Department of Surgical Gastroenterology and Liver Transplantation, Sir Ganga Ram Hospital, New Delhi, India

**Corresponding Author:** Sasidhar Reddy, Senior Registrar Department of Surgical Gastroenterology and Liver Transplantation, Sir Ganga Ram Hospital, New Delhi, India, Phone: +917838046417, e-mail: drshashi2708@gmail.com



## RELATIVE CONTRAINDICATIONS TO LAPAROSCOPY

Although refractory hypotension is the only absolute contraindication to laparoscopy, there are many situations that make its use ill advised. In general, patients with an American Society of Anesthesiologists (ASA) classification of four or higher should not undergo laparoscopic procedures because hemodynamic instability is likely to arise in the setting of a pneumoperitoneum. As such, patients with poor cardiopulmonary reserve should temper the surgeon's enthusiasm for laparoscopic pursuits. However, rarely is the surgeon confronted with such obvious and straightforward clinical decisions.

The assessment of the risks and benefits of alternative operative approaches underscores the relative contraindications for laparoscopic liver resection. In our experience, patients who have had prior open foregut surgery are generally poor candidates for a laparoscopic approach, given the likely adhesive disease. Moreover, bulky pathology or hepatomegaly usually predicates open surgery, as hepatic mobilization can be problematic (Box 1). In contrast, laparoscopic resection for malignancy has been shown to be safe, which parallels the findings for treatment of other intra-abdominal organ cancers.

## OPERATIVE TECHNIQUES

Numerous methods of laparoscopic resection have gained popularity with increased sharing and collaboration in the surgical community. Recognizing the diversity of these laparoscopic techniques used for liver resection, a panel of 45 well-known hepatobiliary surgeons worked to establish a standard classification system and summarize a unified position statement on safety and efficacy of laparoscopic liver resection.

## PURE LAPAROSCOPY

Pure laparoscopy is usually used for wedge resections of anterior lesions of the liver or masses located in the left lateral segment, but it has been used for major lobe resections as well. Access is gained into the abdomen, depending on the surgeon's preference, and an umbilical 10 mm trocar is placed. After insufflation, the patient is moved into the reverse Trendelenburg position to enable

### Box 1: Relative contraindications to laparoscopic hepatic resection

- ASA classification  $\geq 4$
- Poor cardiopulmonary reserve
- Prior open foregut surgery
- Large (> 10 cm) posterior lesions
- Hepatomegaly

ASA, American Society of Anesthesiologists

sighting of the hilar structure and to position the small bowel in the lower abdomen and pelvis. Two to three trocars are placed under direct visualization to facilitate triangulation of the intended surgery site. Here, laparoscopic ultrasound is of great use to determine the depth of the mass and its juxtaposition to vasculature.

Lesions on the liver surface may be wedged out with the use of laparoscopic adaptations of the Harmonic scalpel (Ethicon EndoSurgery, Blue Ash, Ohio), LigaSure (Covidien, Boulder, Colo), Enseal (Ethicon Endo-Surgery, Blue Ash, Ohio), or any other bipolar energy device.

Generally, the hilum is dissected and the respective hepatic artery ligated and divided. The portal vein to the affected side is then clamped. Transection then begins in the usual fashion, and major vasculature is controlled with laparoscopic stapling devices. The major bile ducts are also stapled, and the specimen is extirpated through an extended umbilical incision. For this reason, it is more prudent to attempt larger resections with the alternative hand-assisted and hybrid techniques, given the similarity in the incision size.

## HAND-ASSISTED TECHNIQUE AND THE HYBRID TECHNIQUE

The incision that accommodates the hand port is the same for the hand-assisted and the hybrid techniques, there are some definitive differences. Both operative procedures employ the hand as a retractor, but hand-assisted liver resection implies that the resection is performed entirely intracorporeally. Conversely, the hybrid technique is a practice of using the hand to mobilize the liver with subsequent removal of the hand port so as to perform the liver transection in an open fashion without extending the incision.

Many favors the hybrid approach as they intuitively feel that this technique provides a more expeditious and practical manner for mobilization, parenchymal dissection, and removal of liver specimen. Here, I will describe the hybrid approach to liver resection, but the details are applicable to any system of laparoscopy using the hand.<sup>12</sup>

A 7.5 cm subxiphoid incision is made, and a hand port is inserted for hand assistance. A pneumoperitoneum is established after a standard Hassan trocar insertion periumbilically, and a 5 mm trocar is placed obliquely in the right or left subcostal margin depending on the location of the target lobe. The periumbilical trocar placement can be particularly risky because of its larger size and the relatively blind nature of insertion. This possibility can be minimized by introducing the trocar using the Hassan cut-down technique.

One hand should be placed into the abdomen through the subxiphoid incision to receive the trocar as the other

is used to gently advance the port-system through the fascia. After safe insufflation of the abdomen, the operation begins with mobilization of the liver after positioning the patient in reverse Trendelenburg.

Laparoscopic diathermic energy-based devices are used to divide the visceral attachments and triangular and coronary ligaments. The side of hepatic pathology dictates right or left hand insertion for hepatic lobe retraction.

The hand is an optimal retractor because of its ability to conform to the contours of the liver and displace pressure to the entire organ, preventing possible parenchymal injury. Hand assistance also promotes safety in affording the surgeon with an expedient method of manual control of hemorrhage during a potential vascular mishap.

Once the target liver lobe has been mobilized by division of all peritoneal reflections, the abdomen is exsufflated and the hand port is removed. Because exposure is of paramount importance, use of a retractor system is recommended. With adequate and uncompromised retraction, extrahepatic hilar vasculature ligation and division then ensue to lessen blood loss during liver transection.

Next, the parenchymal dissection through the hand port incision is accomplished with the aid of ultrasonography and ultrasonic surgical aspirators (CUSA, Integra LifeSciences Corp, Plainsboro, NJ) to identify the venous entities. During cases of major resection, the hanging maneuver as described by Dr Belghiti is used, with an umbilical tape passed anterior to the vena cava. Some ardently believe the biliary ductal system should be managed during intrahepatic dissection to prevent injury to the contralateral duct.<sup>11</sup>

For living donor hepatectomies, the hepatic artery, portal vein, and hepatic vein branches are kept intact as the parenchymal division is completed. The patient is then heparinized prior to the dissection of the target vascular structures and ultimate division. Subsequently, the specimen is removed through the hand port site.<sup>13</sup>

### **RIGHT HEPATECTOMY USING THE HYBRID TECHNIQUE**

After mobilization of the right hepatic lobe by division of the falciform and triangular ligaments, exsufflate the abdomen, remove the hand port, and secure the retractor system to expose the liver through the midline abdominal incision. Next, place lap pads behind the liver to bring the hilum into better view.

Prior to dissection, methodically palpate for a replaced right hepatic artery. The middle hepatic artery can be easily mistaken for a right hepatic artery, especially in the setting of a replaced artery, and division can have severe implications for segments 4A and 4B.

Ligate and divide the right hepatic artery and dissect posteriorly to delineate the portal vein. The right portal vein is circumferentially mobilized superiorly and divided. This devascularizes the right lobe inflow and results in demarcation of the liver. The right hepatic vein is then identified on the superior aspect of the liver and is divided using an articulating laparoscopic stapling device (EndoPath ETS, Ethicon Endo-Surgery, Blue Ash, Ohio) to ensure safe control of this very large vessel off of the inferior vena cava.

Using the aforementioned hanging maneuver, proceed with liver division, being mindful to stay to the right of the middle hepatic vein. We opt to ligate the right hepatic duct during intraparenchymal division because contralateral bile duct ischemia can occur if extrahepatic dissection is attempted. The specimen is then removed through this incision.

### **LEFT HEPATECTOMY USING THE HYBRID TECHNIQUE**

A left hepatectomy using the hybrid technique follows many of the same steps that were previously discussed. Again, one should be mindful of arterial variances, especially a replaced left hepatic artery coming from the left gastric artery. After correct identification and division of the middle and left hepatic arteries, dissection of the left portal vein begins by working posteriorly to the ligated arterial vasculature. Traditionally, the caudate lobe is spared in formal left hepatic lobe resections, and therefore, the surgeon should preserve the portal venous branches from the left portal vein into this segment. The middle and left hepatic veins are then divided with a laparoscopic stapling device, and parenchymal transection begins in the standard fashion.

In a recent study, some compared experience of conventional open liver resection to laparoscopic liver resection. As expectant, the laparoscopic approach with hand assistance and parenchymal dissection through the hand port incision had equivalent operative metrics with shortened length of stay.<sup>14,15</sup> Koffron et al have shown that laparoscopic resection is less expensive because of the shortened hospital stay. This finding reflects what has already been conclusively shown with laparoscopic cholecystectomy, fundoplication, and gastric bypass surgery.<sup>16,17</sup>

### **CONCLUSION**

Since Dr Jean Louis Lortat-Jacob<sup>18</sup> detailed the first published hepatectomy using the roadmap laid out by Claude Couinaud, the field of liver surgery has seen a celebrated rise in the capability to offer resection with lower rates of

morbidity and mortality. It is evident that with the arrival of the twenty-first century, the emergence of laparoscopy embodies a marriage of uncompromised surgical technique and better outcomes for patients.

Laparoscopy has emerged as an advancement that embodies these efforts to improve medical care and represents a significant change to the landscape of surgery. Liver surgery, although initially late to embrace laparoscopy, is now gaining momentum in this paradigm shift.<sup>19</sup> The advent of innovative laparoscopic tools that mirror what is used conventionally have facilitated this transition.

## REFERENCES

- Gagner M, Rogula T, Selzer D. Laparoscopic liver resection: benefits and controversies. *Surg Clin North Am* 2004;84(2): 451-462.
- Kaneko H. Laparoscopic hepatectomy: indications and outcomes. *J Hepatobiliary Pancreat Surg* 2005;12(6):438-443.
- Gagner M, Rheault M, Dubuc J. Laparoscopic partial hepatectomy for liver tumor. *Surg Endosc* 1992;6(2):99.
- Gigot JF, Glineur D, Santiago AJ, et al. Laparoscopic liver resection for malignant tumors: preliminary results of a multicenter European study. *Ann Surg* 2002;236(1):90-97.
- Descottes B, Glineur D, Lachachi F, et al. Laparoscopic liver resections of benign liver tumors. *Surg Endosc* 2003;17(1): 23-30.
- Mala T, Edwin B, Rosseland AR, Gladhaug I, Fosse E, Mathisen O. Laparoscopic liver resection: experience of 53 procedures at a single center. *J Hepatobiliary Pancreat Surg* 2005;12(4):298-303.
- Cherqui D, Laurent A, Tayar C, et al. Laparoscopic liver resection for peripheral hepatocellular carcinoma in patients with chronic liver disease: midterm results and perspectives. *Ann Surg* 2006;243(4):499-506.
- O'Rourke N, Fielding G. Laparoscopic right hepatectomy: surgical technique. *J Gastrointest Surg* 2004;8(2):213-216.
- Dulucq JL, Wintringer P, Stabilini C, Berticelli J, Mahajna A. Laparoscopic liver resection: a single center experience. *Surg Endosc* 2005;19(7):886-891.
- Vibert E, Perniceni T, Levard H, Denet C, Shahri NK, Gayet B. Laparoscopic liver resection. *Br J Surg* 2006;93(1):67-72.
- Belghiti J, Guevara OA, Noun R, et al. Liver hanging maneuver: a safe approach to right hepatectomy without liver mobilization. *J Am Coll Surg* 2001;193(1):109-111.
- Fong Y, Jarnagin W, Conlon KC, et al. Hand-assisted laparoscopic liver resection: lessons from an initial experience. *Arch Surg* 2000;135(7):854-859.
- Thenappan A, Jha RC, Fishbein T, et al. Liver allograft outcomes after laparoscopic-assisted and minimal access live donor hepatectomy for transplantation. *Am J Surg* 2011; 201(4):450-455.
- Bhojani FD, Fox A, Pitzul K, et al. Clinical and economic comparison of laparoscopic to open liver resections using a 2-to-1 matched pair analysis: an institutional experience. *J Am Coll Surg* 2012;214(2):184-195.
- Johnson LB, Graham JA, Weiner DA, Smirniotopoulos J. How does laparoscopic assisted hepatic resection compare with the conventional open surgical approach? *J Am Coll Surg* 2012;214(4):717-723.
- Koffron AJ, Auffenberg G, Kung R, et al. Evaluation of 300 minimally invasive liver resections at a single institution: less is more. *Ann Surg* 246(3):385-392.
- Koffron AJ, Kung RD, Auffenberg GB, et al. Laparoscopic liver surgery for everyone: the hybrid method. *Surg* 142(4):463-468.
- Lortat-Jacob JL, Robert HG, Henry C. Excision of the right lobe of the liver for a malignant secondary tumor. *Archives des maladies de l'appareil digestif et des maladies de la nutrition* 1952;41(6):662-667.
- Buell JF, Cherqui D, Geller DA, et al. The international position on laparoscopic liver surgery: the Louisville statement. *Ann Surg* 2008;250(5):825-830, 2009.

# A Comparison of Combined Laparoscopic Uterine Artery Ligation and Myomectomy vs Laparoscopic Myomectomy in Treatment of Symptomatic Myoma

Vaibhav A Dunghav

## ABSTRACT

Uterine leiomyomas are one of the most common benign smooth muscle tumors in women, with a prevalence of 20 to 40% in women over the age of 35 years. Although many women are asymptomatic, problems, such as bleeding, pelvic pain, and infertility may necessitate treatment. Laparoscopic myomectomy is one of the treatment options for myomas. The major concern of myomectomy either by open method or by laparoscopy is the bleeding encountered during the procedure. Most studies have aimed at ways of reducing blood loss during myomectomy. There are various ways in which bleeding during laparoscopic myomectomy can be reduced, the most reliable of which is ligation of the uterine vessels bilaterally. In this review, we propose to discuss the benefits and possible disadvantages of ligating the uterine arteries bilaterally before performing laparoscopic myomectomy.

**Keywords:** Fibroids, Laparoscopic myomectomy, Myomectomy, Uterine artery embolization, Uterine artery ligation, Uterine devascularization.

**How to cite this article:** Dunghav VA. A Comparison of Combined Laparoscopic Uterine Artery Ligation and Myomectomy vs Laparoscopic Myomectomy in Treatment of Symptomatic Myoma. *World J Lap Surg* 2015;8(2):52-56.

**Source of support:** Nil

**Conflict of interest:** None

## INTRODUCTION

Uterine myomas are the most common tumor of the female reproductive system among any age group.<sup>1,2</sup> The incidence of this form of tumor is reported to be between 20 and 40% among women 35 years of age and older.<sup>3</sup> Myomas can significantly decrease the quality of life for women as they can result in menorrhagia, dysmenorrhea, and pelvic pain. Large myomas can also stimulate urinary tract compression, causing increased urinary frequency and urgency.

Among nonsurgical interventions, hormone therapy with gonadotropin-releasing hormone (GnRH) agonists has been the treatment of choice, and may result in symptomatic improvement and reduction in the size of the myoma.<sup>1,4</sup> However, rapid regrowth of the myomas to their original size has been reported to cause the recurrence of symptoms within a few months after the discontinuation of hormone treatment.<sup>4</sup> Furthermore, GnRH agonists can obliterate the myoma myometrial interface and as a result enucleation of myomas becomes more difficult.<sup>5</sup> As a result, hormone therapy has been limited to premenopausal use only.

Among the available modalities for surgical treatment of myomas, hysterectomy is the most common. In the United States, an estimated 600,000 hysterectomies are performed each year, with symptomatic uterine myomas cited as the main cause for approximately 30% of all hysterectomies. For women who wish to retain their childbearing potential, abdominal myomectomy has been the alternative.<sup>6</sup>

Less invasive alternatives, namely, laparoscopic and hysteroscopic myomectomy procedures, have also been developed in recent years.<sup>7</sup> Unfortunately, of these two approaches, the risk of reported recurring myomas is far greater with abdominal myomectomies<sup>1,4</sup> because, in cases with numerous myomas, the surgeon often removes the large and easily visible myomas, unintentionally leaving the smaller or *in situ* ones behind.<sup>1,7,8</sup> Postoperative intact myomas within the uterus may account for a persistence of menorrhagia and a high rate of myoma recurrence.

There are also controversies regarding all types of surgical intervention. Many researchers have reported that myomectomies (abdominal or laparoscopic), especially in the case of multiple myomas, have resulted in excessive blood loss, prolonged operating time, postoperative complication, and a prolonged hospital stay.<sup>7</sup>

To address these complications, an alternative treatment, the laparoscopic bilateral coagulation of uterine vessels, was introduced by Liu in 2000.<sup>9</sup> Other studies reported successful outcomes in treating symptomatic myomas by uterine artery ligation that reduced the patient's symptoms by 60 to 80% and the size of myoma by 40 to 50%.<sup>10</sup>

Senior Resident

Department of Obstetrics and Gynecology, Dr DY Patil Medical College, Pimpri, Pune, Maharashtra, India

**Corresponding Author:** Vaibhav A Dunghav, Senior Resident Department of Obstetrics and Gynecology, Dr DY Patil Medical College, Pimpri, Pune, Maharashtra, India, Phone: 9158872885, e-mail: vaibhav.dunghav84@gmail.com

The exact mechanisms by which the uterine artery ligation causes the reduction in the size of myoma have not been established, yet cell apoptosis and necrosis have been noted as possible explanations.<sup>1</sup> Noting these reported benefits, laparoscopic ligation of the uterine vessels, which causes fewer complications than other procedures, may be a better alternative to hysterectomy, despite the higher technical skill required to perform this procedure.<sup>11</sup>

Many studies in past evaluated the effect of combined laparoscopic uterine artery ligation (LUAL) and myomectomy as a therapeutic method in decreasing operative morbidities, such as intraoperative hemorrhage, operation time, and postoperative fever.

Some of the studies also evaluated myoma recurrence and symptom alleviation associated with recurrence as well as the fertility outcomes for relevant participants.

## AIM

To determine the impact of uterine artery ligation in laparoscopic myomectomy, according to surgical results and clinical outcomes.

## MATERIALS AND METHODS

A review of literature was performed in September 2015 using search engines: Highwire Press, Pubmed and Google. The searches used the keyword 'laparoscopic myomectomy with uterine artery ligation'. No statistical analyses have been performed. Data extraction was directly by full text of the publications in the Journals. In most of the studies main outcome measured was operating time, blood loss, blood transfusion, febrile morbidity, symptoms improvement, recurrence rate, and pregnancy rate. There were several studies performed in past on this topic. And in most of the studies uterine artery ligated at it origin.

## RESULTS

A study by Saeed Alborzi et al of 152 women with symptomatic uterine myomas necessitating surgical intervention who wished to retain their uteri, 65 underwent laparoscopic uterine artery ligation and myomectomy (experimental group) and 87 received laparoscopic myomectomy only (control group). All the participants were recruited from women with symptomatic myomas during a 3-year period between 2003 and 2005. All the symptomatic myomas were diagnosed by transvaginal ultrasound or sonohysterography. All of the women wished to retain their uteri. In total, 152 women between the ages of 20 and 46 years, who could be followed up for 2 years, were selected. The women's symptoms included

menstruation problems, mostly menorrhagia and/or lower abdominal pain. None of the patients was pregnant at the time of the study nor had amenorrhea. The patients were divided into two groups. Group A (n = 65), the experimental group, consisted of patients who underwent both LUAL and myomectomy. Group B (n = 87), the control group, included patients who were treated with laparoscopic myomectomy alone. Both groups had similar overall general characteristics including age, mean average size of myomas, and the number of myomas.

For a period of 24 months, all of the patients were evaluated every 3 months to assess their symptoms and check for the recurrence of myomas by transvaginal ultrasound. Patients graded their subjective symptomatic changes in terms of pain and bleeding using one of two choices: completely resolved or unchanged. Menorrhagia improvement was evaluated by the pads used during menstruation, and dysmenorrhea improvement was evaluated by the amount of analgesics used.

The average operating time and blood loss were  $112 \pm 18$  minutes and  $173 \pm 91$  ml for the experimental group and  $95 \pm 14$  minutes and  $402 \pm 131$  ml for the control group, respectively (statistically significant). A total of 15 (17.2%) of the control group patients required a blood transfusion, but none of the experimental group patients required one. Febrile morbidity occurred in 18.5% of the experimental group and 20.7% of the control group. In the experimental group, the recurrence of myoma was 6.2 and 98.1% of the patients reported symptoms improvement; however, in the control group, these figures were 20.75 and 83.1%, respectively (statistically significant). The pregnancy rates were not statistically significantly different in the experimental group (35%) and the control group (35.7%).

A study by Chin-Jung Wang et al 20 consecutive women with symptomatic uterine fibroids desiring to preserve the uteri underwent laparoscopic surgery with ligation of the uterine arteries with ligating clips, followed by myomectomy and removal of the clips.

Laparoscopic uterine artery ligation with reversible ligating clips was successfully performed in all patients. The median main fibroid diameter and fibroid weight were 7.3 cm [interquartile range (IQR) 7.0–9.0] and 210 gm (IQR 150–295 gm), respectively. The median operating time was 120 minutes (IQR 100–148 minutes) and blood loss was 100.0 ml (IQR 56.3–137.5 ml). The median number of fibroids removed was one (IQR 1–4.3). The median postoperative hospital stay was 3 days (IQR 2–3 days) and no patient developed complications. Menstrual bleeding problems and bulk-related symptoms were controlled in 90.0 and 100% of women, respectively after 6 months of follow-up. One woman conceived spontaneously

4 months after surgery and delivered a baby girl at 38 weeks gestation via cesarean section.

Another study performed by Ji Hae Bae et al in 90 patients. Results show 51 patients (56.6%) underwent laparoscopic myomectomy with uterine artery ligation (group A), and 39 patients (43.3%) underwent laparoscopic myomectomy alone (group B). The mean operating time was  $100.0 \pm 33.8$  minutes in group A and  $90.0 \pm 37.1$  minutes in group B. Both groups were similar with respect to mean blood loss ( $72.3 \pm 109.0$  vs  $62.6 \pm 77.3$  ml). The myoma recurrence rate in group A was significantly less than in group B after a median follow-up period of 11.1 months (2 vs 13%).

A study by Z Holub et al assessed the effect of lateral uterine artery dissection (LUAD) on clinical outcomes in laparoscopic myomectomy (LM). Fifteen women with symptomatic fibroids (dominant fibroid size: 3–6 cm) were randomly allocated to laparoscopic myomectomy (group A) and 16 women to the combined operative procedures LM and LAUD (group B). They assessed the clinical outcomes: intraoperative and postoperative blood loss, operating time, hospital stay, hemoglobin fall, inflammatory response and tissue markers [C-reactive protein (CRP), creatinin kinase and white blood cells (WBC)]. The mean operating time was 69.5 minutes in group A and 76.5 minutes in the group B, and the mean length of hospital stay was 2.6 days vs 2.1 days, respectively ( $p > 0.05$ ). For the laparoscopic myomectomy and combined operative procedure, respectively, the intraoperative blood loss was 134 ml (10–400 ml) and 93.7 ml (10–200 ml) ( $p > 0.05$ ); the difference (92.4 vs 46 ml) in estimated postoperative blood loss was statistically significant ( $p < 0.05$ ), and the decline in the hemoglobin level was  $1.2 \text{ g/dl}^{-1}$  (group A) vs  $0.6 \text{ g/dl}^{-1}$  (group B) on the 3rd postoperative day ( $p < 0.05$ ). Group B demonstrated a less intense stress response in terms of CRP ( $p < 0.001$ ) and WBC ( $p < 0.01$ ). The LUAD had little impact on intraoperative blood loss. This may be due to the smaller fibroid size, but the statistical difference in hemoglobin fall on the 3rd postoperative day was significant. The dissection of the uterine artery in laparoscopic myomectomy is a feasible surgical procedure with a low rate of complication.

A study by Giuseppe Vercellino et al of 166 women with symptomatic uterine myomas necessitating surgical intervention who wished to retain their uteri, 80 underwent laparoscopic uterine artery clipping and myomectomy (experimental group) and 86 received laparoscopic myomectomy only (control group). Main outcome measures were operating time, number and weight of leiomyomas, blood loss, Doppler examination of the uterine arteries and complications of procedure.

In the experimental group, the median hemoglobin drop measured on day 3 postoperatively was 1.2 g/dl. In the control group, the mean hemoglobin drop measured on day 3 postoperatively was 1.45 g/dl. The time needed to put the clips in place (the time from the opening of the retroperitoneum and the positioning of the clips) varied between 6 and 40 minutes. No patient required blood transfusion. There were no conspicuous complications.

## DISCUSSION

Excision of fibroids from the uterine corpus, repair of the uterine incision, control of operative blood loss, and removal of large fibroids are major concerns during LM. Control of operative blood loss might be the most critical consideration. Most intraoperative conversions to laparotomy reported in the literature have been because of intraoperative bleeding.<sup>12</sup> Previous studies study also confirmed the most serious complication during LM for large fibroids is severe intraoperative hemorrhage and subsequent blood transfusion.<sup>13</sup> More women with symptomatic uterine fibroids request laparoscopic management with preservation of the uterus. As the size of fibroids increases, it is necessary to develop a management strategy to circumvent surgical problems related to large fibroids. Pretreatment with GnRH agonist can shrink the fibroids and theoretically simplify myomectomy. However, GnRH agonist therapy may alter the myoma-myometrium interface and induce the disappearance of small fibroids; therefore, it may increase the difficulty of fibroid enucleation and the incidence of recurrent fibroids.<sup>14–16</sup> In addition, GnRH agonist therapy provides only a slight benefit in reducing blood loss.<sup>17</sup> Therefore, it is suggested that pretreatment with GnRH agonist be used in selected LM cases.

Vasopressin is a posterior pituitary hormone with a strong vasoconstrictive effect on smooth muscle. Local administration of vasopressin to the uterus is helpful in controlling bleeding during myomectomy.<sup>18,19</sup> Possible drawbacks include bleeding from the needle puncture sites, which often persists throughout the procedure, requiring later electrosurgical coagulation, and delayed bleeding in the myometrium.<sup>20</sup> If unexpected bleeding occurs, the goal of controlling operative bleeding will not be achieved.

Placing a tourniquet around the lower uterus to stop the blood flow to the uterus can facilitate a myomectomy. It is, however, difficult to perform during a laparoscopy because there are no appropriate instruments. Modified procedures have been introduced for this purpose in laparoscopic surgery.<sup>7,21</sup> They can effectively reduce blood loss during LM and have the potential to prevent fibroid recurrence. Nevertheless, suture and hemoclip ligations

**Table 1:** Comparison of various studies in term of operative time and intraoperative blood loss

Study name	No. of participants			Operating time (min)		Outcome Intraoperative blood loss (ml)	
	Experimental group (E)	Control group (C)	Total	Experimental group (E)	Control group (C)	Experimental group (E)	Control group (C)
Saeed Alborzi et al	65	87	152	112 ± 18	95 ± 14	173 ± 91	402 ± 131
Chin-Jung Wang et al	20	—	20	120 (100–148)	—	100 (56.3-137.5)	—
Ji Hae Bae et al	51	39	90	100 ± 33.8	90 ± 37.1	72.3 ± 109	62.6 ± 77.3
Z Holub et al	15	16	31	76.5	69.6	93.7	134
Giuseppe Vercellino et al	80	86	166	—	—	1.2 g/dl	1.45 g/dl

E: Experimental group, C: Control group

are permanent methods and might not be suitable for women who want to retain their childbearing capacity. Hem-o-lok clips can stop uterine blood flow at the uterine artery level and reperfusion occurs after removal. With the aid of this instrument, blood loss can be controlled and childbearing preserved when performing a uterine depletion procedure followed by a myomectomy.

Criticisms of the transient blocking uterine perfusion procedure are that the average 2 hours occlusion time might induce irreversible damage in the uterine myometrium and cause embolic events and pulmonary emboli after release of the clips.

Traditional uterine tourniquets usually require only an hour.<sup>22</sup> A review of the literature on ischemic, necrotic twisted adnexa showed no reports of embolic phenomena after detorsion.<sup>23,24</sup> In addition, the uterus has a dual extrinsic blood supply. The primary supply is from the uterine arteries, and the secondary supply is from branches of the ovarian arteries. If the uterine arteries are occluded, the myometrium is supplied by the ovarian arteries through the communicating arteries. If the ovarian arteries remain intact during the operation, damage to the myometrium theoretically would not occur, regardless of the length of time the uterine arteries are occluded.

Blood loss in myomectomy mainly occurs during removal of fibroids and uterine repair. Therefore, it is necessary to quickly suture the wound to avoid a massive hemorrhage. It is not easy to perform a perfect uterine repair with minimal blood loss within a short time in laparoscopic surgery unless surgeons are proficient in laparoscopy. A uterine depletion procedure can provide a relatively bloodless situation and let the surgeon perform laparoscopic suturing with ease.

After reviewing literature on uterine artery ligation prior to laparoscopic myomectomy shows that it significantly reduces blood loss compared to laparoscopic myomectomy without uterine artery ligation group (Table 1).

All of the studies also show that it slightly increases in operative time without any increase in morbidity in experimental group (Table 1).

In experimental group there is decrease in incidence of recurrence rate of myoma and blood transfusion compared to control group.

## CONCLUSION

In conclusion, LM offers several benefits to the patient. It is still a challenging technical procedure and might be associated with high surgical morbidity and incidence of blood transfusion. Surgical strategies are needed to overcome these problems in LM.

Uterine artery ligation prior to myomectomy can control operative blood loss in LM and preserve the childbearing capacity of the patient. However, larger studies to investigate the feasibility and effectiveness of this procedure are crucial before definite conclusions can be drawn.

## REFERENCES

1. Liu WM, Wang PH, Chou CS, Tang WL, Wang IT, Tzeng CR. Efficacy of combined laparoscopic uterine artery occlusion and myomectomy via minilaparotomy in the treatment of recurrent uterine myomas. *Fertil Steril* 2007;87(2):356-361.
2. Kirsten H, Anton L, Nils EK, Hans JN, Anette BB, Olav I. Laparoscopic occlusion of uterine vessels for the treatment of symptomatic fibroids: initial experience and comparison to uterine artery embolization. *Am J Obstet Gynecol* 2004;190(1):37-43.
3. Park K, Kim J, Shin J, Kwon J, Koo J, Jeong K. Treatment outcome of uterine artery embolization and laparoscopic uterine artery ligation for uterine myoma. *Yonsei Med J* 2003;44(4):694-702.
4. Liu WM, Ng HT, Wu YC, Yen YK, Yuan CC. Laparoscopic bipolar coagulation of uterine vessels: a new method for treating symptomatic fibroids. *Fertil Steril* 2001;75(2):417-422.
5. Campo S, Garcea N. Laparoscopic myomectomy in premenopausal women with and without preoperative treatment using gonadotrophin-releasing hormone analogues. *Hum Reprod* 1999;14(1):44-48.
6. Pokras R, Hufnagel VG. Hysterectomies in the United States 1965–1984. *Vital health statistics, series 13.92*. Washington, DC: US Government Printing Office; March 1987.
7. Liu WM, Tzeng CR, Yi-Jen C, Wang PH. Combining the uterine depletion procedure and myomectomy may be useful

- for treating symptomatic fibroids. *Fertil Steril* 2004;82(1): 205-210.
8. Nezhat FR, Roenisch M, Nezhat CH, Seidman DS, Nezhat CR. Recurrence rate after laparoscopic myomectomy. *J Am Assoc Gynecol Laparosc* 1998;5(3):237-240.
  9. Liu WM. Laparoscopic bipolar coagulation of uterine vessels to treat symptomatic leiomyomas. *J Am Assoc Gynecol Laparosc* 2000;7(1):125-129.
  10. Ravina JH, Herberateau D, Ciraru-Vigieron N, Bouret JM, Houdart E, Aymard A. Arterial embolization to treat uterine myomata. *Lancet* 1995;346(8976):671-672.
  11. Holub Z, Eim J, Jabor A, Hendl A, Lukac J, Kliment L. Complications and myoma recurrence after laparoscopic uterine artery occlusion for symptomatic myomas. *J Obstet Gynecol Res* 2006;32(1):55-62.
  12. Dubuisson JB, Fauconnier A, Fourchette V, Babaki-Fard K, Coste J, Chapron C. Laparoscopic myomectomy: predicting the risk of conversion to an open procedure. *Hum Reprod* 2001;16(8):1726-1731.
  13. Wang CJ, Yuen LT, Lee CL, Kay N, Soong YK. Laparoscopic myomectomy for large uterine fibroids: a comparative study. *Surg Endosc* 2006;20(9):1427-1430.
  14. Fedele L, Vercellini P, Bianchi S, Brioschi D, Dorta M. Treatment with GnRH agonists before myomectomy and the risk of short-term myoma recurrence. *Br J Obstet Gynaecol* 1990;97(5):393-396.
  15. Lethaby A, Vollenhoven B, Sowter M. Efficacy of preoperative gonadotrophin hormone releasing analogues for women with uterine fibroids undergoing hysterectomy or myomectomy: a systematic review. *BJOG* 2002;109(10):1097-1098.
  16. Campo S, Garcea N. Laparoscopic myomectomy in premenopausal women with and without preoperative treatment using gonadotrophin-releasing hormone analogues. *Hum Reprod* 1999;14(1):44-48.
  17. Lethaby A, Vollenhoven B, Sowter M. Pre-operative GnRH analogue therapy before hysterectomy or myomectomy for uterine fibroids. *Cochrane Database Syst Rev* 2001:CD000547.
  18. Fletcher H, Frederick J, Hardie M, Simeon D. A randomized comparison of vasopressin and tourniquet as hemostatic agents during myomectomy. *Obstet Gynecol* 1996;87(6): 1014-1018.
  19. Kimura T, Kusui C, Matsumura Y, Ogita K, Isaka S, Nakajima A, Ohashi K, Koyama M, Azuma C, Murata Y. Effectiveness of hormonal tourniquet by vasopressin during myomectomy through vasopressin V1a receptor ubiquitously expressed in myometrium. *Gynecol Obstet Invest* 2002;54(3):125-131.
  20. Reich H. Laparoscopic myomectomy. *Obstet Gynecol Clin North Am* 1995;22(4):757-780.
  21. Sinha RY, Hegde A, Warty N, Jain R. Laparoscopic devascularization of uterine myomata followed by enucleation of the myomas by direct morcellation. *J Am Assoc Gynecol Laparosc* 2004;11(1):99-102.
  22. Rock JA, Jones HW III. *Te Linde's operative gynecology*. 9th ed. Philadelphia: JB Lippincott; 2003. p. 784.
  23. McGovern PG, Noah R, Koenigsberg R, Little AB. Adnexal torsion and pulmonary embolism: case report and review of literature. *Obstet Gynecol Surv* 1999;54(9):601-608.
  24. Oelsner G, Cohen SB, Soriano D, Admon D, Mashiach S, Carp H. Minimal surgery for the twisted ischaemic adnexa can preserve ovarian function. *Hum Reprod* 2003;18(12):2599-2602.



# The Future of Suprapubic Single-incision Laparoscopic Appendectomy

<sup>1</sup>Khaled Al-Yaqout, <sup>2</sup>Abdulaziz Alghurair, <sup>3</sup>Hussain Al-Tarrah

## ABSTRACT

**Background:** Suprapubic single-incision laparoscopic appendectomy (SSILA) has recently been studied by different authors, the targeted benefits were better cosmesis, less infection and possibly less hernia formation.

**Aim:** To evaluate the feasibility and benefits of SSILA by reviewing the most recent data published to date, and identifying the pros and cons of its use against an umbilical incision.

**Materials and methods:** A systematic electronic search based on preferred reporting items for systematic reviews and meta-analyses (PRISMA) statement was conducted, articles from 2010 to 2015 were reviewed. Only Adult population was included in the study. Pre-, intra- and postoperative variables were included in our study, such as operative duration, wound infection, cosmetic outcome and pain.

**Results:** Four studies were included and round up a total of 129 patients. Incision size varied from 1.5 to 2.5 cm, procedure was completed in all studied candidates, mean operative time was 52.9 minutes, no intraoperative complications were recorded, wound infection occurred in 0.015% of cases, mean hospital stay 1 to 4.7 days, pain and cosmetic outcome were difficult to interpret due to the way, their evaluation was conducted. Suprapubic single-incision laparoscopic appendectomy appears to give a better operative view, follow-up duration 1 to 80 weeks. Most studies suffered from bias in all aspects.

**Conclusion:** Finding a different access site in acute appendicitis may decrease the rate of port-site complications, and hence the morbidity associated with it. The suprapubic incision is an appealing alternative, with lack of strong evidence to support it. The available evidence supports its use, but randomized controlled trials have to be conducted to determine its fait.

**Keywords:** Appendectomy, Laparoscopic, Single port, Suprapubic.

**How to cite this article:** Al-Yaqout K, Alghurair A, Al-Tarrah H. The Future of Suprapubic Single-incision Laparoscopic Appendectomy. *World J Lap Surg* 2015;8(2):57-61.

**Source of support:** Nil

**Conflict of interest:** None

<sup>1-3</sup>Registrar

<sup>1</sup>Department of General Surgery, Mubarak Al-Kabeer Hospital, Kuwait

<sup>2</sup>Department of General Surgery, Al-Adan Hospital, Kuwait

<sup>3</sup>Department of General Surgery, Amiri Hospital, Kuwait

**Corresponding Author:** Khaled Al-Yaqout, Registrar Department of General Surgery, Mubarak Al-Kabeer Hospital Kuwait, Phone: +96597777609, e-mail: k.alyaqout@gmail.com

## INTRODUCTION

From an era where open appendectomy was the gold standard management of acute appendicitis (AA), emerged the three-port laparoscopic appendectomy (TPLA) showing more promising results in regards to postoperative pain, earlier return to work and cosmesis, and eventually proving to be a better predecessor. Surgeons further challenged the three-port ideation with single-incision laparoscopic surgery (SILS), aiming for even better cosmesis, and less postoperative pain. Single-incision laparoscopic surgery was questioned by being more challenging, technically more difficult and can be associated with more complications.<sup>1</sup> A meta-analysis of eight randomized controlled trials (RCTs), which included 1234 patients, one compared TPLA to single-incision laparoscopic appendectomy (SILA) for the management AA. It showed similar outcomes in regards to both surgical and medical complications, similar conversion rate, postoperative ileus, wound infection, re-operation rates, postoperative pain, hospital duration, and time to initiate first meal. Although SILA seems to be superior in regards to return to normal activity, and resumption of normal diet. It still stands behind in regards to operative time by approximately 5 minutes.<sup>2</sup> Starvros et al concluded that the increased risk of hernia formation was not supported by any clinical evidence in their meta-analysis, but the follow-up duration was reported to be short.<sup>3</sup> Many authors concluded that the umbilicus is the most common site for port-site complications, it carries a greater risk of port-site infection (PSI). This conclusions were evident in studies investigating SILS and conventional laparoscopy, done for various abdominal procedures.<sup>4-6</sup> Not only the umbilicus flora augments this but also the fact that retrieving the appendix through the incision will further increase such risk, and was linked to an increased incidence of hernia formation at those sites.<sup>7</sup> The rationale of this review is to evaluate the use of a suprapubic site of entry in SILA. Our objective is to target adults presenting with AA. We will evaluate it using the most recent evidence available.

## MATERIALS AND METHODS

### Literature Search

Our review followed the PRISMA statement.<sup>8</sup> We conducted a systematic electronic search using the following

keywords in every possible combination 'wound' 'laparoscopic' 'single' 'port' 'access' 'complications' 'infection' 'SILS' 'LESS' 'incision' 'appendectomy' 'site' 'suprapubic' 'SPL' 'single port appendectomy (SPA)' 'one port umbilical surgery (OPUS)' 'natural orifice transumbilical surgery (NOTUS)' 'SILA'. Search engines used: Medical literature analysis and retrieval system online (MEDLINE), Excerpta medica dataBASE (EMBASE), chochrane library. Relevant articles in the studies collected were also evaluated. Last search was done on 24/8/2015.

### Inclusion Criteria

Studies focusing on port-site complication, specially those comparing rate of infection at different incision sites. In addition, we included papers evaluating the applicability of SILA. The search results were limited to systematic reviews, meta-analysis and randomized controlled trials (RCT), once not available the best available evidence was included. Search results were filtered initially by screening the article titles, once approved by the two authors abstracts were further screened, at this stage the full articles were retrieved and decided to be included or not, if at any stage there was a disagreement on the inclusion or exclusion the third author acted as a referee.

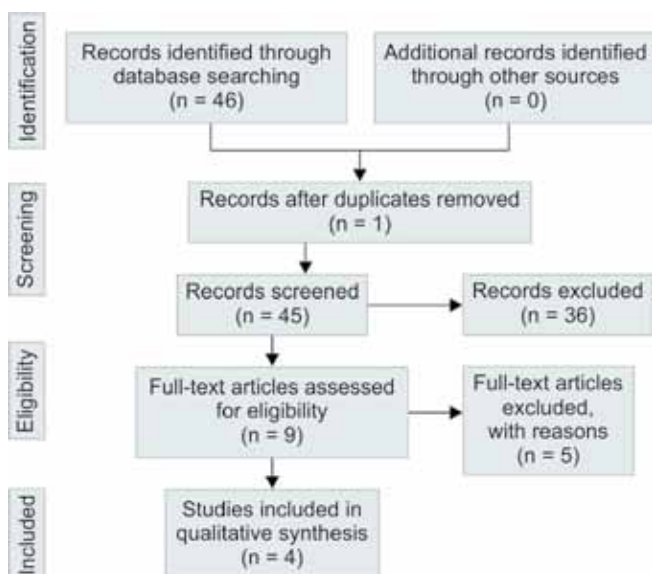
### Exclusion Criteria

Studies conducted on pediatrics population, obstetric and gynecology procedure, urological procedures, cases of malignancy and robotic surgery procedures. One study was excluded due to small sample size.

### Funding

There was no funding for this review, all articles were obtained through individual university access.

## RESULTS



A systematic research revealed 46 articles, the search was restricted to adults (age  $\geq 19$  years), and studies conducted in the past 5 years only. We have initially restricted the search to RCTs but were not able to obtain any results matching our inclusion criteria, hence the highest level of evidence available was used. From 46 articles, 12 were filtered by title. Eventually, nine articles were reviewed after exclusion by abstracts. Out of nine full texts only four studies were included in our review. One study was excluded due to small sample size.<sup>9</sup> Exclusion was based nine on our inclusion and exclusion criteria. The articles characteristics are presented in Table 1 and patient characteristics and outcomes in Table 2.

### Type of Studies and Bias

All four studies were conducted on adults diagnosed with AA, none of them was an RCT. Only one study included those with complicated AA.<sup>7</sup> Pooled sample size for all studies was 129 patients. The studies were published between 2011 and 2015. The article type varied, Vidal et al conducted a prospective study,<sup>10</sup> Ze Zhang et al got their results through a propensity matched analysis,<sup>7</sup> a retrospective study was conducted by Wang Y et al,<sup>11</sup> and a case series was presented by Alvarez et al.<sup>12</sup>

The sample size ranged from 15 to 54 patients. All studies suffered from selection bias. There was no random sequence in selecting the candidates, except for Ze Zhang et al<sup>7</sup> who were trying to eliminate bias by using propensity matched analysis. No evidence of concealment was present when selecting the study candidates in all papers, so, in conclusion selection bias is profound along most of the articles. Both participants and candidates were aware of the type of procedure being performed. Blinding was not evident even in the assessment of variable outcomes, such as postoperative complications and wound cosmesis. Hence, performance and detection bias is also profound along all studies. All papers suffered attrition bias, by excluding the complicated appendixes in three articles,<sup>10-12</sup> or by excluding those who did not have a matching population without mentioning the outcome of them.<sup>7</sup>

### Surgical Technical Aspects

All procedures were performed under GA where there was no contraindication to laparoscopic surgery. All surgeries were performed by surgeons experienced in laparoscopic surgery. Wound size was 1.5 cm on two studies,<sup>11,12</sup> 2 cm<sup>7</sup> and 2.5 cm.<sup>10</sup> Two authors used a self made port.<sup>7,11</sup> One conducted the study using SILS port,<sup>10</sup> and one using R-port.<sup>12</sup> The operative time range was [(35–76.36 minutes) (mean = 52.91 minutes)]. None of the studies reported any intraoperative complication, use

Table 1

Study	Year published	Sample size (n = patients)	Incision type and length (port)	Type of study	Surgeon experience	Instrument used to secure/resect appendix and mesoappendix	Follow-up
Alvarez et al <sup>12</sup>	2012	15	1.5 cm transverse/(R Port)	Series of 15 cases	N/A	Appendix by stable/mesoappendix by clips and cautery	N/A
Vidal et al <sup>10</sup>	2011	20	2.5 cm transverse/SILS port	Prospective study	Same experienced laparoscopic surgeons	Appendix by endo gia/mesoappendix by clips	7 days
Wang et al <sup>11</sup>	2015	42	1.5 cm transverse/self made port	Retrospective analysis	Two surgeon team experienced in laparoscopy	Nonabsorbable loop, meso with ultrasonic scalpel	1 month
Ze Zhang et al <sup>7</sup>	2015	54	2 cm transverse/self made port	Propensity matched analysis	Two surgeon team experienced in laparoscopy	Nonabsorbable loop, meso with ultrasonic scalpel	12 to 20 months

Table 2

Study	Mean operative time in minutes (confidence interval)	Wound complications (n = incidence)	Intraoperative complication/conversion/extra-port	Pain (n = number of patients)	Drain placement	Cosmesis	Hospital stay in days
Ze Zhang	58.91 (± 17.45)	wound infection (n = 1)	0/0/0	Required additional analgesia (n = 13)	5	Psaq satisfaction with appearance 8 (8–16)	4.7 ± 1.6
Wang Y	58 (± 11)	wound infection (n = 1)	0/0/0	Required additional analgesia (n = 8)	4	N/A	3 ± 1
Vidal	40 (± 7)	nell	0/0/0	Vas median 2 (1–4)	4	N/A	2 ± 0.5
Alvarez	35 (15–60)	nell	0/0/0	Required additional analgesia (n = 1)	13	No proper assessment of cosmetic outcome	Mean < 24/ 22 (18–31) hours

of extra-ports, conversion to conventional or open procedure. Drain was used in 4.96% of cases (n = 26). Most of the studies has concluded that a suprapubic approach offered a better visualization of the appendix with a better viewing angle.

### Postoperative Course, Pain Assessment

Mean hospital stay averaged from 1 to 4.7 days. Pain assessment was subjective in three out of four studies.<sup>7,11,12</sup> One study used visual analog scale (VAS) with a pain median value of 2 (1–4).<sup>10</sup>

### Postoperative Complications

Two out of 129 were complicated with wound infection, no other postoperative complications were mentioned otherwise. It appears that the rate of wound infection is lower in a suprapubic incision in comparison to an umbilical incision in one study (2.3 vs 8.7%)<sup>11</sup> and (1.8% vs 3.3–8.2%) in another.<sup>7</sup>

### Cosmetic Outcome

Only one study has used patient scar assessment questionnaire (PSAQ) median = 8 (8–16),<sup>7</sup> the rest based their assessment on clinical basis.

### Follow-up

Follow-up ranged from 1 to 80 weeks.

### DISCUSSION

Suprapubic incision is an appealing site for performing SILS in AA. We will discuss the feasibility and possibility of such an approach on the bases of comparing it to the conventional umbilical incision. Our study was based on the hypothesis that by choosing a different entry site for AA in SILS, the rate of port-site complications will reduce. The umbilicus is the standard site of entry to date, but, port-site herniation, infection and pain are among the commonly seen complications with such an incision, not only in SILS but also in conventional laparoscopic surgery.<sup>4,6,7,11</sup> A systemic review conducted by M Owens included 25 review original articles, highlighted port-site hernial complications, based on his data out of 7,802 patients undergoing laparoscopic cholecystectomy (LC), the incidence of hernia was (0.12–1.8% mean 0.69) where at least 68.25% were at the umbilicus. He also mentioned that wound infection is a key player in predisposing late port-site herniation, hence the increased incidence of infection at the umbilicus may explain the increased incidence of hernia at this site.<sup>4</sup> This approves a previously conducted systematic review included 5984 patients

and showed five reports proposing umbilical herniation as secondary to infection at this site.<sup>13</sup> In the other hand, varying depth the umbilicus is thought to result in a higher local wound complication rate.<sup>14</sup> A descriptive study published in 2013, it included 570 patients. They analyzed port-site complications, and concluded that the umbilical port is the most common site (47% of port-site complications). The complications ranged from PSI, bleeding, herniation, omental entrapment and port-site metastasis.<sup>15</sup> S Ghata et al in a prospective study on 100 patients assessing wound complication, they have found that most PSI is at the umbilicus, along with subcutaneous emphysema and port-site hernia.<sup>6</sup> One hundred and fifty patients were studied in an randomized clinical trial conducted by P Bucher et al, it showed similar rates of seroma and hematoma in both umbilical and other ports (3%), in conventional laparoscopic cholecystectomy, he has also shown a 0% hernial rate, yet his study lacks long-term follow-up in regards to hernia, showed no blinding or concealment and suffers selection bias in our opinion. Although no infection was reported one can predict that hematoma/seroma can predispose to wound infection.<sup>16</sup> No level one evidence is present to support a suprapubic SILS. This paper aims not to establish SILS as a gold standard management of AA, but to describe an alternative to the commonly used access site, in order to decrease the complication rate associated with it as described previously, and hence to get more acceptance, to motivate the conduction of RCTs regarding this topic. Suprapubic single-incision laparoscopic appendectomy (SSILA) is relatively new, it was first proposed in 2005. Hence, we would have come to a better conclusion if sufficient sample sizes were available to achieve power. Another issue is the lack of RCTs, but we are looking forward to see the results of Ze Zhang et al upcoming RCT, which will aid in determining the fate of SSILA. With the available evidence we can conclude that, using the commercially available SILS ports, the operative time may be shorter. The mean operative time presented in our paper reflects mostly the work presented by one institute,<sup>7,11</sup> they used a self made port that might have resulted in longer operative time, not only this but also the use of conventional instruments in their approach would alter the ergonomics and triangulation in the field and hence result in operative delay. The safety of SSILA might be questioned by some, but the 0% rate of intraoperative complications proves no such claim to date. Cosmesis is not compromised by the use of extra-ports or conversion to conventional nor open. All four authors claimed no use of extra-ports, this can be due to many factors. One is that the viewing angle in such an approach can ease the dissection and retrieval of the appendix, another

factor is that the surgeons are familiar with SSILA, a third possibility is that many of these studies has excluded complicated cases, except for Ze Zhange et al,<sup>7</sup> but he also achieved equal results even after including the complicated cases. Drain placement is subjected to the surgeons preference, and, the intra-abdominal findings. The high percentage of drains used is due to a liberal use of drains by Alvarez in his study. A total of 13 drains were placed in 15 individuals in his study. We could not conclude if pain in SSILA is better than an umbilical approach, this is mainly due to the lack of evidence on this topic. Only one author used VAS and the sample was too small to come up with a conclusion. Authors claim that cosmetic outcome is better. Hypothetically, we can assume that the presence of the incision in the pubic area will be invisible, even if complications, such as infection arises in such an area, the concern regarding it final outcome will not be as if it was at the umbilicus, but as from the evidence available, one author has presented an objective cosmetic assessment.<sup>7</sup> Hence, we can only base our conclusion hypothetically supported by the subjective opinion of the SSILA authors that we can achieve a better cosmetic outcome with such an approach. The follow-up duration was too short in some studies to evaluate complications, such as herniation, we are hoping that the upcoming RCTs will give a better answer, yet assuming that the infection rate is lower we can hypothesis that we will have a lower rate of hernia formation.

## CONCLUSION

Finding a different access site in AA might decrease the rate of port-site complications, and hence the morbidity associated with it, the suprapubic incision is an appealing alternative, with lack of strong evidence to support it. The available evidence supports its use, but more RCTs have to be conducted to give a better decision on such an approach.

## REFERENCES

1. Vettoretto N, Cirocchi R, Randolph J, Morino M. Acute appendicitis can be treated with single-incision laparoscopy: a systematic review of randomized controlled trials colorectal disease. *Wiley-Blackwell* 2015;17(4):281-289.
2. Xu AM, Huang L, Li TJ. Single-incision versus three-port laparoscopic appendectomy for acute appendicitis: systematic review and meta-analysis of randomized controlled trials. *Surgical Endoscopy*. Springer Science + Business Media, 2014;29(4):822-843.
3. Antoniou SA, Koch OO, Antoniou GA, Lasithiotakis K, Chalkiadakis GE, Pointner R, Grandrath FA. Meta-analysis of randomized trials on single-incision laparoscopic versus conventional laparoscopic appendectomy. *Am J Surg Elsevier BV* 2014;207(4):613-622.

4. Owens M, Barry M, Janjua AZ, Winter DC. A systematic review of laparoscopic port site hernias in gastrointestinal surgery. *The Surgeon*. Elsevier BV 2011;9(4):218-224.
5. Bunting DM. Port-site hernia following laparoscopic cholecystectomy. *J Society of Laparoendos Surg* 2010;14(4):490-497.
6. Ghata S, Dugar D, Mishra RK, Khetri R, Houghton T. Study of port site complications in laparoscopic surgeries. *J Pharmace Biomed Sci* 2015;5(2):134-138.
7. Zhang Z, Wang Y, Liu R, Zhao L, Liu H, Zhang J, Li G. Suprapubic single incision versus conventional laparoscopic appendectomy. *J Surg Res Elsevier BV* 2015.
8. Moher D, Liberati A, Tetzlaff J, Altman DG. Preferred reporting items for systematic reviews and meta-analyses: the PRISMA statement, *BMJ*. *BMJ* 2009 Jul 21;339(1):b2535-b2535.
9. Yu J, Wang Y, Hu Y, Cheng X, Zhen L Li, G. Single-incision laparoscopic appendectomy performed above the pubic symphysis—a new scarless approach. *Minimally Invasive Therapy and Allied Technologies*. Informa UK 2011;20(1):18-21.
10. Vidal Ó, Ginestà C, Valentini M, Martí J, Benarroch G, García-Valdecasas JC. Suprapubic single-incision laparoscopic appendectomy: a nonvisible-scar surgical option. *Surgical Endoscopy*. Springer Science + Business Media 2010;25(4):1019-1023.
11. Wang Y, Xiong W, Lan X, Zhang J, Chen T, Liu H, Li G. Suprapubic single incision laparoscopic appendectomy. *J Surg Res* 2015;193(2):577-582.
12. Alvarez JA G, Gascon Hove M, Elosua TG. Suprapubic appendectomy: a different single-incision approach, surgical innovation. *SAGE Publications* 2012;21(1):39-42.
13. Bunting DM. Port-site hernia following laparoscopic cholecystectomy. *J Soc Laparoendos Surg* 2010;14(4):490-497.
14. Weiss HG, Brunner W, Biebl MO, Schirnhofner J, Pimpl K, Mittermair C, Obrist C, Brunner E, Hell T. Wound complications in 1145 consecutive transumbilical single-incision laparoscopic procedures. *Annals of Surgery*. Ovid Technologies (Wolters Kluwer Health), 2014;259(1):89-95.
15. Augustine A, Pai M, Shibumon M, Karthik S. Analysis of laparoscopic port site complications: a descriptive study. *J Minimal Access Surg Medknow* 2013;9(2):59.
16. Bucher P, Pugin F, Buchs NC, Ostermann S, Morel P. Randomized clinical trial of laparoendoscopic single-site versus conventional laparoscopic cholecystectomy. *Br J Surg Wiley-Blackwell* 2011;98(12):1695-1702.

## RETROSPECTIVE STUDY

# A Comparative Study of Single Incision vs Conventional Four Incision Laparoscopic Cholecystectomy: A Single Center Experience

<sup>1</sup>Njem Josiah Miner, <sup>2</sup>RK Mishra

## ABSTRACT

Laparoscopic cholecystectomy has traditionally been performed using multiple small incisions. Single incision laparoscopic cholecystectomy (SILC) has emerged as an alternative technique to improve cosmesis and minimize complications associated with multiple incisions. This study compared SILC with conventional four incision laparoscopic cholecystectomy.

**Materials and methods:** One hundred and twenty-one patients had laparoscopic cholecystectomy at the institute of minimal access, metabolic and bariatric surgery, Sir Ganga Ram Hospital, New Delhi, between January 2013 and October 2014. A total of 61 (50.4%) had conventional four port laparoscopic cholecystectomy (4PLC), while 60 (49.6%) had SILC. Indications for the operation were similar for the two groups. Excluded were patients who were operated for malignant gallbladder disease, patients with Mirizzi syndrome, patients with gallbladder perforation and patients who were in American Society of Anesthesiologists (ASA) 1V and V.

**Primary end points:** Analgesic requirements, Complications and hospital visits, Length of hospital stay.

**Results:** The average length of hospital stay including in-patient and out-patient surgeries was  $23.93 \pm 9.8$ , range 4 to 48 hours for those who had SILC and  $30.07 \pm 16$ , range 8 to 72 hours for patients who underwent 4PLC. Patients in both groups had either paracetamol or a nonsteroidal anti-inflammatory drug (NSAID) as postoperative analgesic. Only one (1.7%) patient who had SILC required an NSAID for postoperative analgesia, while 59 (98.3%) had postoperative pain relieve using only paracetamol. Four (6.6%) of patients who had 4PLC required an NSAID for postoperative analgesia, while 57 (93.4%) had only paracetamol for postoperative analgesia.

**Conclusion:** Single incision laparoscopic cholecystectomy appears to offer prospects for shorter hospital stay and early return to work compared to conventional 4PCL. Patients undergoing either SILC or 4PLC appear to have similar analgesic requirement. Extrapolating this to pain difference between the two surgical techniques, however, requires caution. Single incision laparoscopic cholecystectomy

as a surgical technique is, however, feasible and promising for treatment of symptomatic cholelithiasis.

**Keywords:** Analgesic, Four incision laparoscopic cholecystectomy, Hospital stay, Single incision laparoscopic cholecystectomy.

**How to cite this article:** Miner NJ, Mishra RK. A Comparative Study of Single Incision vs Conventional Four Incision Laparoscopic Cholecystectomy: A Single Center Experience. *World J Lap Surg* 2015;8(2):62-67.

**Source of support:** Nil

**Conflict of interest:** None

## INTRODUCTION

Laparoscopic cholecystectomy (LC) has become one of the most effective procedures for the treatment of gallbladder pathology.<sup>1</sup> This technique has induced tremendous revolution in the surgery of biliary system, mainly due to improved results compared to the open technique and its cosmetic advantages has further endeared in the heart of surgeons.<sup>1,2</sup> Since, the first LC by Muhe et al in 1985, conventional laparoscopic cholecystectomy (CLC) has become the gold standard for treating gallbladder disease.<sup>1,3,4,9,12,13</sup> Conventional laparoscopic cholecystectomy is a safe established procedure and traditionally it is performed through three to four small incisions.<sup>4,5,9,11</sup> It is the commonest operation performed laparoscopically worldwide.<sup>14</sup>

A trend toward even more minimally invasive approaches has, however, led to techniques of single incision and natural orifices transluminal endoscopic surgery (NOTES).<sup>1,2,4,4,9</sup> The first published report of single incision laparoscopic cholecystectomy (SILC) was by Navarra in 1997 and since that time the idea of 'scarless' surgery has gained increasing popularity among patients as well as surgeons.<sup>1,4,6</sup> Single incision laparoscopic cholecystectomy is indeed a rapidly evolving technique that is complimenting CLC in selected fields and patients.<sup>4</sup> It is now considered by many as a bridge between traditional cholecystectomy and NOTES.<sup>2,4,5</sup> Single incision laparoscopic cholecystectomy utilizes three ports through a single skin incision at the umbilicus and is being considered as a 'no scar' surgery because the incision is placed within the umbilical scar.<sup>4,7</sup> It has gained increasing

<sup>1</sup>Senior Registrar, <sup>2</sup>Director, Professor and Senior Consultant

<sup>1</sup>Department of Surgery, Cardiothoracic Surgery Unit, JOS University Teaching Hospital, JOS, Nigeria

<sup>2</sup>Department of Minimal Access Surgery, World Laparoscopy Hospital, Gurgaon, Haryana, India

**Corresponding Author:** Njem Josiah Miner, Senior Registrar Department of Surgery, Cardiothoracic Unit, JOS University Teaching, PMB 2076, JOS, Nigeria, e-mail: njemjoe@gmail.com

attention due to the potential to maximize the benefits of laparoscopic surgery.<sup>8,11</sup> The reported advantages of SILC include less postoperative pain and minimum or no narcotic analgesic requirements, shorter hospital stay, quicker return to work and better cosmesis as well as low complication rate and cost.<sup>1,4,9,11</sup>

Single incision laparoscopic cholecystectomy is feasible and promising method of cholecystectomy and it is possible to do this procedure without the use of special equipment.<sup>1,4,9</sup> It is a safe and effective alternative to four incision laparoscopic cholecystectomy that provides surgeons with an alternative minimal access surgical option and the ability to hide the surgical incision within the umbilicus.<sup>4,9,10</sup> It is predicted by some reports that it may become a standard approach to LC.<sup>1</sup> This procedure is, however, not without drawbacks. Among the suggested disadvantages are prolonged operative time, high cost of special instruments, increased risk of operative complications and ergonomically disadvantageous to the surgeon.<sup>1</sup>

The main aim of this study is to compare SILC with conventional four incision laparoscopic cholecystectomy in patients who had cholecystectomy for gallbladder disease. The specific objectives include finding out the advantages of SILC over CLC, to evaluate any operative challenges inherent in SILC as well as unveil a single center experience with both operative approaches.

## MATERIALS AND METHODS

After institutional clearance, clinical data of all patients who had LC at the institute of minimal access, metabolic and bariatric surgery Sir Ganga Ram Hospital between January 2013 and October 2014 was retrieved from the hospital database. Patients were evaluated with respect to demographic characteristics, surgical complications, analgesic requirements, length of hospital stay, conversion from single incision to four incision laparoscopic cholecystectomy or to open cholecystectomy.

The analysis included profiling of patients on different demographic and clinical parameters. Quantitative data is presented in terms of means and standard deviation. Student t-test was used for comparison of individual quantitative parameters. Cross tables were generated and Chi-square test was used for testing of associations.  $p$ -value  $< 0.05$  is considered statistically significant. Software Package for the Social Sciences (SPSS) software was used for analysis.

## OPERATIVE TECHNIQUES

All operations were performed under general anesthesia and orotracheal intubation. Patients were placed

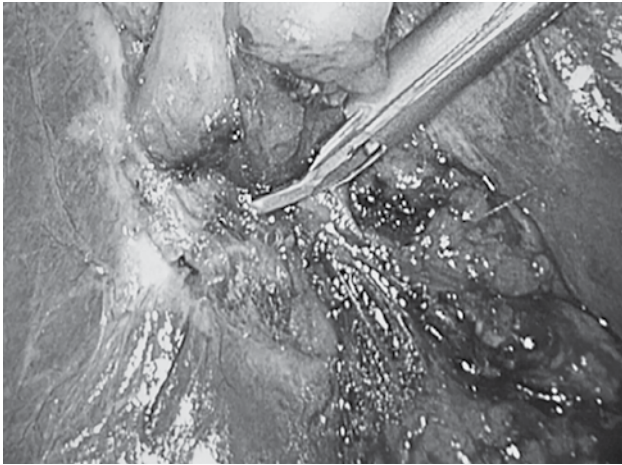
in reverse Trendelenburg position ( $30^\circ$ ) with table tilted right up to displace the intra-abdominal organs away from the gallbladder. A nasogastric tube was placed for decompression. For SILC, after pneumoperitoneum using the standard Veress needle technique, a 2 cm trans-umbilical incision was made. A 10 mm camera port was inserted and diagnostic laparoscopy performed. Two other 5 mm ports were placed through the umbilical incision (Figs 1 and 2). A striker mini alligator was passed through the right hypochondrium to provide cephalad retraction of the gallbladder fundus. A hunter's grasper was used to grasp the infundibulum, providing lateral traction. The gallbladder was dissected laterally with a combination of harmonic scalpel and blunt suction tip to create a large lateral window. The hilum was dissected and the cystic duct and cystic artery are identified. The posterior branch of the cystic artery which is present almost all the time is coagulated with harmonic. The cystic artery and cystic duct are clipped and divided (Figs 3 to 5). The gallbladder is dissected from the liver bed along the cystic plate. The gallbladder bed was inspected

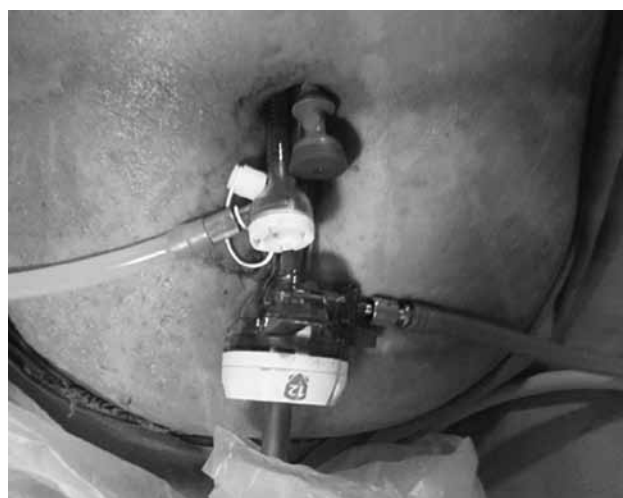

Fig. 1: Port position for SILC

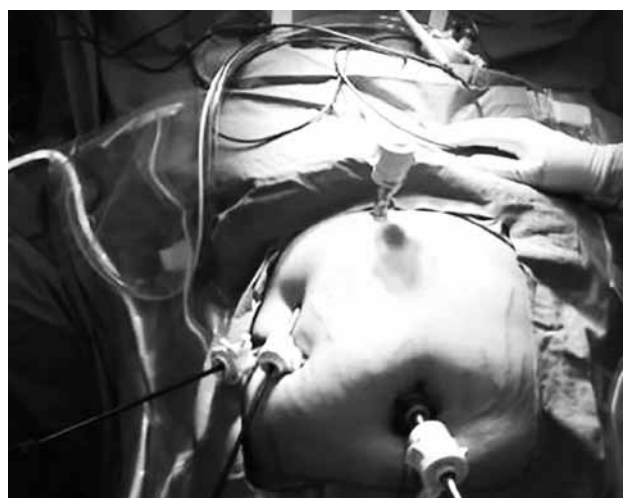

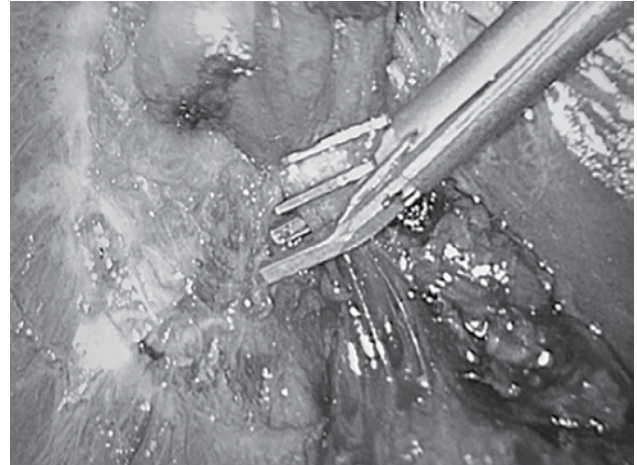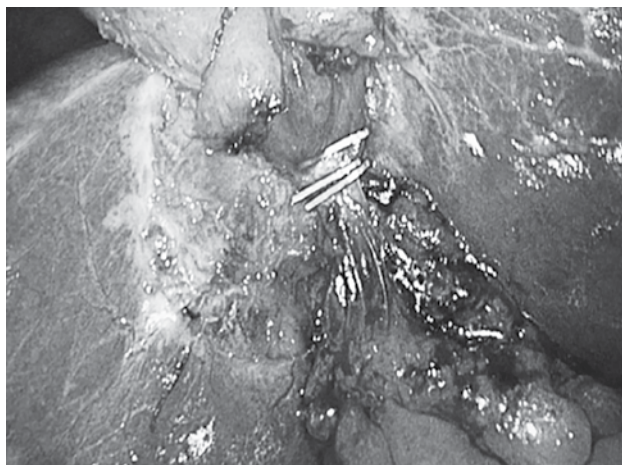
Fig. 2: Port position for 4PLC



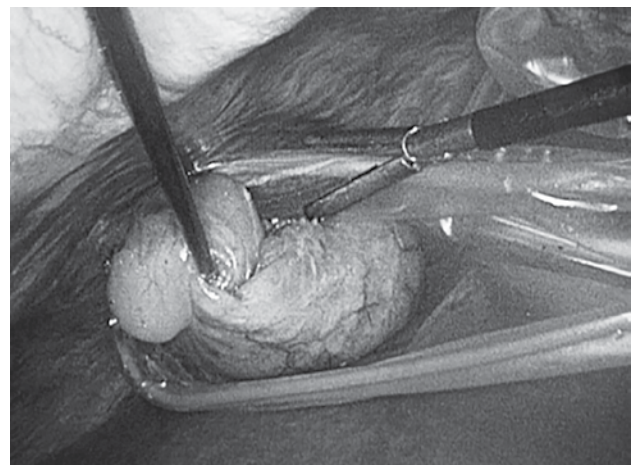
**Fig. 3:** Applying a clip



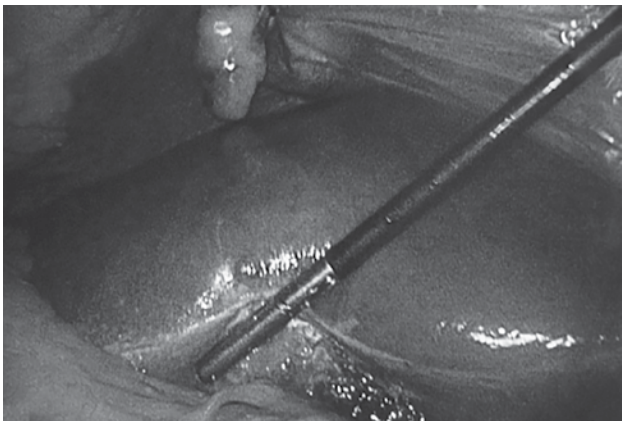
**Fig. 4:** Clip application



**Fig. 5:** Clips on cystic duct



**Fig. 6:** Specimen in endo bag



**Fig. 7:** Inspecting the gallbladder bed

before final separation of the gallbladder from its bed to ensure no bleeding or leaks were left unattended (Fig. 6). The specimen was delivered by a retrieval bag through the 10 mm port after changing the camera to a 5 mm 30° camera for retrieval under vision (Fig. 7). The umbilical incision was closed with vicryl 2/0 suture.

For the four incision laparoscopic cholecystectomy, after pneumoperitoneum using the standard Veress needle technique. A 10 mm 30° umbilical port was placed and 360° diagnostic scan of the entire abdomen was

performed to exclude injury or bleeding incurred during pneumoperitoneum, first port placement and to identify any unsuspecting gross pathology. Following this, 10 or 5 mm epigastric, 5 mm right hypochondriac working ports as well as 5 mm assisting port just below right hypochondriac port were subsequently placed (Fig. 2). A hunter's grasper passed through the assisting port was used for cephalad retraction of the gallbladder fundus. Another grasper through the right hypochondriac port is used to provide lateral retraction of the infundibulum of the gallbladder. The gallbladder was dissected laterally with a combination of harmonic scalpel and bunt suction tip as describe earlier. The hilum was dissected and the cystic duct and cystic artery were identified. The posterior branch of the cystic artery which is always present was coagulated with harmonic. The cystic duct and artery are clipped and divided. The gallbladder is dissected from the liver bed along the cystic plate. Inspection of the bed was done before the last bit of the gallbladder was completely separated, to ensure adequate hemostasis. The specimen was delivered in a retrieval bag through the 10 mm port under vision. The 10 mm incision was closed using vicryl 2/0 suture.



## RESULTS

Of the 150 patients who had LC at the institute of minimal access, metabolic and bariatric surgery, Sir Ganga Ram Hospital, New Delhi, 61 (50.4%) had conventional four port laparoscopic cholecystectomy (4PLC), while 60 (49.6%) had SILC (Table 1). The average age of the

Table 1: Demographics, symptomatology and diagnosis

Study parameters	Number (n = 121)	%
<b>Gender</b>		
Male	57	47.1
Female	64	52.9
<b>Complications</b>		
Pain	120	99.2
No pain	1	0.8
<b>Examination</b>		
JAU	1	0.8
TEN	40	33.1
No complication	80	66.1
<b>USS</b>		
CHOLECY	1	0.8
CHOLELI	3	2.5
MSTONE	1	0.8
STONE	36	29.8
STONES	74	61.2
NONE	6	5.0
<b>Diagnosis</b>		
CHOLECYS	6	5.0
CHOLELIT	113	93.4
CHOLIELI	1	0.8
NONE	1	0.8
<b>Anesthesia</b>		
GA	118	97.5
NO GA	3	2.5
<b>Findings</b>		
MSTONES	1	0.8
PUS/STN	1	0.8
STONE	33	27.3
STONES	78	64.5
NONE	8	6.6
<b>Convert</b>		
YES	1	0.8
NO/NILL	120	99.2
<b>Complic</b>		
YES	0	0.0
NO/NILL	121	100.0
<b>LC/LICS</b>		
LC	61	50.4
LICS	60	49.6
<b>Analges</b>		
NSA	5	4.1
PCM	116	95.9

Table 2: Age distribution and hospital stay

Study parameters	Mean	Median	SD	Min.	Max.
Age (years)	45.94	46.00	14.84	9.0	85.0
Hospital stay (hrs)	27.0	24.0	13.8	4	120

patients was  $45.9 \pm 9$  to 85 years for both groups (Table 2). The average age for those who had SILC was  $46.7 \pm 15$  while that for those who had 4PLC was  $45.2 \pm 14$ . The number of males who had SILC was 26 (43.3%), while 34 (56.7%) were females. Those who had conventional 4PLC had 31 (50.8%) males and 34 (56.7%) females. Indications for the operation were similar for the two groups (Table 3). There was one conversion from SILC to 4PLC. This was a patient who had prior percutaneous drainage of gallbladder empyema in another hospital. None of the patients in the two groups were, however, converted to open cholecystectomy. There was also no intraoperative

Table 3: Analgesic requirement, symptomatology, and demographics

Study parameters	NSA (n = 5)	PCM (116)	Chi-square	p-value
<b>Gender</b>				
Male	3 (60.0)	54 (46.6)	0.348	0.555
Female	2 (40.0)	62 (53.4)		
<b>Complications</b>				
Pain	5 (100.0)	115 (99.1)	0.043	0.835
No pain	0 (0.0)	1 (0.9)		
<b>Examination</b>				
JAU	0 (0.0)	1 (0.9)	0.464	0.793
TEN	1 (20.0)	39 (33.6)		
No complication	4 (80.0)	76 (65.5)		
<b>USS</b>				
CHOLECY	0 (0.0)	1 (0.9)	9.851	0.080
CHOLELI	1 (20.0)	2 (1.7)		
MSTONE	0 (0.0)	1 (0.9)		
STONE	3 (60.0)	33 (28.4)		
STONES	1 (20.0)	73 (62.9)		
NONE	0 (0.0)	6 (5.2)		
<b>Diagnosis</b>				
CHOLECYS	0 (0.0)	6 (5.2)	23.602	0.000*
CHOLELIT	4 (80.0)	109 (94.0)		
CHOLIELI	1 (20.0)	0 (0.0)		
NONE	0 (0.0)	1 (0.9)		
<b>Anesthesia</b>				
GA	5 (100.0)	113 (97.4)	0.133	0.716
NO GA	0 (0.0)	3 (2.6)		
<b>Findings</b>				
MSTONES	0 (0.0)	1 (0.9)	2.963	0.564
PUS/STN	0 (0.0)	1 (0.9)		
STONE	3 (60.0)	30 (25.9)		
STONES	2 (40.0)	76 (65.5)		
NONE	0 (0.0)	8 (6.9)		
<b>Convert</b>				
YES	0 (0.0)	1 (0.9)	0.043	0.835
NO/NILL	5 (100.0)	115 (99.1)		
<b>Complic</b>				
YES	0 (0.0)	0 (0.0)	—	—
NO/NILL	5 (100.0)	116 (100.0)		
<b>LC/LICS</b>				
LC	4 (80.0)	57 (49.1)	1.826	0.177
LICS	1 (20.0)	59 (50.9)		

p-value < 0.05, statistically significant

complication or perioperative mortality recorded in both groups of patients.

The average length of hospital stay including in-patient and out-patient surgeries was  $23.93 \pm 9.8$ , 4 to 48 hours for those who had SILC and  $30.07 \pm 16$ , 8 to 72 hours for patients who underwent 4PLC ( $p = 0.014$ ). After undergoing SILC, 90% (54 of 60) of patients went home within 24 hours, while 75% (46 of 61) of those who had 4PLC went home within 24 hours ( $p = 0.05$ ). Patients in both groups had either paracetamol or a nonsteroidal anti-inflammatory drug (NSAID) as postoperative analgesic. Only one (1.7%) patient who had SILC required an NSAID for postoperative analgesia, while 59 (98.3%) had postoperative pain relieve using only paracetamol. Four (6.6%) of patients who had 4PLC required an NSAID for postoperative analgesia, while 57 (93.4%) had only paracetamol for postoperative analgesia ( $p = 0.177$ ), which was not statistically significant. The difference in analgesic requirement of males and females was not statistically significant, although, more males tended to take stronger analgesics (Table 4). Younger patients appeared to need stronger analgesics for pain relieve compared to older patients, ( $p = 0.015$ ) (Table 5).

Follow-up was limited to one to two postoperative office visits. No complications were noted in this period in the two groups.

**DISCUSSION**

Single incision laparoscopic cholecystectomy is not totally a new concept, it was introduced into practice as far back as 1992 by Pelosi et al<sup>4</sup> who performed a single puncture laparoscopic appendectomy. First experiences with SILC were reported by Navarra et al in 1997 and with a different approach by Piskun and Rajpal in 1999.<sup>4</sup> There have been many studies establishing the advantages of SILC as a complimentary or substitute surgical technique to conventional 4PLC. This topic, however, remains contentious and incompletely settled.

This study showed that 90% of patients who had SILC went home within 24 hours. This is similar to a study

reported by Brittney et al.<sup>14</sup> This showed a statistically significant shorter length of hospital stay for patients who had SILC. Patients who had SILC stayed an average of 7 hours less than those who had 4PLC. This result is similar to the result of other studies<sup>14</sup> who reported the mean postoperative hospital stay after SILC to be 12 hours shorter than that of patients who had 4PLC. Prasad also reported a mean postoperative hospital stay of 0.34 days after SILC as against 0.98 days after 4PLC.<sup>4</sup> Older patients stayed longer in hospital (Table 1) which is understandable because most of them have other comorbidities.

The analgesic requirement of patients who had SILC was not quite different from that of patients who went through 4PLC. Although only one patient in the SILC group required a stronger analgesic NSAID as against four patients for the 4PLC group, this was not statistically significant. Other factors which other studies have addressed either in favor or against either of the operative procedures include cost, operative time, blood loss, ergonomics and return to normal activity. Single incision laparoscopic cholecystectomy has been reported to have a slightly higher operative cost than 4PLC due to the peculiarity of the roticulating instruments required to ensure ergonomically smooth procedure.<sup>4,14</sup> It has also been reported that SILC take more operative time to complete compared to 4PLC<sup>14</sup> this has been attributed to the steep learning curve associated with SILC. This has also been associated with a high conversion rate and as well as complications.

There was one conversion from SILC to 4PLC in this study. This was a patient who had prior percutaneous drainage of gallbladder empyema in another hospital. There was no perioperative complications in the two groups.

**LIMITATIONS OF THE STUDY**

This study was a retrospective nonrandomized, single center study with few patients which constituted a limitation to the strength of its findings. The inability of the study to also address factors, such as cost, operative

**Table 4:** Demographics and hospital stay

Study parameters	NSA (5)	PCM (116)	Mean difference	Standard error of mean	95% CI		t-value	p-value
					Lower	Upper		
Age (years)	30.20 ± 9.96	46.62 ± 14.66	-16.42	6.637	-29.562	-3.279	-2.474	0.015*
Hospital stay (hrs)	24.80 ± 15.59	27.10 ± 13.74	-2.296	6.310	-14.791	10.199	-0.364	0.717

\*p-value <0.05, statistically significant

**Table 5:** Hospital stay SILC vs 4PLC

Study parameters	LC (61)	SILS (60)	Mean difference	Standard error of mean	95% CI		t-value	p-value
					Lower	Upper		
Age (years)	45.18 ± 14.66	46.71 ± 15.10	-1.536	2.705	-6.893	3.820	-0.568	0.571
Hospital stay (hrs)	30.07 ± 16.33	23.93 ± 9.81	6.133	2.459	1.264	11.00	2.494	0.014*

\*p-value <0.05, statistically significant



time, blood loss and long-term outcomes also constitute a weakness. It is hoped that future studies would address this inherent challenge.

## CONCLUSION

Single incision laparoscopic cholecystectomy appears to offer prospects for shorter hospital and early return to work compared to conventional 4PLC. Patients undergoing either SILC or 4PLC appear to have similar analgesic requirement. Extrapolating this to pain difference between the two surgical technique, however, require caution. Single incision laparoscopic cholecystectomy as a surgical technique is, however, feasible and promising for treatment of symptomatic cholelithiasis.

## REFERENCES

1. Pan MX, Jian ZS, Cheng Y, Xu XP, Zhang Z, et al. Single incision versus three port laparoscopic cholecystectomy: a prospective randomized study. *World J Gastroenterol* 2013 Jan 21;19(3):394-398.
2. Antoniou SA, Pointner R, Grandrath FA. Single incision laparoscopic cholecystectomy: a systemic review. *Surg Endosc* 2011 Feb;25(2):367-377.
3. Lianguan G, Chhanghuan S, Jianfen B. Single incision versus conventional laparoscopic cholecystectomy outcomes. A meta-analysis of randomized control trials: *plos one* 8(10): e 76530.
4. Prasad A, Mukherjee KA, Kaul S, Kaur M. Post operative pain after cholecystectomy; conventional versus single incision laparoscopic cholecystectomy. *J Minim Access Surg* 2011 Jan-Mar;7(1):24-27.
5. Petrostos AC, Molinelli BM. Single incision multiport laparoscopic surgery (SIMPLE): early evaluation of SIMPLE cholecystectomy in a community setting. *Surg Endosc* 2009 Nov;23(11):2631-2637.
6. SAGES: conventional four port (incision) laparoscopic cholecystectomy; early report of the first prospective randomized sham controlled trial.
7. Qiu Z, Sun J, Pu Y, Jiang T, Cao J, Wu W. Learning curve of transumbilical single incision laparoscopic cholecystectomy. A preliminary study of 80 selected patients with benign gall-bladder disease. *World J Surg* 2011 Sep;35(9): 2092-2101.
8. Marker SR, Karthikesalingam A, et al. Conventional multiport cholecystectomy; a systemic review and meta-analysis. *Surgical endoscopy* 2012;26(5):1205-1213.
9. Brittney LC, Veronica EC, David TA. *Proc (Bayl Univ med Cent)* 2012 Oct;25(4):319-323.
10. Robert KE, Solomon D, Duffy AJ, Bell RL. Single incision laparoscopic cholecystectomy; a surgeons initial experience with 56 consecutive cases and a review of the literature. *J Gastrointest Surg* 2010 Mar;14(3):506-510.
11. Davidsons BR. Fewer than four ports versus four ports for laparoscopic cholecystectomy. *Cochrane Data-base Syst Rev* 2014 Feb 20;2.
12. Araoye MO. *Research methodology with statistics for health workers and social sciences.* Nathudex Publishers 2004; 115-120, Ilorin, Nigeria.
13. Cusherie A. How I do it. *Laparoscopic cholecystectomy.* *JR Coll Surg Edin* 44, 1999 June;187-192.
14. Brittney LC, Veronica EC, David TA. Single incision laparoscopic cholecystectomy versus traditional four port cholecystectomy *Proc (Bayl Univ Med Cent)* 2012;25(4):319-323.