



■ INTRODUCTION

Fibroids or leiomyomas are a very commonly occurring uterine tumor affecting up to 20–25% of women. Fibroid develops from benign transformation of a single smooth muscle cell. The growth of myoma is dependent on many factors. Increased estrogen stimulation alone or together with growth hormone or human placental lactogen appears to be the major growth regulator of fibroid. The severities of symptoms depend on the number of tumors, size, and location. Many a time, they can cause abdominal pressure leading to urinary frequency, abdominal pain, or constipation. One of the common occurrences is dysfunctional uterine bleeding (DUB) due to altered blood flow through the uterus. The fibroids many a time do not affect pregnancy.

Fibroids are clinically diagnosed in 25% of women, although their actual incidence is probably much higher since they are frequently found on routine ultrasound. In women with menorrhagia, the hematocrit is used to assess the degree of anemia. Patients with large broad ligament fibroid may require an intravenous pyelogram to rule out any ureteral obstruction. For anemic patients, preoperative treatment with gonadotropin-releasing hormone (GnRH) may enable restoration of a normal hematocrit and decrease the size of myoma and, thus, reduce the risk of transfusion.

Fibroid types are defined by where they grow in relation to the uterine wall (**Fig. 1**). There are four types of uterine fibroids:

1. **Submucosal fibroids:** Grow in the submucosa, which means just below the thin layer of tissue found in the uterus. These fibroids can protrude into the uterine cavity. These are the rarest type of fibroid.
2. **Intramural fibroids:** Grown in and are contained within the uterine wall. These are the most common type of fibroid.
3. **Subserosal fibroids:** Grown on the outside of the uterine wall.
4. **Pedunculated fibroids:** Types of fibroids that grow on stalks or stems. These stems are attached to the uterine wall and can grow either outside the uterus or inside the uterine cavity.

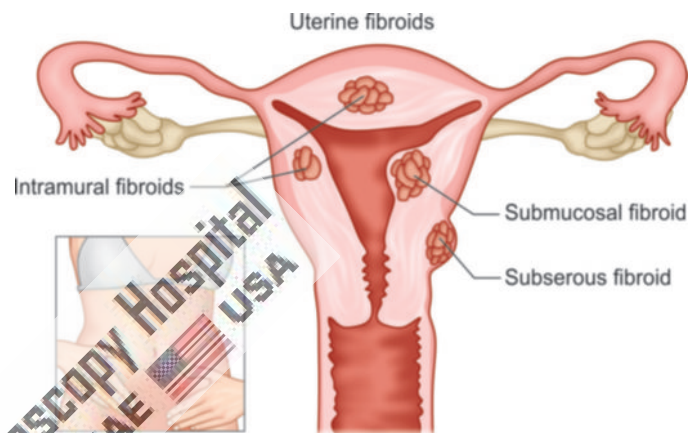


Fig. 1: Different types of fibroid uterus.

Uterine leiomyomas are the most frequent indication for hysterectomy all over the world. Many patients with symptomatic leiomyomas desire to retain the option of future childbearing or simply want to preserve their uterus. For these women, myomectomy, the removal of the myomas with reconstruction and preservation of the uterus, is an important option.

Over the past 10 years, several studies have demonstrated that laparoscopic myomectomy has several advantages over laparotomic and minilaparotomic approaches, including lower operative hemoglobin drop, shorter hospital stays, less postoperative pain, and faster recovery times. On the other hand, laparoscopy itself is a surgical technique that may present significant challenge to the surgeons. The suture of the uterine wall defect is probably the most difficult and time-consuming task for surgeons performing laparoscopic myomectomy.

■ INDICATIONS

The decision to perform surgery for uterine leiomyoma is complex and varies from patient to patient based on their medical conditions, surgical history, clinical picture, and patient preference. In general, consideration for a hysterectomy is given in patient with:

- **Excessive uterine bleeding:**
 - Profuse bleeding causing lifestyle derangements that is refractory to medical management
 - Uterine bleeding that results in anemia

- *Pelvic discomfort caused by myomas:*
 - Acute and severe
 - Chronic lower abdominal pain or low back or pelvic pressure with evidence of sizeable leiomyoma on imaging studies
- Leiomyomas that are palpable abdominally.

■ CONTRAINDICATIONS

- Endometrial cancer
- Uterine sarcoma

Intraoperatively use of dilute vasopressin helps to minimize the blood loss. Vertical uterine incisions bleed less than transverse incisions.

Single, vertical, anterior, and midline incisions are least likely to form adhesion. Although sutures predispose to adhesions, they are almost always necessary to close the uterine defect.

If during myomectomy, the endometrial cavity is entered due to large size of myoma, then such a patient when subsequently becomes pregnant should necessarily undergo cesarean delivery.

Preoperative GnRH agonist has been used by some gynecologists to decrease myomas and intraoperative blood loss. The risk of future uterine rupture is a major concern following myomectomy. The difficulty of adequately closing the layers laparoscopically and use of electrocoagulation may contribute to the risk of uterine rupture.

Uteroperitoneal fistulas may follow laparoscopic myomectomy because meticulous laparoscopic approximation of all layers is very difficult. Use of electrocautery for hemostasis inside the uterine defect may also increase the risk of uteroperitoneal fistula formation.

The chances of postoperative adhesion are also quite high in case of laparoscopic myomectomy. A single uterine incision for removal of multiple leiomyomas and subserosal approximation of the uterine defect should be done.

Laparoscopic-assisted myomectomy (LAM) can reduce the chance of this complication. Here, the suturing is done outside by open method so decreasing the operating time

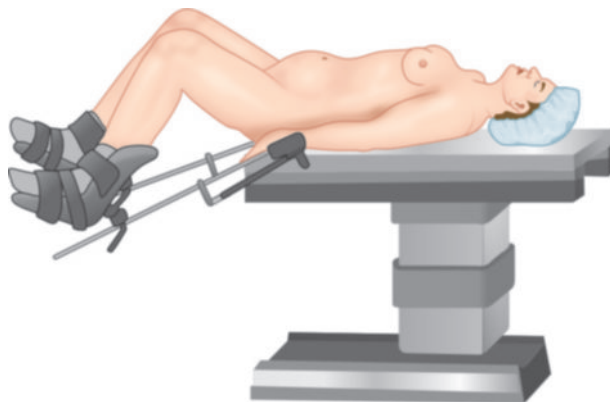


Fig. 2: Patient position in laparoscopic myomectomy.

and secure-layered suturing ensures that uterus does not rupture in later pregnancy. Pelvic observation during the laparoscopy allows the diagnosis and treatment of any other disease such as endometriosis or adhesion in the same setting. The criteria for LAM are myoma >5 cm, numerous myomas, requiring vigorous use of morcellator, deep intramural myoma, and removal that require uterine repair with sutures in multiple layers.

■ PATIENT POSITION

Correct patient positioning is a key component of successful laparoscopic myomectomy (**Fig. 2**). Table height should be at or below the waistline of the operating surgeon to avoid muscular fatigue from the nonphysiological position of the surgeon's arms during the procedure. The patient's knees should be widely separated in Allen-type stirrups. Padded supports should be applied to the foot and posterior calf. Deep vein thrombosis (DVT) prophylaxis stockings above knee type should be applied before positioning the legs in stirrups. Sequential calf muscle compressors should be in place over DVT stockings. Both upper limbs are tucked on the patient's sides with the IV line in place with extension tubing.

■ POSITION OF THE SURGICAL TEAM

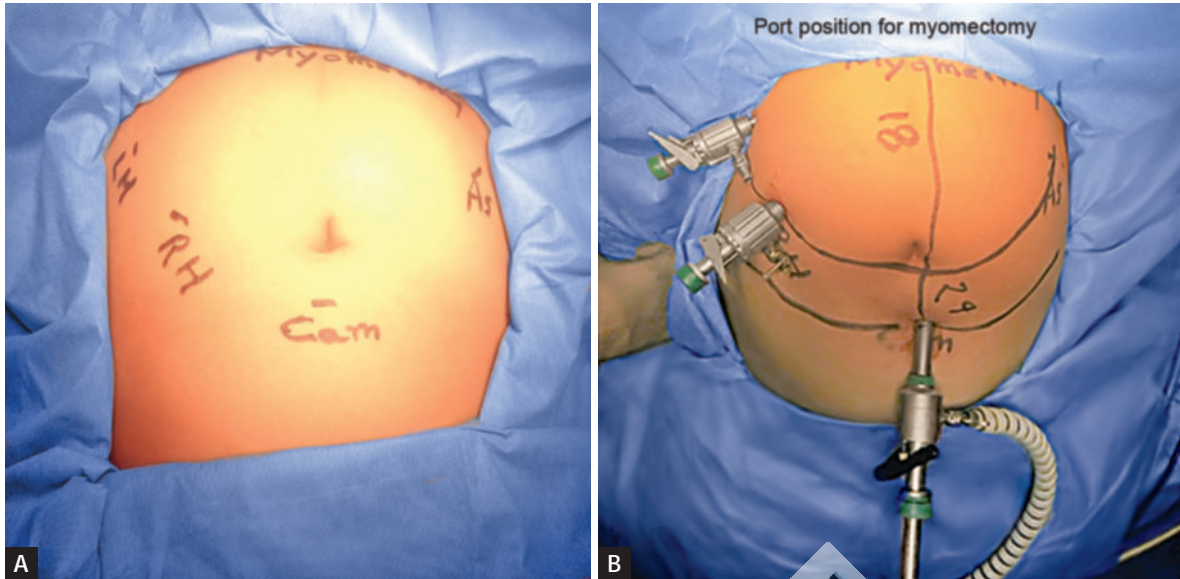
Surgeon should stand in the left side of the patient during Veress needle insertion and opposite to the side of pathology to start surgery, monitor, target organ, and surgeons visual axis in coaxial line, camera assistant should be in the right side of the surgeon, two assistant surgeons one in the right side opposite to the main surgeon and the second for holding uterine manipulator, and scrubbed nurse should be in the left side of the surgeon. Preparation of parts is done by scrubbing and draping under aseptic techniques (**Fig. 3**).

■ PORT PLACEMENT

The insertion of the trocars is a crucial issue to accomplish the operation. In most instances, when small-to-midsized

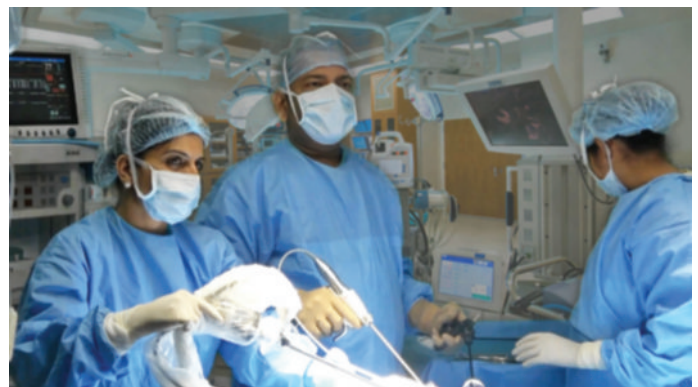

Fig. 3: Position of surgical team during laparoscopic myomectomy.



Figs. 4A and B: Port position for laparoscopic myomectomy.

fibroids are concerned, the laparoscope can be placed in standard umbilical position, using the closed- or open-entry technique of choice. However, depending on the size of the uterus, a supraumbilical insertion may be required for large myomas to gain optimal view and room for surgical manipulation. Lee and Wang (2009) suggest placing the laparoscope at the midpoint between the umbilicus and the xiphoid process (Lee-Huang point), if the uterine size is >14 weeks of gestation; the Lee-Huang point could be useful not only to increase the working distance in case of large myomas, but also to prevent injuries in the umbilical area when adhesions are expected, notably in patients with previous abdominal or pelvic surgery (Fig. 4A).

Secondary ports for laparoscopic myomectomy depend on size of uterus. Port position depends on baseball diamond concept (Fig. 4B). Myomectomy usually needs two ipsilateral and one contralateral port position. Base of the myoma should be the target and telescope should be placed 24 cm from the target. This usually comes from supraumbilical port in between umbilicus and xiphisternum. Working ports should be 18 cm from the target and this should be two ipsilateral and one contralateral.

PROCEDURE

Pedunculated myomas are easiest to remove by just coagulating and cutting the stalk. Diluted vasopressin may be injected in the base of stalk. Intramural fibroids require more manipulation, so diluted vasopressin should be injected between the myometrium and the fibroid capsule (Fig. 5). Dilute vasopressin (20 units in 100 mL of normal saline) is injected just beneath the capsule of the fibroid enough to make a bleb. Enough is injected to penetrate the capsule of the fibroid, causing the area injected to appear white or pale. This also facilitates dissection of the fibroid.

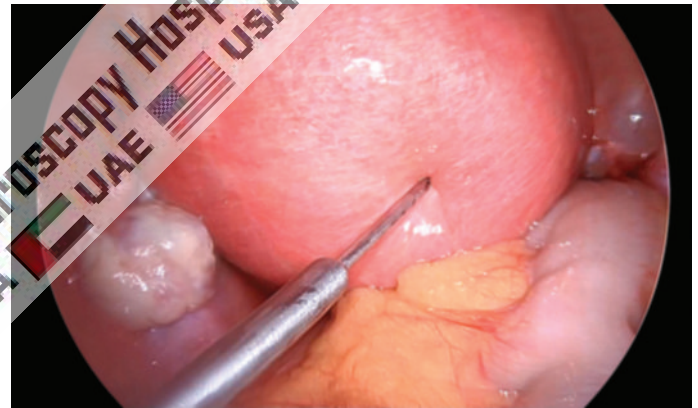


Fig. 5: Injection of vasopressin.

A vertical or horizontal incision depends on port position is made on the serosa overlying the leiomyomas using the monopolar electrode or harmonic scalpel (Fig. 6). The incision is extended until it reaches the capsule. The myometrium retracts as incision is made, exposing the myoma. Two grasping tooth forceps hold the edges of myometrium and the suction irrigator is used as blunt probe to remove the covering of the leiomyomas from its capsule.

The myoma screw should be inserted into the fibroid to apply traction, while the suction irrigation instrument can be used as a blunt dissector (Fig. 7). The harmonic scalpel, monopolar hook, or CO₂ laser can be used to further dissect capsular attachment. Vessels are electrocoagulated before being cut (Fig. 8).

After complete myoma removal, the uterine defect is irrigated; bleeding points are identified and controlled with the open jaw of bipolar. If the fibroid is small and patient does not want baby, the edges of the uterine defects are approximated by coagulating the myometrium. If the deeper defect is formed and cavity is opened, then the edges of defect should be approximated by using 4-0 polydioxanone (PDS).

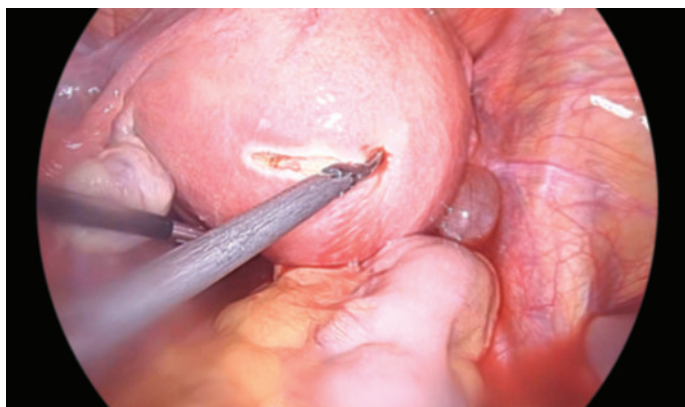


Fig. 6: Incision on seromuscular layer to start laparoscopic myomectomy.

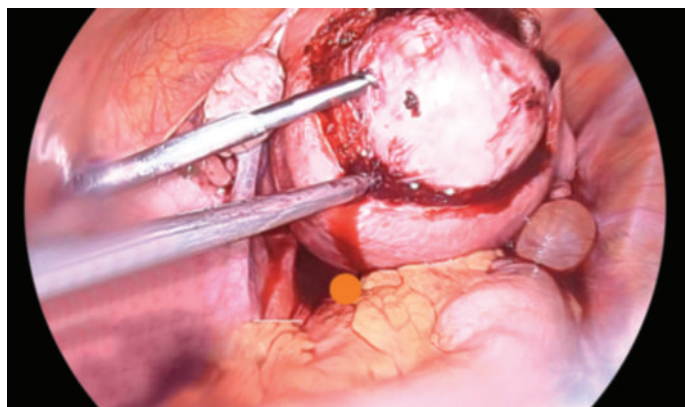


Fig. 7: Use of myoma screw for enucleation of intramural myoma.

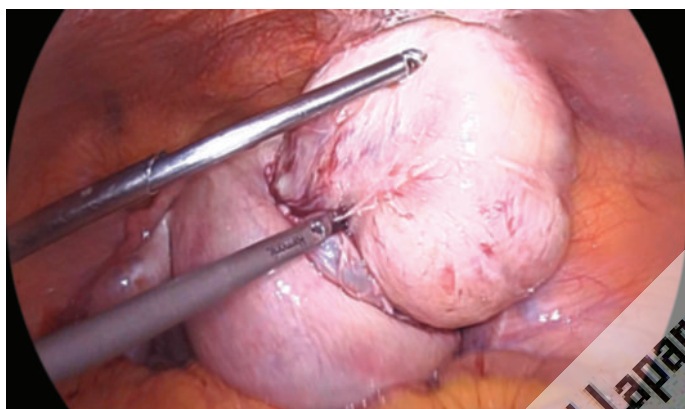


Fig. 8: Traction and countertraction for enucleation of intramural myoma.

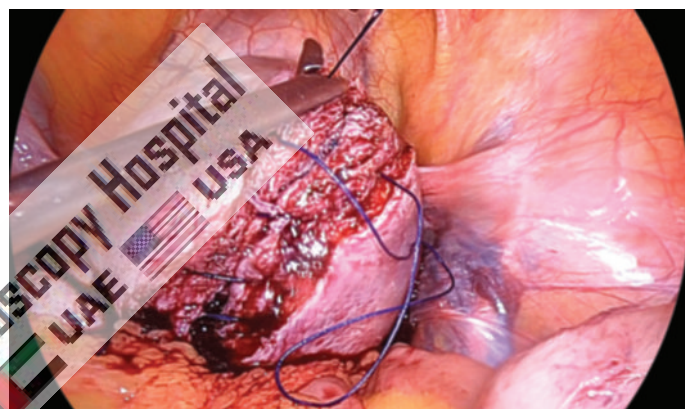


Fig. 9: Suturing of muscle layer of uterus after removal of myoma.

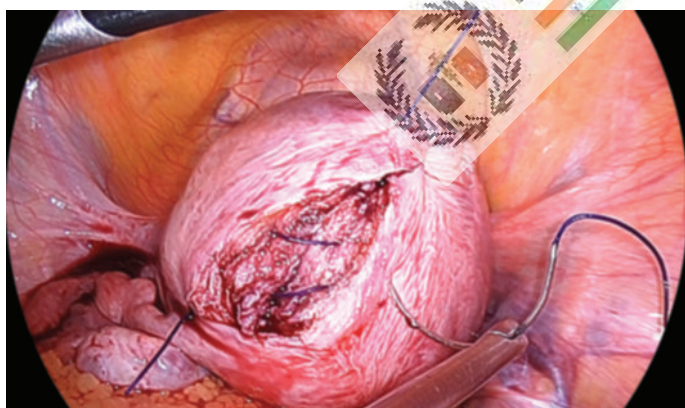


Fig. 10: Suturing of serosal layer after suturing muscle layer of uterus.

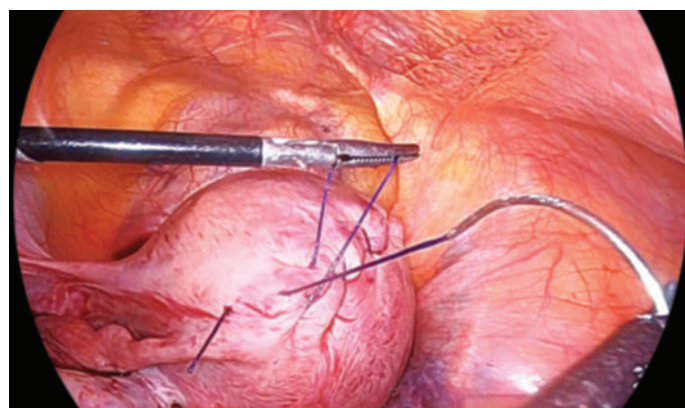


Fig. 11: Continuous suturing of layers of uterus after removal of myoma.

The repair mainly involves suturing of muscle layer and subserosal layer by No. 1 Vicryl or PDS by continuous suture or can be done en masse as one single layer interrupted extracorporeal square knot. Sutures are applied at a distance of 5–10 mm depending on vascularity of myoma in multiple layers according to depth of intramural myoma (Figs. 9 to 13). A new kind of suture, bidirectional barbed thread (Quill Self-Retaining System; Angiotech Pharmaceuticals, Inc., Vancouver, British Columbia, Canada), has been

recently made available to surgeons; this suture consists of standard material with tiny barbs cut into the length of the thread facing in opposite directions from the midpoint and with a needle at each end.

Common methods of extraction include removal via posterior colpotomy and by electric morcellation (Figs. 14 and 15). The performance of posterior colpotomy is facilitated by an assistant elevating the posterior fornix of the vagina from below with a veil held by a sponge forceps

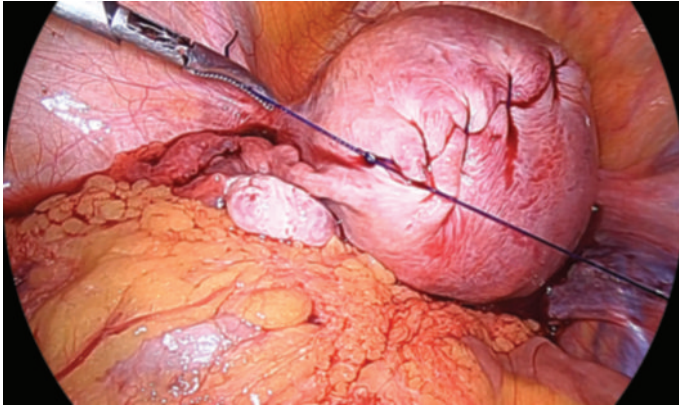


Fig. 12: Suturing knot termination of all the layers of uterus after removal of myoma.

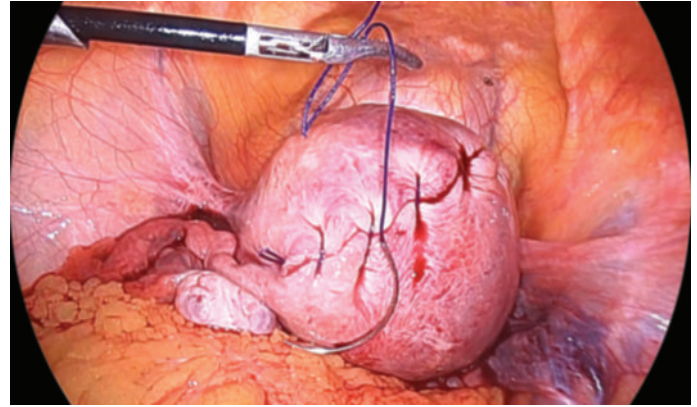


Fig. 13: Completion of suturing of muscle layer and serosal layer after removal of myoma.

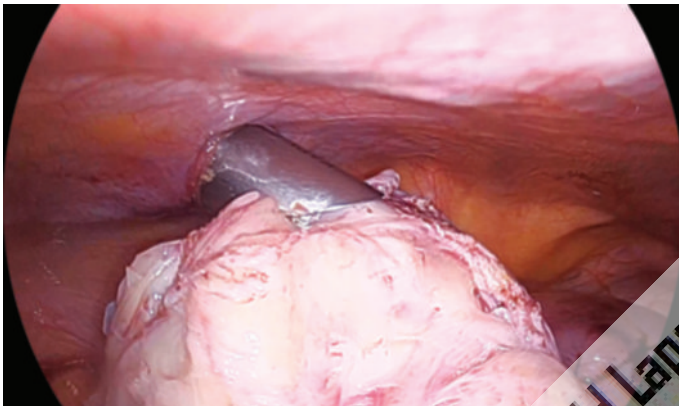


Fig. 14: Careful morcellation of fibroid uterus.

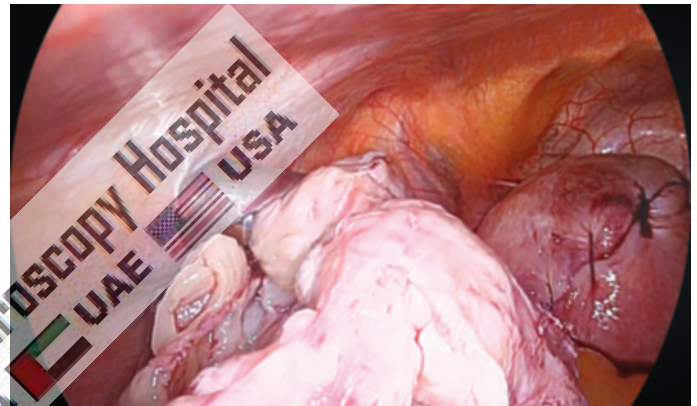


Fig. 15: Morcellation of fibroid uterus should be always under vision.

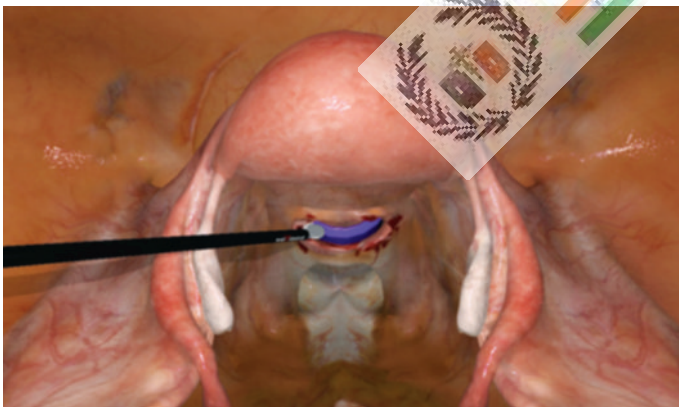

Fig. 16: Posterior colpotomy for removal of myoma with the help of spatula or hook.

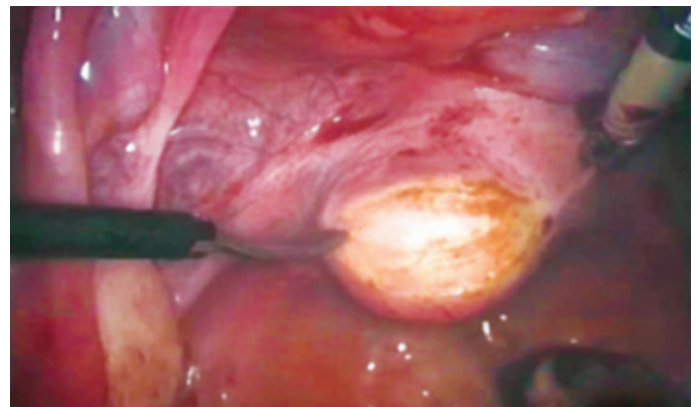

Fig. 17: Posterior colpotomy for removal of myoma with the help of monopolar scissors.

or colpotomizer (**Fig. 16**). The posterior colpotomy is made about 2 cm above the vaginal attachment of the uterosacral ligaments using monopolar cutting current of spatula, hook, monopolar scissors, or harmonic scalpel (**Fig. 17**).

A 10-mm forceps with jaws are inserted through the colpotomy under direct vision and this is used to grasp the myoma (**Fig. 18**). Depending on the size, the myoma may be extracted whole or if large morcellated before extraction

through the colpotomy. Alternatively, the 10 mm accessory port may be enlarged to 12–15 mm to allow the introduction of an electric morcellator (**Fig. 19**). Claw forceps are inserted through the morcellator channel and used to grasp the myoma, which is then progressively cut by the morcellator and extracted piecemeal. The morcellator should be held as if pointing to the abdominal wall in such a way as to avoid the risk of injury to surrounding organs by the morcellator

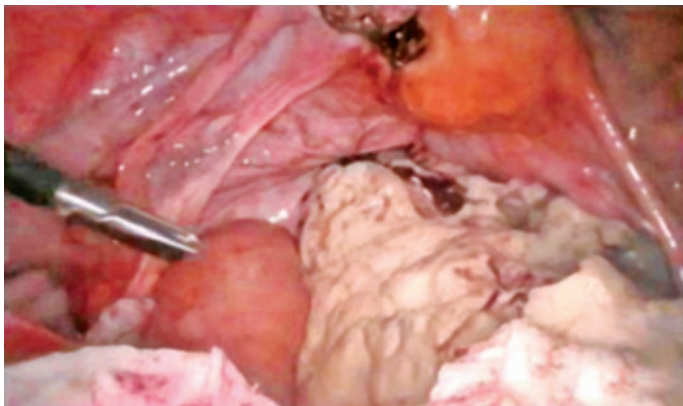


Fig. 18: Extraction of myoma through colpotomy.

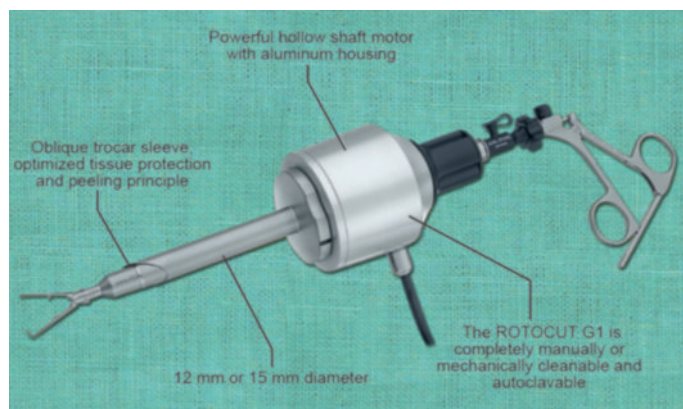


Fig. 19: Morcellator is necessary equipment for myoma tissue retrieval.

blade (Figs. 14 and 15). Following extraction, irrigation is performed as deemed adequate using normal saline. Especially in cases with associated infertility, Interceed may be placed along suture lines as further prophylaxis against adhesions.

After repair, thorough suction and irrigation should be performed. Some gynecologist uses adhesive medical glues over the suture line to prevent adhesion. Even in the hands of an expert, the laparoscopic myomectomy is difficult and challenging. Tumble square knot is advisable, if the edges are in tension. Dundee jamming knot with continuous suturing may be used, if the tension is not too much, followed by Aberdeen termination. Precise suturing of several layers is almost impossible laparoscopically.

Intraligamentous and broad ligament fibroids are difficult to remove due to the risk of injury to ureter and uterine artery at the time of dissection. Following a thorough exposure of ureter and vessels and depending on the location of myoma, an incision is made on the anterior or posterior leaf of the broad ligament and the leiomyomas are slowly shelled as any other subserosal or intramural fibroid.

Throughout the procedure, the location of the ureter is monitored and bleeding points are controlled by bipolar. The broad ligament and peritoneum are not closed in cases of broad ligament myoma. If postoperative oozing is anticipated, a drain should be left.

Upon completion, ports are removed under vision. It is important to ensure that all gas is let out. The 12 mm port is closed using Cobbler needle or Veress needle technique under vision. The port with the telescope is removed last with the telescope in place such that the cannula comes out of the incision before the tip of the telescope. This technique is employed to prevent omentum or bowel entrapment in the incision. The port is closed with sutures previously placed with Cobbler or Veress needle technique. The 5 mm ports do not require closure. The skin incision is closed with staples or Steri-Strip and a dry dressing is applied.

REMOVAL OF MYOMA MORSAFE

The Food and Drug Administration (FDA) looked at studies about the use of power morcellation to find out how often problems occur. They found that anywhere from 1 in 225 to 1 in 580 women treated for fibroids by having their uterus or fibroids removed were later found to have uterine sarcoma. Fibroid removal is one of the difficult and time-consuming procedures. Larger myomas may be removed through a posterior colpotomy. In women with concurrent posterior cul-de-sac pathology, posterior colpotomy is not safe. Medium- and large-sized fibroids are morcellated using a morcellator. The process is ineffective for calcified myomas. For infected tissue and in case of suspected carcinoma, tissue retrieval bag should be used (Figs. 20 and 21). Many sizes of disposable tissue retrieval bags are available and hard rim of these retrieval bags is easy to negotiate inside the abdominal cavity. Morcellation of a malignancy is contraindicated and women should be evaluated preoperatively to identify malignancy. However, leiomyosarcoma cannot be reliably diagnosed preoperatively; thus, there is a risk that a woman with a presumed leiomyoma may have a malignancy that may be spread through morcellation, leading to a potentially worsened prognosis. Although an abdominal hysterectomy or myomectomy may reduce the chance of spreading cancer cells in women with undiagnosed leiomyosarcoma, it is associated with increased morbidity when compared with minimally invasive approaches. The obstetrician-gynecologist and patient should engage in shared decision-making, including informed consent explaining the risks and benefits of each approach to surgery for presumed leiomyomas, the risks and benefits of morcellation, and alternatives to morcellation.

COMPLICATIONS

Laparoscopic myomectomy has all of the usual risks of laparoscopy, predominantly those related to trocar placement. This includes injury to bladder, bowel, ureter,

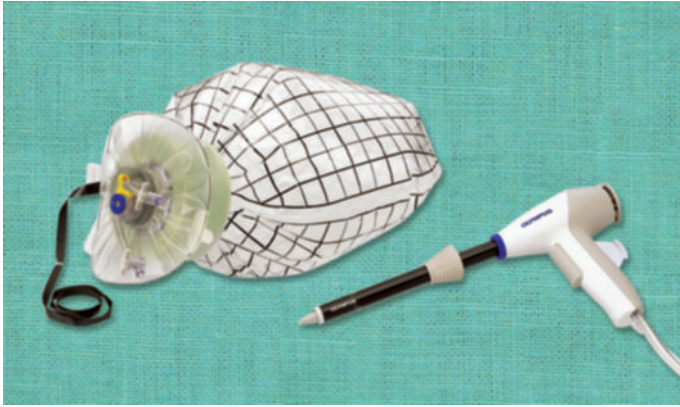


Fig. 20: Morcellation of myoma in Endobag.

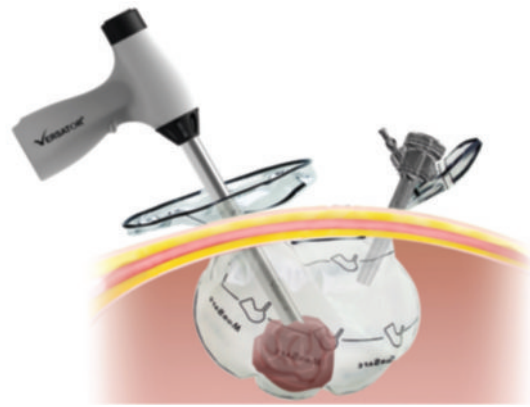


Fig. 21: Morcellation of myoma in Morsafe Endobag.

and blood vessels, and the need to convert to a laparotomy. Rates of conversion vary from very low to 8–10%, largely depending on the complexity of the case.

Suboptimal defect closures are of great concern for uterine rupture in future labor. A number of case reports have been published that describe uterine rupture after laparoscopic myomectomy. Two retrospective analyses evaluating uterine rupture after laparoscopic myomectomy showed no cases of uterine rupture. Another retrospective study showed a rupture rate of 3.7% (2/54 patients). The largest published series of laparoscopic myomectomy reported one uterine rupture per 213 patients. The risk of unexpected leiomyosarcoma is uncertain, but estimates range from 1 in 498 to <1 in 10,000. For women undergoing surgery for presumed leiomyomas, the higher procedural risk of abdominal hysterectomy or myomectomy (to avoid the risk of spreading malignant cells from an unsuspected leiomyosarcoma) must be balanced against the risk of morcellating an unanticipated malignancy and its associated morbidity and mortality. Based on existing data, this balance may favor a minimally invasive approach for younger women. However, because of the increasing prevalence of leiomyosarcoma with advancing age (and interpreting the age cutoff of 50 years used in the decision analyses as a proxy for menopause), for postmenopausal women, this balance may favor procedures that do not involve morcellation.

■ CONCLUSION

Laparoscopic myomectomy can be regarded as an alternative to open myomectomy in well-selected patients. Most studies failed to document significant differences between the two techniques as to the rate of complications and showed better figures of recovery and hospital stay in the laparoscopy group. Although laparoscopic myomectomy is still an operation that requires high skills, it is possible that the increasing laparoscopic competence of gynecologist, along with the advances in surgical instrumentation and




the availability of new suturing materials, will contribute to make it a more widespread procedure.




■ BIBLIOGRAPHY



1. AAGL Advancing Minimally Invasive Gynecology Worldwide. AAGL practice report: Morcellation during uterine tissue extraction. *J Minim Invasive Gynecol.* 2014;21:517-30.
2. ACOG Committee Opinion No. 770: Uterine morcellation for presumed leiomyomas. *Obstet Gynecol.* 2019;133:e238-48.
3. American Cancer Society (ACS). (2021). Survival rates for uterine sarcoma. [online] Available from <https://www.cancer.org/cancer/uterine-sarcoma/detection-diagnosis-staging/survival-rates.html>. [Last accessed May, 2021].
4. Banas T, Klimek M, Fugiel A, Skotniczny K. Spontaneous uterine rupture at 35 weeks' gestation, 3 years after laparoscopic myomectomy, without signs of fetal distress. *J Obstet Gynaecol Res.* 2005;31:527-30.
5. Brölmann H, Tanos V, Grimbizis G, Ind T, Philips K, van den Bosch T, et al. Options on fibroid morcellation: a literature review. *Gynecol Surg.* 2015;12:3-15.
6. Desai VB, Wright JD, Schwartz PE, Gross CP, Xu X. In reply. *Obstet Gynecol.* 2018;132:519-20.
7. Dubuisson J, Fauconnier A, Deffarges J, Norgaard C, Kreiker G, Chapron C. Pregnancy outcome and deliveries following laparoscopic myomectomy. *Hum Reprod.* 2000;15:869-73.
8. Dubuisson JB, Fauconnier A, Chapron C, Kreiker G, Norgaard C. Reproductive outcome after laparoscopic myomectomy in infertile women. *J Reprod Med.* 2000;45:23-30.
9. Einstein MH, Barakat RR, Chi DS, Sonoda Y, Alektiar KM, Hensley ML, et al. Management of uterine malignancy found incidentally after supracervical hysterectomy or uterine morcellation for presumed benign disease. *Int J Gynecol Cancer.* 2008;18:1065-70.
10. Farmer RM, Kirschbaum T, Potter D, Strong TH, Medearis AL. Uterine rupture during trial of labour after previous cesarean section. *Am J Obstet Gynecol.* 1991;65:996-1001.
11. Flamm BL, Goings JR, Liu Y, Wolde-Tsadik G. Elective repeat cesarean delivery versus trial of labor: a prospective multicenter study. *Obstet Gynecol.* 1994;83:927-32.
12. Glaser LM, Friedman J, Tsai S, Chaudhari A, Milad M. Laparoscopic myomectomy and morcellation: a review of techniques, outcomes, and practice guidelines. *Best Pract Res Clin Obstet Gynaecol.* 2018;46:99-112.
13. Golan D, Aharoni A, Gonen R, Boss Y, Sharf M. Early spontaneous rupture of the post myomectomy gravid uterus. *Int J Gynaecol Obstet.* 1990;31:167-70.

14. Grande N, Catalano GF, Ferrari S, Marana R. Spontaneous uterine rupture at 27 weeks of pregnancy after laparoscopic myomectomy. *J Minim Invasive Gynecol.* 2005;12:301.
15. Hensley ML, Leitao MM. (2021). Treatment and prognosis of uterine leiomyosarcoma. [online] Available from <https://www.uptodate.com/contents/treatment-and-prognosis-of-uterine-leiomyosarcoma>. [Last accessed May, 2021].
16. Hurst BS, Matthews ML, Marshburn PB. Laparoscopic myomectomy for symptomatic uterine myomas. *Fertil Steril.* 2005;83:1-23.
17. Kumakiri J, Takeuchi H, Kitade M, Kikuchi I, Shimanuki H, Itoh S, et al. Pregnancy and delivery after laparoscopic myomectomy. *J Minim Invasive Gynecol.* 2005;12:241-6.
18. Landi S, Fiaccavento A, Zaccoletti R, Barbieri F, Syed R, Minelli L. Pregnancy outcomes and deliveries after laparoscopic myomectomy. *J Am Assoc Gynecol Laparosc.* 2003;10:177-81.
19. Lieng M, Istre O, Langebrenne A. Uterine rupture after laparoscopic myomectomy. *J Am Assoc Gynecol Laparosc.* 2004;11:92-3.
20. Lynam S, Young L, Morozov V, Rao G, Roque DM. Risk, risk reduction and management of occult malignancy diagnosed after uterine morcellation: a commentary. *Womens Health (Lond).* 2015;11:929-44.
21. Malin JL, Kahn KL, Adams J, Kwan L, Laouri M, Ganz PA. Validity of cancer registry data for measuring the quality of breast cancer care. *J Natl Cancer Inst.* 2002;94:835-44.
22. Moore BJ, White S, Washington R, Coenen N, Elixhauser A. Identifying increased risk of readmission and in-hospital mortality using hospital administrative data: The AHRQ Elixhauser Comorbidity Index. *Med Care.* 2017;55:698-705.
23. Mowers EL, Skinner B, McLean K, Reynolds RK. Effects of morcellation of uterine smooth muscle tumor of uncertain malignant potential and endometrial stromal sarcoma: case series and recommendations for clinical practice. *J Minim Invasive Gynecol.* 2015;22:601-6.
24. Nielsen TF, Ljungblad U, Hagberg H. Rupture and dehiscence of cesarean section during pregnancy and delivery. *Am J Obstet Gynecol.* 1989;160:569-73.
25. Nkemayim DC, Hammadeh ME, Hippach M, Mink D, Schmidt W. Uterine rupture in pregnancy subsequent to previous laparoscopic electromyolysis: case report and review of the literature. *Arch Gynecol Obstet.* 2000;264:154-6.
26. Oduyebo T, Rauh-Hain AJ, Meserve EE, Seidman MA, Hinchcliff E, George S, et al. The value of re-exploration in patients with inadvertently morcellated uterine sarcoma. *Gynecol Oncol.* 2014;132:360-5.
27. Ozeren M, Ulusov M, Uvanik E. First-trimester spontaneous uterine rupture after traditional myomectomy: case report. *Isr J Med Sci.* 1997;33:752-3.
28. Pelosi MA, Pelosi MA. Spontaneous uterine rupture at thirty-three weeks subsequent to previous superficial laparoscopic myomectomy. *Am J Obstet Gynecol.* 1997;177:1547-9.
29. Phelan JP, Clark SL, Diaz F, Paul RH. Vaginal birth after cesarean. *Am J Obstet Gynecol.* 1987;157:1510-15.
30. Pirracchio R, Resche-Rigon M, Chevret S. Evaluation of the propensity score methods for estimating marginal odds ratios in case of small sample size. *BMC Med Res Methodol.* 2012;12:70.
31. Pisarska MD, Carson SA. Incidence and risk factors for ectopic pregnancy. *Clin Obstet Gynecol.* 1999;42:2-8.
32. Raine-Bennett T, Tucker LY, Zaritsky E, Littell RD, Palen T, Neugebauer R, et al. Occult uterine sarcoma and leiomyosarcoma: incidence of and survival associated with morcellation. *Obstet Gynecol.* 2016;127:29-39.
33. Ramirez PT, Frumovitz M, Pareja R, Lopez A, Vieira M, Ribeiro R, et al. Minimally invasive versus abdominal radical hysterectomy for cervical cancer. *N Engl J Med.* 2018;379:1895-904.
34. Raspagliesi F, Maltese G, Bogani G, Fucà G, Lepori S, De Iaco P, et al. Morcellation worsens survival outcomes in patients with undiagnosed uterine leiomyosarcomas: a retrospective MITO group study. *Gynecol Oncol.* 2017;144:90-5.
35. Roopnarinesingh S, Suratsingh J, Roopnarinesingh A. The obstetric outcome of patients with previous myomectomy or hysterectomy. *West Indian Med J.* 1985;34:59-62.
36. Seagle BLL, Sobocki-Rausch J, Strohl AE, Shilpi A, Grace A, Shahabi S. Prognosis and treatment of uterine leiomyosarcoma: A National Cancer Database study. *Gynecol Oncol.* 2017;145:61-70.
37. Seiner P, Farina C, Todros T. Laparoscopic myomectomy and subsequent pregnancy: results in 54 patients. *Hum Reprod.* 2000;15:1993-6.
38. Siedhoff MT, Doll KM, Clarke-Pearson DL, Rutstein SE. Laparoscopic hysterectomy with morcellation vs abdominal hysterectomy for presumed fibroids: an updated decision analysis following the 2014 Food and Drug Administration safety communications. *Am J Obstet Gynecol.* 2017;216:259.e1-6.
39. Sizzi O, Manganaro L, Rossetti A, Saldari M, Florio G, Loddo A, et al. Assessing the risk of laparoscopic morcellation of occult uterine sarcomas during hysterectomy and myomectomy: Literature review and the ISGE recommendations. *Eur J Obstet Gynecol Reprod Biol.* 2018;220:30-8.
40. Stewart EA. (2020). Uterine fibroids (leiomyomas): Differentiating fibroids from uterine sarcomas. [online] Available from <https://www.uptodate.com/contents/uterine-fibroids-leiomyomas-differentiating-fibroids-from-uterine-sarcomas>. [Last accessed May, 2021].
41. Stringer NH, Strassner HT, Lawson L, Oldham L, Estes C, Edwards M, et al. Pregnancy outcomes after laparoscopic myomectomy with ultrasonic energy and laparoscopic suturing of the endometrial cavity. *J Am Assoc Gynecol Laparosc.* 2001;8:129-36.

Contact us

 **World Laparoscopy Hospital**
 **Cyber City, Gurugram, NCR Delhi**
 **INDIA : +919811416838**

 **World Laparoscopy Training Institute**
 **Bld.No: 27, DHCC, Dubai**
 **UAE : +971523961806**

 **World Laparoscopy Training Institute**
 **8320 Inv Dr, Tallahassee, Florida**
 **USA : +1 321 250 7653**