

■ INTRODUCTION

Minimal access surgery (MAS) a new surgical and interventional approach, was called by different name and one of the popular is minimally invasive surgery. However, unique complications are associated with gaining access to the abdomen for laparoscopic surgery. The technique of first entry inside the human body with telescope and instruments is called access technique. The hallmark of the new approaches is the reduction in the trauma of access. The technique for access to the peritoneal cavity, choice of access technique, placement locations, and port placement is very important in MAS. Technique of access is different for different minimal access surgical procedures. Thoracoscopy, retroperitoneoscopy, axilloscopy, and arthroscopy all have different ways of access. In this chapter, we will discuss various abdominal access techniques.

It is important to know that approximately 20% of laparoscopic complications are caused at the time of initial access. Developing access skill is one of the important achievements for the surgeon practicing MAS. First entry or access in laparoscopy is of two types: (1) closed access and (2) open access.

■ ANATOMY OF ANTERIOR ABDOMINAL WALL

Knowledge of the surgical anatomy of the abdominal wall is essential for the safe access in laparoscopic surgery. Laparoscopic instruments traverse the skin, subcutaneous fat, variable myofascial layers, preperitoneal fat, and parietal peritoneum. There are three large, flat muscles (external oblique, internal oblique, and transversus abdominis) and one long vertically oriented segmental muscle (rectus abdominis) on each side. The layers of the abdominal wall in the midline include skin, subcutaneous fat, and a fascial layer (linea alba) that is a coalescence of the anterior and posterior rectus sheath. Four major arteries on each side are also present which form an anastomotic arcade that supplies the abdominal wall. The superior and inferior epigastric artery and the branches provide the major blood supply to the rectus abdominis muscle and other medial structures (Fig. 1).

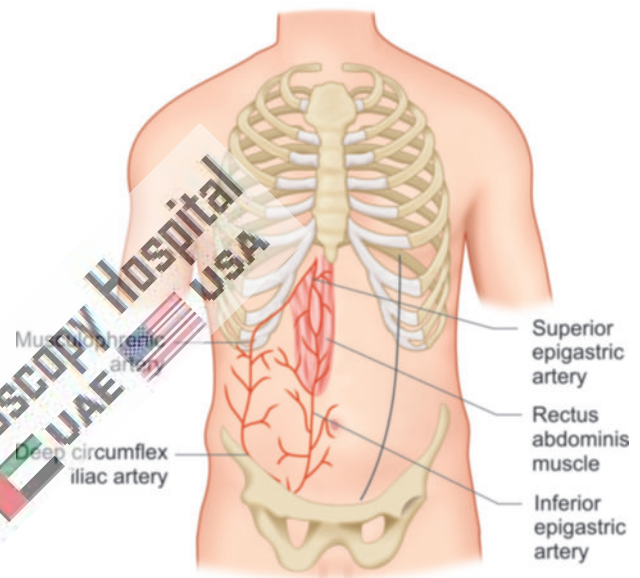


Fig. 1: Anterior abdominal wall anatomy.

Among all these arteries, the most important for laparoscopic surgeon is the inferior epigastric artery and vein. The inferior epigastric vessel landmark is less variable compared to superior epigastric. Bleeding from inferior epigastric is a big problem because it is larger in diameter than superior epigastric.

Umbilicus is the site of choice for access in majority of laparoscopic procedure. The umbilicus is a fusion of fascial layers and is devoid of subcutaneous fat. The median umbilical ligament which is obliterated urachus and paired medial umbilical ligaments, i.e., obliterated umbilical arteries are peritoneal folds that join at the inferior crease of the umbilicus, forming a tough layer. This umbilical tube scar remains after the umbilical cord obliterates which makes an attractive site of primary access of Veress needle and trocar. At the level of umbilicus, skin fascia and peritoneum are fused together, with the minimum fat. The midline of abdominal wall is free of muscle fibers, nerves and vessels except at its inferior edge where pyramidalis muscle is sometimes found. Therefore, Veress needle or trocar insertion in these locations rarely cause much bleeding. If a defect in the umbilical fascia suggests an umbilical hernia or

if any midline incision scar of previous laparoscopy is found or if any anomalies of the urachus may also exist umbilicus should not be used for primary access. If an umbilical hernia or urachal anomaly is suspected, alternative access sites may need to be considered.

The colon is attached to the lateral abdominal wall along both gutters and puncture laterally for secondary trocars should be under video control to avoid visceral injury. When left subcostal site is chosen for access it should be 2 cm below the costal margin in midclavicular line called Palmer's point. The costal margin provides good resistance as the needle is introduced. When puncture site lateral to the midline is used, it is prudent to choose location lateral to the linea semilunaris to avoid injury of superior and inferior epigastric vessels. In obese patients, the linea semilunaris may not be visible. In these, location of inferior artery can be localized by careful transillumination.

Access to preperitoneal space is gained by penetrating almost all the layers of abdominal wall except peritoneum. The open technique of access is preferable in this situation. After incising the fascia with the scalpel, fingered dissection is advisable to avoid puncture of peritoneum.

■ CLOSED ACCESS TECHNIQUE

To start any laparoscopic procedure the peritoneal cavity needs to be accessed, first to establish pneumoperitoneum and subsequently to place a port for the laparoscope and add the placement of additional ports for various laparoscopic instruments. In closed access technique, pneumoperitoneum is created by Veress needle (named for Janos Veress) (Fig. 2). The Veress needle was originally developed by Janos Veress to give patients with tuberculosis iatrogenic pneumothorax without damaging the underlying lung parenchyma (Fig. 3). It has a small-bore (1.8–2.2 mm) needle with a spring-loaded protective obturator with a side hole that recoils to cover the end of the needle, allowing




Fig. 2: Veress needle inventor—Janos Veress.

entry into a body cavity without traumatizing the underlying organs (Fig. 4). Maximum flow of gas through the eye of Veress needle is 2.5 L/min only but for safety it should be kept at 1 L/min to prevent accidental gas embolism (Fig. 5). This is a blind technique and most practiced way of access by surgeons and gynecologists worldwide. When choosing site of closed access, previous surgical incisions, or any anatomical abnormality, should be noted. Sites that have not been previously instrumented are preferred for initial access. Closed technique of access merely by Veress needle insertion and creation of pneumoperitoneum is an easy way of access but it is not possible in some of the minimal access surgical procedures such as axilloscopy, retroperitoneoscopy, and totally extraperitoneal approach of hernia repair. In general, closed technique by Veress needle is possible only if there is a preformed cavity like abdomen.

Creation of pneumoperitoneum is one of the most important steps in laparoscopy. The aim is to build up a good protective cushion of gas to ensure the safe entry of trocar and cannula.

Veress Needle Insertion

The standard method of insufflations of the abdominal cavity is via a Veress needle inserted through a small skin incision over inferior crease of umbilicus. Disposable and reusable metal Veress needles are available commercially in different lengths (8–20 cm), i.e., long for obese patients, short for thin or pediatric patients.

Before using Veress needle, it should be checked for its patency and spring action. Spring action of Veress needle can be checked by pulling the head out. The disposable

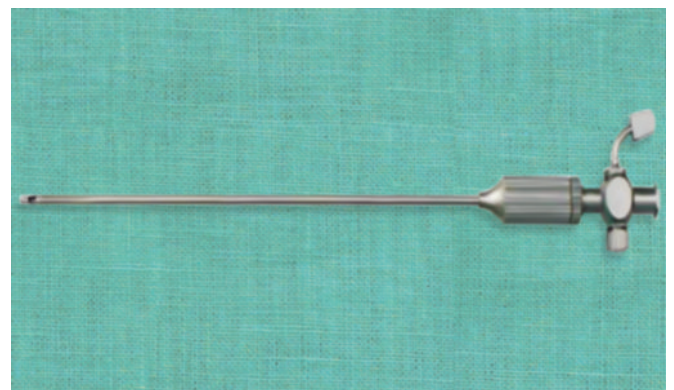


Fig. 3: Veress needle.




Fig. 4: Parts of Veress needle.




Fig. 5: Eye of Veress needle.

Veress needle spring action can be checked by pressing the sharp end against any sterilized draping.

Insufflation via the Veress needle creates a cushion of gas over the bowel for insertion of the first trocar. Insufflation then retracts the anterior abdominal wall, exposing the operative field.

Preparation of Patient

The patient should be nil orally since the morning of surgery. In some of the procedure such as laparoscopic hysterectomy or colorectal surgery where distended bowel may interfere, it is good to prepare bowel prior to the night of surgery by giving some mild purgative (polyethylene glycol). Bowel preparation can minimize the need of accessory port to retract the bowel.

Before coming to operation theater, patient should always void urine. The full urinary bladder may get perforation at the time of insertion of Veress needle or trocar. If the laparoscopic procedure is of short duration and is going to be performed of upper abdomen, then Foley catheterization is not necessary. If gynecological operative surgery or any major general surgical lower abdominal procedure has to be performed (such as hernia or adhesiolysis), it is wise to insert Foley catheter.

If surgeon is going to perform any upper abdominal procedures such as cholecystectomy, fundoplication, duodenal perforation, hiatus hernia, etc., it is good practice to have nasogastric tube in place. A distended stomach will not allow proper visualization of Calot's triangle and then surgeon has to apply more traction over fundus or Hartmann's pouch, and this may cause tenting of common bile duct (CBD) followed by accidental injury. In gynecological or lower abdominal minor laparoscopic procedure, it is not necessary to put nasogastric tube.

In MAS, shaving of skin is not must and if necessary, it should be done on operation table itself by surgeon.

Operating Room Setup

An organized well-equipped operation theater is essential for successful laparoscopy. The entire surgical team should be familiar with the instruments and their function. Each instrument should be inspected periodically for loose or broken tips even if the same instrument was used during a previous procedure. It is necessary to confirm proper sterilization of instruments because the surgeon ultimately is responsible for the proper functioning of all instrument and equipment.

The entire instrument should be placed according to wish of the surgeon so that it should be ergonomically perfect for that surgery. The coaxial alignment should be maintained. Coaxial alignment means the eye of the surgeon, target of dissection, and monitor should be placed in same axis.

Patient Position

Initially at the time of pneumoperitoneum by Veress needle, patient should be placed supine with 15° head down. The benefit of this Trendelenburg's position is that bowel will be pulled up and there will be more room in pelvic cavity for safe entry of Veress needle. It is important to remember that patient should be placed in head-down position only if surgeon is planning to insert Veress needle pointing toward pelvic cavity. If surgeon is planning to insert Veress needle perpendicular to abdominal wall as in case of very obese patient, previous midline incision or diagnostic laparoscopy in local anesthesia, the patient should be placed in supine position otherwise all the bowel will come just below the umbilicus and there is increased risk of bowel injury.

In gynecological laparoscopic procedures or if laparoscopy is planned to be performed together with hysteroscopy, patient should be positioned in lithotomy position and one assistant should be positioned between the leg of patient (**Fig. 6**). Patient's leg should be comfortably supported by padded obstetric leg holders or Allen stirrups which minimize the risk of venous thrombosis. In these procedures, surgeon needs to use uterine manipulator for proper visualization of female reproductive organs. The assistant seating between the legs of patient will keep on watching the hand movement of surgeon on monitor and he should give traction with the handle of uterine monitor in appropriate direction. If thoracoscopy or retroperitoneoscopy is planned, then patient is placed in lateral position (**Fig. 7**).

Position of Surgical Team

The laparoscopic surgeon is very much dependent and helpless with eye fixed on monitor. At the time of laparoscopic surgery, surgeon is largely depending on his correct standing position. If the surgery is of upper abdomen, French surgeons like to stand between the legs of patient, popularly known as

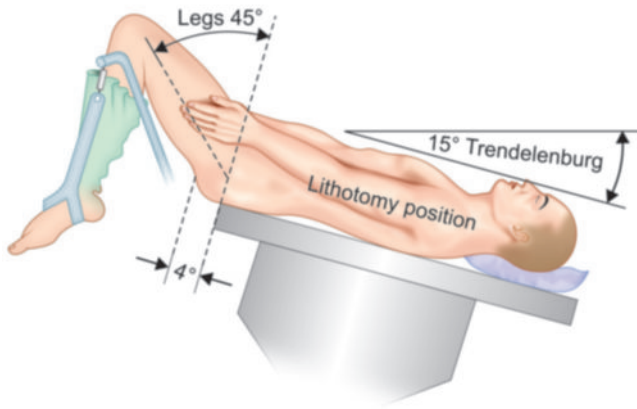


Fig. 6: Patient position in gynecological laparoscopy.

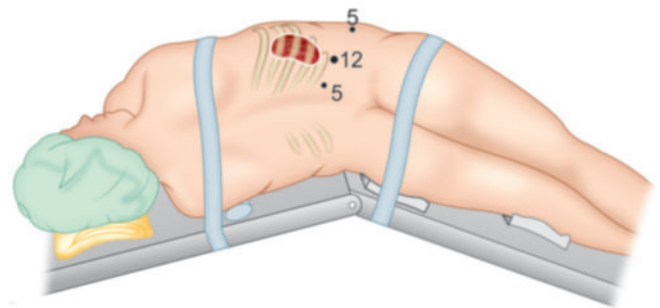
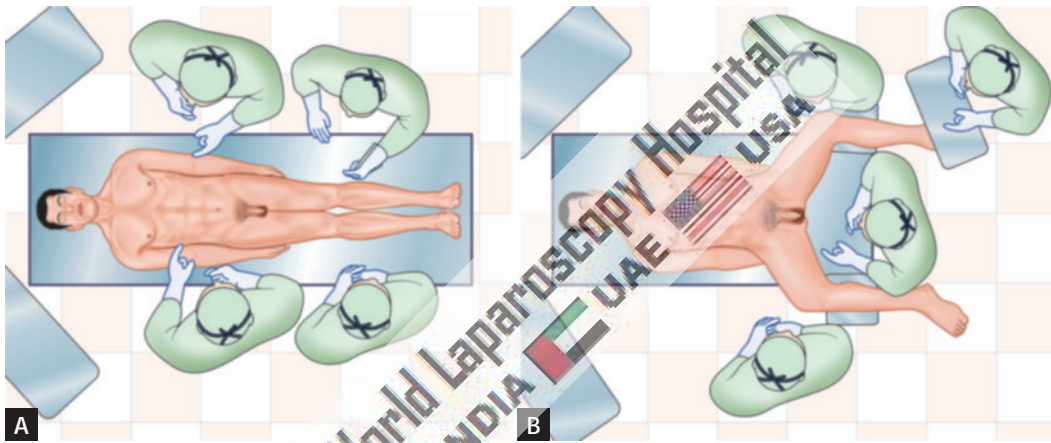


Fig. 7: Patient position in retroperitoneoscopy.



Figs. 8A and B: American versus French position.

“French position” (Figs. 8A and B). The American surgeons like to operate from left in cases of upper abdominal surgery such as cholecystectomy called as “American position”.

It is not always wise to remain standing in any one fixed position and surgeon can walk to the other side of operation table to achieve proper ergonomics. In most of the cases at the time of initial access, right-handed surgeon should stand on left side of the patient so that he can hold the Veress needle with right dominant hand. If surgeon is left-handed, he should stand right to the patient at the time of access and insert the Veress needle or trocar with left hand. This helps in inserting Veress needle and trocar toward pelvis by dominant hand. Once the initial Veress needle and first optical trocar has been introduced surgeon should stand opposite to the organ which he wants to operate on. Once all the ports are in position, the surgeon should come opposite to the side of pathology to start surgery and he should achieve coaxial alignment means eye of the surgeon, target of dissection, and center of monitor should be in one linear axis. In cholecystectomy, appendectomy, right-sided hernia or right ovarian cyst, surgeon should stand left to the patient. In left-sided pathology such as left ovarian cyst and left-sided

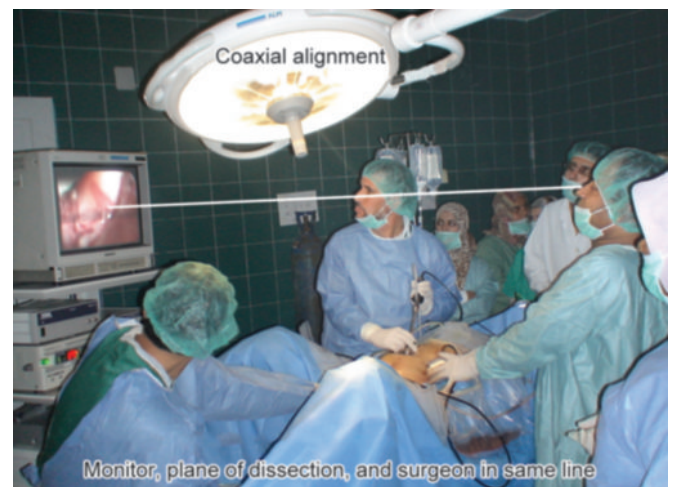

Fig. 9: Surgeon stands left to the patient in most of the right-sided pathology.

hernia, it is ergonomically better for surgeon to stand right to the patient (Fig. 9).

In most of the upper abdominal surgery, camera assistant should stand left to the surgeon and in lower abdominal surgery, he or she should stand right to the surgeon. Camera

assistant while holding telescope can pass his or her hand between body and arm of surgeon so that sometime surgeon can help him to focus his camera correctly. Camera assistant can be placed opposite to the surgeon to stand but in this case, it is better to have two monitors on both the side of patient, one for surgeon and one for camera stand and other members of surgical team. The surgeon should work in the most comfortable and less tiring position possible with shoulder relaxed, arms alongside of the body, elbows at 90° angle and forearm horizontal.

Preparation for Access

Before starting access, abdomen should be examined for any palpable lump. It is wise to tell the patient to void urine before coming to operating room but if the bladder is found full at the time of palpation. Foley catheter and nasogastric tube should be applied once patient is anesthetized. Remember that full bladder or distended stomach may be injured very easily by Veress needle or trocar.

Once the patient is cleaned painted and draped, all the connection should be attached, followed by focusing and white balancing of camera. At the time of focusing, the distance between the gauge piece and tip of the telescope should be 6–8 cm.

Choice of Gas for Pneumoperitoneum

At first, pneumoperitoneum was created by filtered room air. Carbon dioxide (CO₂) and nitrous oxide (N₂O) are now preferred gas because of increased risk of air embolism with room air. CO₂ is used for insufflation as it is 200 times more diffusible than oxygen and 20 times more absorbable than room air. It is rapidly cleared from the body by the lungs and will not support combustion. N₂O is only 68% as rapidly absorbed in blood as CO₂. N₂O has one advantage over CO₂ that it has mild analgesic effect, and hence no pain if diagnostic laparoscopy is performed under local anesthesia. CO₂ has the advantage of being noncombustible and allows the concomitant use of electrocoagulation and

laser irradiation. For short operative procedures such as sterilization or drilling, under local anesthetic N₂O may also be used. During prolonged laparoscopic procedure, N₂O should not be a preferred gas for pneumoperitoneum because it supports combustion better than air. CO₂ when comes in contact with peritoneal fluid converts into carbonic acid. Carbonic acid irritates diaphragm causing shoulder tip pain and discomfort in abdomen. Carbonic acid has one advantage also that it alters pH of peritoneal fluid (acidotic changes) and it is mild antiseptic, so the chances of infection may be slightly less compared to any other gas. Helium gas being inert in nature is also tried in many centers, but it does not have any added benefit over CO₂. Helium may be a suitable alternative to CO₂ for creating pneumoperitoneum in patients with severe cardiorespiratory disease. Some of the study suggest that pneumoperitoneum with helium will not be associated with profound circulatory depression or oxygen transport abnormalities. In addition, the use of helium is not associated with acid-base disturbances, although central venous filling pressures are similarly increased as with the use of CO₂ pneumoperitoneum. However, helium is expensive gas and because of its low water solubility helium has a lower safety margin than CO₂ in the event of gas embolism.

Introduction of Veress Needle

To access the abdomen with a closed approach using a Veress needle:

- Apply two Allis forceps to evert the inferior crease of umbilicus (**Fig. 10**).
- Give a 2-mm smiling incision in the skin and the subcutaneous tissue over inferior crease of umbilicus (**Fig. 11**).
- Hold shaft of the Veress needle as a dart (**Fig. 12**).
- Guard the length of Veress needle needed to reach the peritoneal cavity (**Fig. 13**).
- Place the needle through the incision to the level of the fascia (**Fig. 14**).

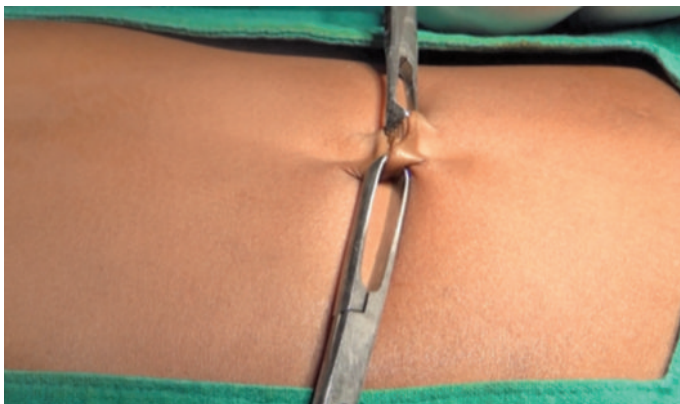


Fig. 10: Two Allis forceps is applied over crease of umbilicus.

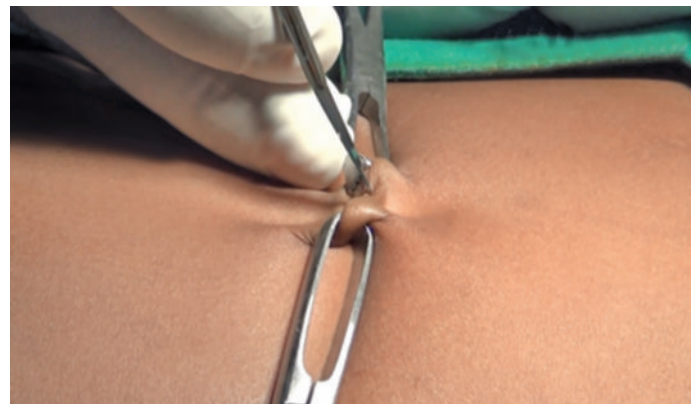

Fig. 11: 2-mm stab wound over inferior crease of umbilicus.

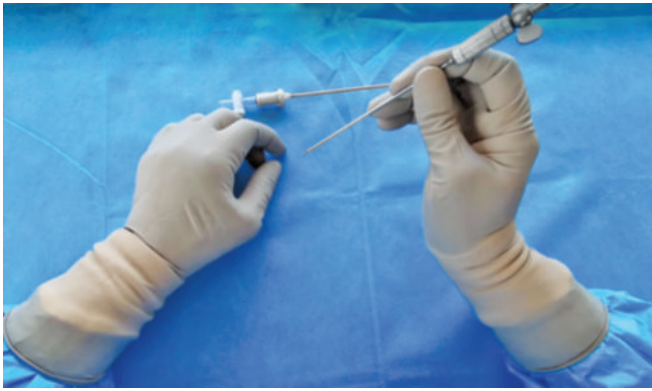


Fig. 12: Veress needle should be held like a dart.

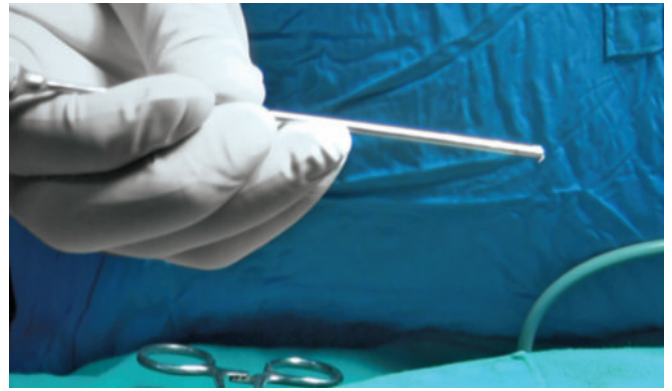


Fig. 13: Guard the required length of Veress needle.

- Grasp and elevate the abdominal wall with your left hand. It is important to note that grasping only the skin while not including the fascia may increase the rate of failed entry (**Fig. 14**).
- Hold the Veress needle just over the previously incised site and insert it through the incision at a 45° angle toward anus but keep perpendicular to the abdominal wall. This can be only achieved by lifting the abdominal wall adequately by left hand (**Fig. 14**).
- While inserting the Veress needle feel for two “pops”. The first occurs when the needle passes through the abdominal fascia and the second as it passes through the parietal peritoneum. More lateral access sites may have additional “pops” if more than one layer of fascia is traversed.
- As soon as the needle enters the peritoneal space, the displaced hub of the needle will “click” as the protective sheath recoils to cover the end of the needle. After entering in abdominal cavity, the intra-abdominal needle will also move more freely than a needle within the abdominal wall.

Veress needle should be held like a dart (**Fig. 12**). At the time of insertion, there should be 45° of elevation angle. Elevation angle is angle between instrument and body of patient. To get an elevation angle of 45° the distal end of the Veress needle should be pointed toward anus (**Fig. 14**). To prevent creation of preperitoneal slip of tip of Veress needle, it is necessary that Veress needle should be perpendicular to the abdominal wall. However, there is a fear of injury of great vessels or bowel if Veress needle is inserted perpendicular to the abdominal wall. To avoid both the difficulty (creation of preperitoneal space and injury to bowel or great vessels), the lower abdominal wall should be lifted in such a way that it should lie at 90° angle in relation to the Veress needle but in relation to the body of patient Veress needle will be at an angle of 45° pointed toward anus. Lifting of abdominal wall should be adequate so that the distance of abdominal wall from viscera should increase. If less than required dose of muscle relaxant is given in muscular patient, lifting of

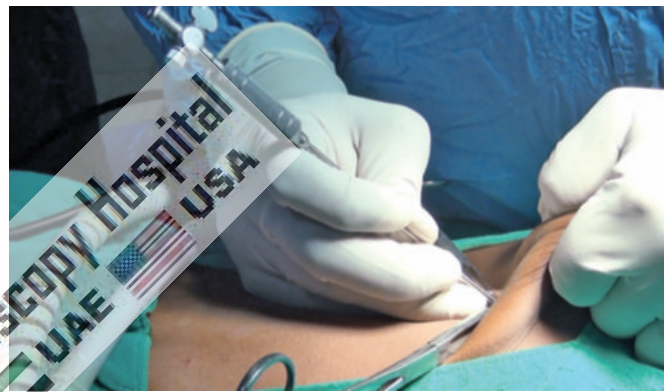

Fig. 14: Veress needle should be pointed toward anus but perpendicular to abdominal wall.

abdominal wall may be difficult. In multipara patient, lifting lower abdominal wall is very easy.

Several tests are available for confirming Veress needle placement. These include one of the following:

Needle Movement Test

Once the Veress needle is inside the abdominal cavity, the tip of Veress needle should be free and if surgeon will gently move the tip of needle there should not be feel of any resistance. It is very important to remember that Veress needle should not be moved inside the abdominal cavity much, otherwise there is a risk of laceration of bowel to be punctured.

Irrigation Test

A 10-mL syringe should be taken in one hand and surgeon should try to inject at least 5 mL of normal saline through Veress needle. If tip of Veress needle is inside the abdominal cavity, there will be free flow of saline otherwise some resistance is felt in injecting saline (**Fig. 15**).

Aspiration Test

After injecting saline, surgeon should try to aspirate that saline back through Veress needle (**Fig. 16**). If the tip of Veress

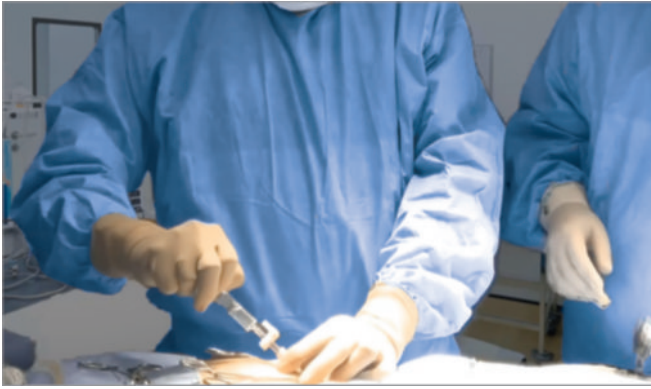

Fig. 15: Irrigation test.

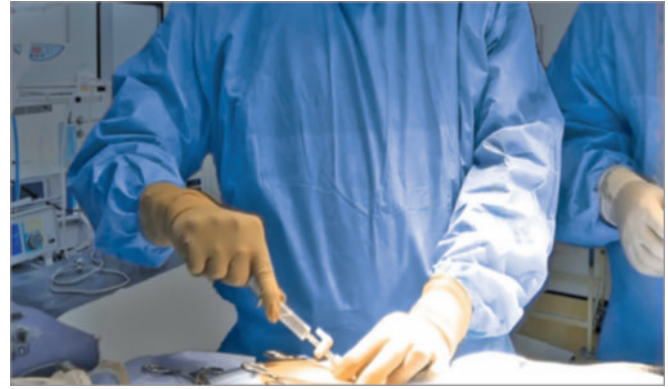

Fig. 16: Aspiration test.

needle is in abdominal cavity, the irrigated water cannot be sucked. But if it is in preperitoneal space or in muscle fiber or above; the rectus the injected water can be aspirated back. In aspiration test, if more irrigated fluid is coming, then surgeon should suspect ascites, some cysts or perforation of urinary bladder. If fecal matter is seen then perforation of bowel may be the reason and if blood is coming then the vessel injury is the cause. If any fresh blood or fecal fluid is aspirated in the syringe, surgeon should not remove the Veress needle and urgent laparotomy is required. Leaving Veress needle in position is helpful in two ways. First, it is easy to find the punctured area after laparotomy and secondly, the further bleeding will be less.

Hanging Drop Test

Few drops of saline should be poured over the Veress needle and abdominal wall should be lifted slightly, if tip of the Veress needle is inside the abdominal cavity the hanging drop should be sucked inside because inside the abdomen, there is negative pressure. If tip of the Veress needle is anywhere else, the hanging drop test will be negative (**Figs. 17A and B**). Once it is confirmed that Veress needle is inside the abdominal cavity, the tubing of insufflator is attached and flow is started.

Measurement of Intra-abdominal Pressure

Measure intra-abdominal pressure by attaching the Veress needle to the laparoscopic insufflator. An intra-abdominal position of the needle is suggested for intra-abdominal pressure ≤ 10 mm Hg. In one large observational study, confirmation of low intraperitoneal pressure was the most reliable method to confirm Veress needle placement.

Once an intra-abdominal position of the needle is verified, initiate gas insufflation (typically CO_2). A properly placed Veress needle will allow free flow of gas. Tympany should be appreciated with percussion of the abdomen in the right upper quadrant.

For many years, surgeons have been using towel clip to elevate the abdominal wall. This towel clip technique

of lifting abdominal wall was advocated by Johns Hopkins University but after some time it was realized that towel clip technique increases the distance of skin from rest of the abdominal wall more than distance of abdominal wall from viscera. Abdominal wall should be held full thickness with the help of the thenar hypothenar and all the four fingers (**Fig. 14**). It is lifted in such a way that angle between Veress needles to abdominal wall should be 90° and angle between Veress needle and patient should be 45° . At the time of entry of Veress needle, surgeon can hear and feel two click sounds. The first click sound is due to rectus sheath and second click sound is due to puncture of peritoneum. Anterior and posterior rectus forms one sheath at the level of umbilicus, so there will be only one click for rectus.

If any other area of abdominal wall is selected for access surgeon will get three click sounds. Once these two click sound is felt, surgeon should stop pushing Veress needle further inside and he should use various indicators to know how far he has accessed. Once the desired length of Veress needle is introduced in abdomen, the tubing of insufflator should be attached to Veress needle (**Fig. 15**). It is important to keep nice hold on Veress needle throughout while gas is flowing; otherwise Veress needle can slip out and may create preperitoneal insufflation (**Fig. 16**).

Insufflation of Gas Test, Quadromanometric Test

Tubing of the insufflator should be tightly attached with the help of Luer lock of Veress needle (**Figs. 18 and 19**). For safe access, surgeon should always see carefully all the four indicators of insufflator at the time of creation of pneumoperitoneum. If the gas is flowing inside the abdominal cavity, there should be proportionate rise in actual pressure with total gas used. Suppose only with the entry of 200–300 mL of gas, if actual pressure is equal to preset pressure of 12 mm Hg, that means gas is not going in free abdominal cavity, it may be in preperitoneal space or inside omentum or may be in bowel. If gas is flown >5 L without any distention of abdomen that may be due to leakage or gas may be going inside the vessel.



Figs. 20A and B: Quadromanometric indicators.

Flow rate: This reflects the rate of flow of CO₂ through the tubing of insufflator. When Veress needle is attached, the flow rate should be adjusted to 1 L/min. Studies were performed over animal in which direct intravenous (IV) CO₂ were administered, and it was found that risk of air embolism is less if rate is within 1 L/min. At the time of access using Veress needle technique, sometime Veress needle may inadvertently enter inside a vessel but if the flow rate is 1 L/min there is a less chance of serious complication. When initial pneumoperitoneum is achieved and cannula is inside abdominal cavity, the insufflators flow rate may be set at maximum, to compensate loss of CO₂ due to use of suction irrigation instrument. This should be remembered that if insufflator is set to its maximum flow rate then also it will allow flow only if the actual pressure is less than preset pressure otherwise it will not pump any gas. Most of the surgeons keep initial flow rate with Veress needle to 1 L/min and as soon as they confirm that gas is going satisfactorily inside the abdominal cavity by percussion examination and seeing obliteration of liver dullness (**Fig. 21**), then they increase flow rate to 3 L/min. No matter how much flow rate you set for Veress needle, the eye of normal caliber Veress needle can give away CO₂ flow at maximum 2.5 L/min. Once cannula is in place flow rate can be increase but when the flow of CO₂ is >10 L/min inside the abdominal cavity through cannula and there is leak, there is always a risk of hypothermia and dryness of intestine. To avoid this hypothermia in all modern microprocessor controlled Laproflattor, there is an electronic heating system which maintains the temperature of CO₂.

Total gas used: As soon as 100–200 mL of gas is inside the abdominal cavity, surgeon should do percussion of the right hypochondrium and liver dullness should obliterate with tympanic sound (**Fig. 21**). This is the fourth indicator of insufflator. Normal size human abdominal cavity needs 1.5-L CO₂ to achieve intra-abdominal actual pressure of 12 mm Hg. In some big size abdominal cavity and in

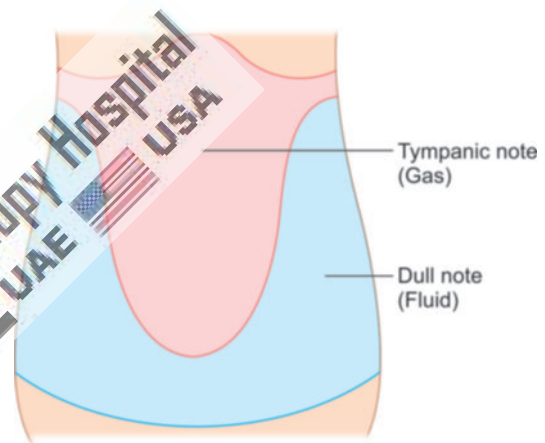


Fig. 21: Tapping over right hypochondrium will demonstrate obliteration of liver dullness.

multipara patients, sometimes we need 3 L of CO₂ (rarely 5–6 L) to get desired pressure of 12 mm Hg. Whenever there is less or more amount of gas used to inflate a normal abdominal cavity, surgeon should suspect some errors in pneumoperitoneum technique. These errors may be leakage or may be preperitoneal space creation or extravasation of gas.

■ PRIMARY TROCAR INSERTION

Technical errors in the insertion of trocars after creation of pneumoperitoneum are the most common causes of injury, resulting from inadequate stabilization of the abdominal wall, excessive resistance to trocar insertion, and excessive, misdirected or uncontrolled force applied by the surgeon along the axis of the trocar. It is important to stabilize the abdominal wall by full insufflation, complete muscle relaxation, to increase the distance between the anterior abdominal wall and the retroperitoneal vessels and the abdominal organs. It is important to ensure that the skin incision is of enough length and that the reusable trocar tip is sharp so that no resistance is offered.

Trocar and cannula design currently available have several basic features in common. They come in a variety of sizes and the central trocar may have a pyramidal, conical or rounded tip (**Figs. 22 and 23**). They have a valve system and a gas input with a tap. These cannulas have flap, bicuspid or magnetic valves and care should be taken when passing telescope through the port that lens of telescope should not hit the valve otherwise it can be damaged. Some disposable cannula has a safety system with a cylinder jumps forward after penetration of abdominal wall and forms a shield over the sharp trocar tip. This is not fool proof due to shield lag. In the most recent disposable cannula, the trocar itself is spring loaded. Few optical trocars are also available which has been discussed in Chapter 3: Laparoscopic Equipment and Instrument.

The first trocar and cannula inserted is usually 11 mm in diameter. This will accommodate a 10-mm telescope and leave enough space in the cannula for rapid gas insufflation, if required.

Steps of Primary Trocar Insertion

Patient Position

As for Veress needle insertion, patient should be placed supine with 10–20° head down. The cephalocaudal relationship between the aortic bifurcation and the umbilicus has been studied radiologically. The umbilicus is often located directly above or cephalad to the aortic bifurcation and is consistently located cephalad to where the left common iliac vein crosses the midline. The aortic bifurcation is located more caudal to the umbilicus in the Trendelenburg's position than in the supine position.

Site

The same site of Veress needle entry should be used for primary trocar insertion. Inferior or superior crease of umbilicus can be used in average built patient and transumbilical

incision can be used in obese patient. Before introduction of trocar, surgeon should confirm pneumoperitoneum. After adequate distention of abdominal cavity, the actual pressure should be equal to the preset pressure and gas flow should be stopped.

Before introduction of trocar, the initial 2-mm stab puncture wound of skin for Veress needle should be extended to 11 mm (**Fig. 24**). It should be remembered that most common cause of forceful entry inside the abdominal cavity with primary trocar is small skin incision. To avoid inadvertent injury of bowel due to forceful uncontrolled entry, the incision of skin should not be <11 mm in size. The skin incision for trocar should be smiling in shape (U-shaped) along the crease of umbilicus to get a better cosmetic value. After giving 11-mm incision with 11 number blades, surgeon should spread fatty tissues with Kelly clamp or mosquito forceps (**Fig. 25**). This will also dilate the obliterated vitellointestinal duct which was demonstrated first time by Scandinavian surgeons so it is called Scandinavian technique.

Introduction of Primary Trocar

Surgeon should hold the trocar in proper way. Head of trocar should rest on thenar eminence, middle finger should encircle air inlet and index finger should point toward sharp end (**Fig. 26**).

After holding the trocar properly in hand, full thickness of abdominal wall should be lifted by fingers thenar and hypothenar muscles. After creation of pneumoperitoneum, lifting of abdominal wall is difficult because it slips. To overcome this, it should be grasped to counter the pressure exerted by the tip of trocar.

Angle of Insertion

Initially, angle of insertion for primary trocar should be perpendicular to abdominal wall but once surgeon feels




Fig. 22: Reusable trocar and cannula.

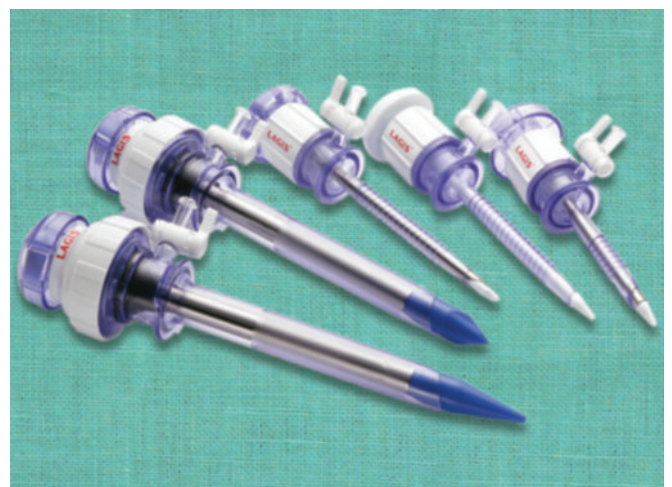

Fig. 23: Disposable trocar and cannula.

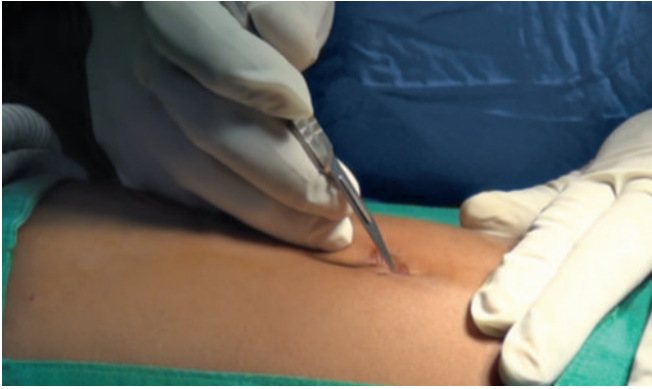

Fig. 24: 2-mm stab wound should be extended to 11 mm.

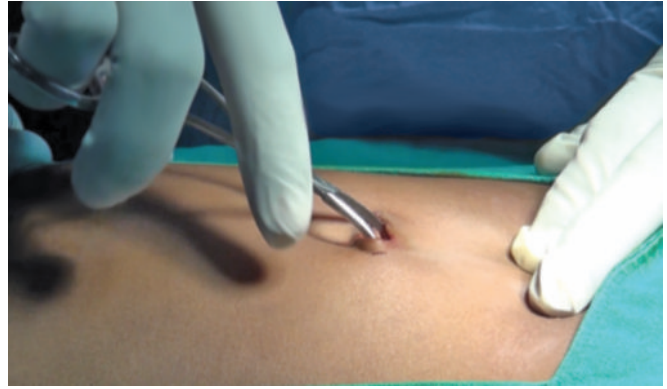

Fig. 25: Mosquito forceps tip introduced through stab wound.

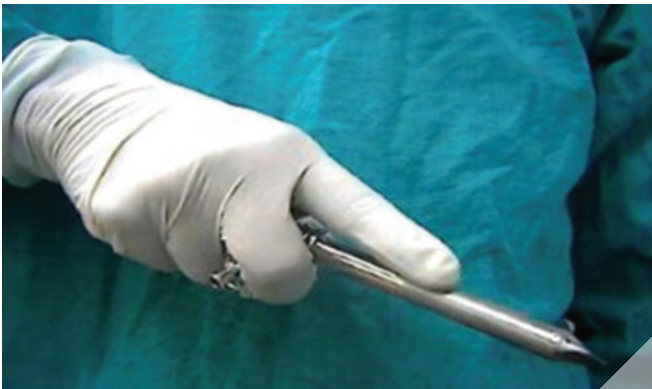


Fig. 26: The trocar and cannula should be held like a pistol.

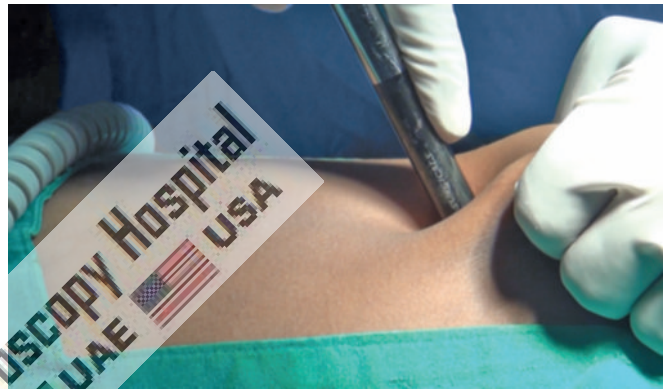


Fig. 27: Insertion of trocar by screwing fashion.

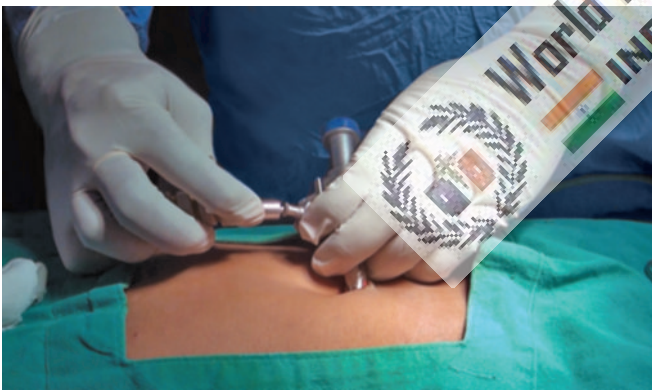

Fig. 28: Insufflator tubing is reattached once optical port is introduced.

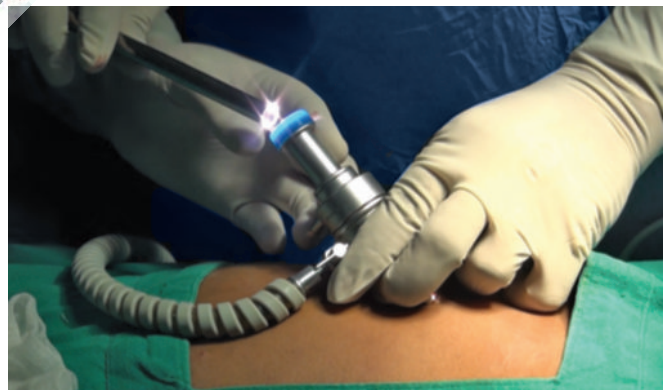

Fig. 29: Introduction of telescope.

giving way sensation, the trocar should be tilted to 60–70° angle. Insertion of trocar should be in screwing fashion in case of pyramidal trocar. In disposable bladed trocar, screwing the trocar should not be done (**Fig. 27**).

Confirmation of Entry of Primary Trocar

- Audible click if disposable trocar or safety trocar is used.
- Whooshing sound if reusable trocar is used (gas passes from the small hole at the tip of pyramidal shaped trocar to the head of trocar).
- Loss of resistance felt both in disposable as well as reusable trocar.

Once the trocar entry in abdominal cavity is confirmed, cannula is stabilized with left hand and trocar is removed by right hand. After removing trocar, cannula is pushed slightly further inside the abdominal cavity to prevent coming cannula in preperitoneal space with movement of abdominal wall with respiration. Once cannula is in place tubing of insufflator is attached again and flow is restarted to refill the CO₂ at preset pressure (**Fig. 28**). Telescope is introduced slowly keeping the oblique cut edge down in case of 30° telescope (**Fig. 29**). At the time of introduction of telescope, it is wise to keep valve of cannula open to prevent scratch over tip of telescope.

Once the telescope is inside, the elevation angle of the telescope should be 90° with panoramic vision. The site just below the entry of primary port is examined for any vessel or bowel injury (**Fig. 30**). Sometime, there may be few drops of blood found just below the site of entry but these few drops of blood are trickled blood through umbilical wound. If surgeon has any doubt about perforation of bowel or injury to vessel, he should evaluate this area again after putting other ports.

Working Ports

To select the site for secondary port, transillumination with illuminated telescope tip should be done first to locate avascular area to avoid injury of subcutaneous vessels. With the help of mosquito forceps, any remaining skin fiber is breached, and the subcutaneous fat should be cleared. Initially, the direction of entry of trocar is perpendicular but as soon as the tip of trocar is seen, the direction of trocar should be changed toward the free space to prevent any injury of underlying viscera (**Fig. 31**).

Subsequent Ports

Subsequent ports are inserted under direct vision at locations appropriate for the procedure and to the anatomy of the individual. If the port is on the opposite side of the

patient, it can be introduced same way but if surgeon is not able to bend enough to opposite side, his right index finger can be placed over the head of the trocar and left hand should guard the shaft of cannula. Alternatively, trocars of opposite side can be introduced by the assistant (**Fig. 32**). With slow rotatory movement of right hand, first the tip of trocar should be perpendicular to the skin but as soon as tip of trocar is seen direction of trocar should change toward the anterior abdominal wall. Alternatively, surgeon can go to another side of the patient and he can introduce the trocar in conventional way.

In same manner, all the working port should be introduced, and instruments are inserted to start the surgery (**Fig. 33**). It should be remembered that distance between two ports should never be <5 cm. The “Baseball diamond concept” discussed in Chapter 7: Principle of Laparoscopic Port Position is the most appropriate method to decide the site of introduction of working port. The positioning of operative ports is an important factor in determining the ease with which a procedure is carried out. It is a skill which must be learnt.

Slipping of Port

Sometimes, the port wound becomes bigger than the diameter of cannula and it tends to slip out frequently.

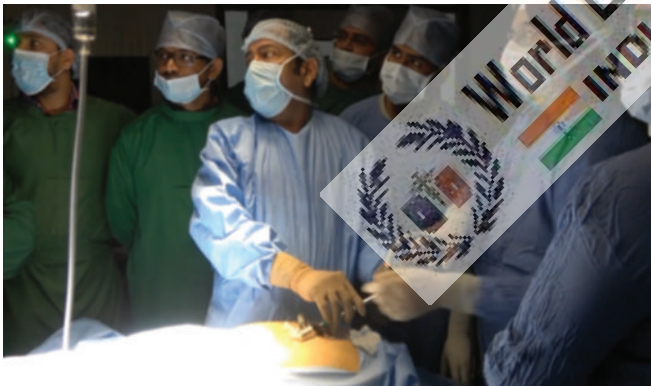

Fig. 30: Initial diagnosis of injury after access.

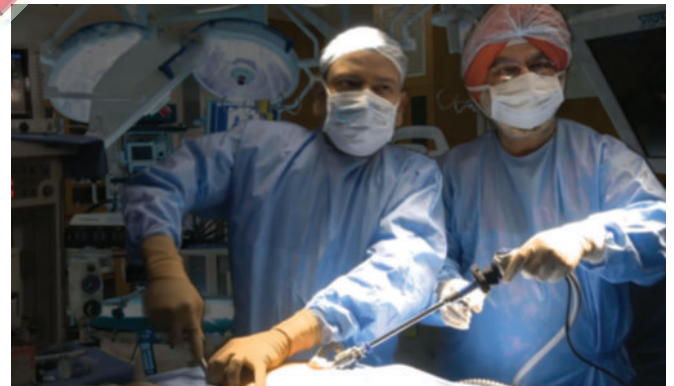

Fig. 31: Introduction of secondary port.

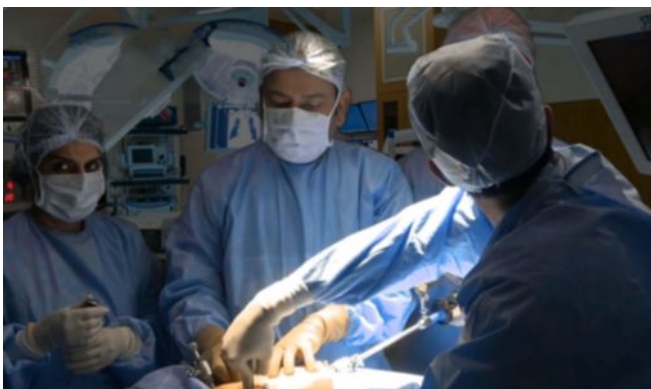


Fig. 32: Introduction of secondary trocar.

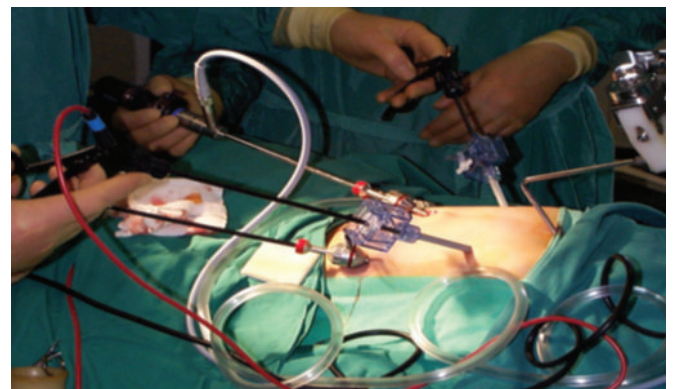


Fig. 33: All the ports and instruments should be positioned properly without entangling each other.

In these situations, a simple stitch over skin and fixing of the cannula with the help of sterile adhesive tape helps. In pediatric laparoscopic surgery, stabilizing the port is necessary. Reusable metal cannula has trumpet or flap valves. The flap valves can be manually opened when introducing or removing an instrument. This avoids damaging delicate instruments such as tip of telescope or blunting sharp instruments such as aspiration needle and scissors. A reducer tube is used with large cannula to maintain the gas seal and this automatically opens the valve. Several cannulas modeled on the Hasson cannula is available for use during open laparoscopic procedures. Different sized converters (gaskets) are available for disposable cannula to maintain the gas seal.

■ OPEN ACCESS

Open access technique was developed by Hasson in 1974 (Figs. 34 to 40). The choice of site may be based on the surgeon's preference or the presence of a previous regional incision that may have adhesions. Hasson trocar is used in open technique which is available both in disposable and reusable model (Figs. 34 and 35). Open access technique is like minilaparotomy and the cannula is introduced inside. Hasson's technique involves direct open visualization of the tissues at every layer until the peritoneum is opened, followed by placement of anchoring sutures in the fascia to secure a conical collar. The trocar is then placed through the collar to establish pneumoperitoneum and access. Disadvantages include persistent uncontrolled CO₂ leakage in many cases, increased incision size, and increased time for placement. This technique generally adds to the length of the procedure, taking longer to perform at the beginning and the end of the procedure compared with a closed Veress needle technique. Even though the Hasson technique is most commonly used in the periumbilical region, this method can be used anywhere on the abdominal wall and is particularly

useful when there is a concern for abdominal wall adhesions in a patient with a prior laparotomy.

In this, there is a direct entry by open technique, without creating pneumoperitoneum and insufflator is connected once blunt trocar is inside the abdominal cavity under direct vision. There are various ways of open access such as Hasson's technique, Scandinavian technique, and Fielding technique.

Some surgeons and gynecologists practice blind trocar insertion without pneumoperitoneum. The incidence of injury due to this type of access is much higher. This type of direct trocar entry is practiced by gynecologists for sterilization. Sterilization may be performed because in multipara patients the lower abdominal wall is lax; making the fascia thinner and easy elevation by hand is possible. Bleeding due to accidental damage to a major vessel during this initial stage is one of the most dangerous complications of laparoscopic surgery.

The Hasson trocar system was initially developed for laparoscopy in patients who have had a previous laparotomy. After seeing benefit of open access technique, many surgeons started using open access technique routinely in all their patients. An access wound was made using traditional open techniques and the Hasson trocar and cannula was designed to both fix the port and seal this larger wound round the port. It requires the use of sutures to prevent slippage of port. This involved making a small entry wound directly through the scar tissue of the umbilicus and then dilating this up by passage of a blunt, preferable conically tipped trocar and cannula (Figs. 39 and 40).

Steps of Open Access Technique

A transverse incision is made in the subumbilical region and the upper skin flap is retracted with an Allis forceps. The lower flap is retracted using a small right-angled retractor. Subcutaneous tissue is dissected till the linea alba and the

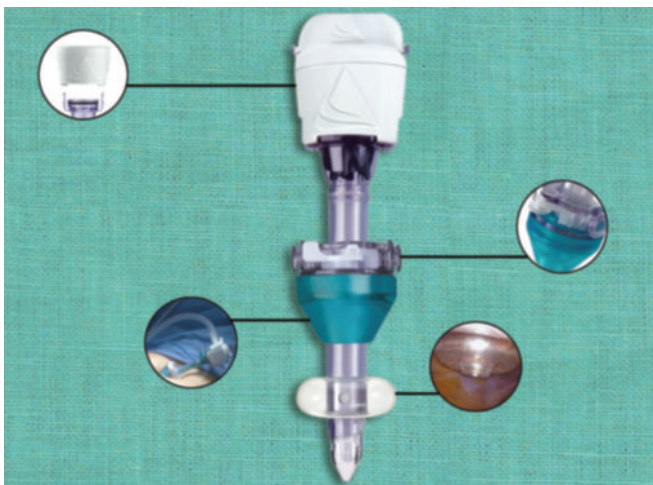


Fig. 34: Disposable Hasson trocar.

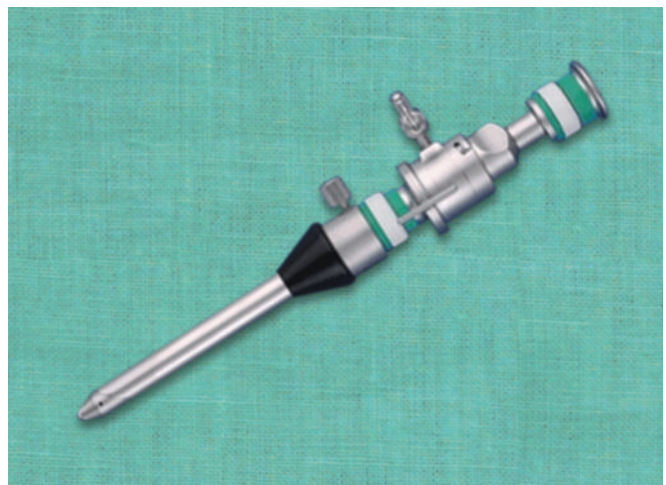


Fig. 35: Reusable Hasson trocar.

rectus sheath is visualized. Stay sutures are taken on either side of the midline.

- Make a transverse or longitudinal incision in the skin just below the umbilicus (**Fig. 36**).
- Stay suture is given both the end of transverse incision.
- Both the stays are pulled up to make a bridge-like elevation of rectus.
- Rectus sheath is incised in the midline along the line of linea alba pointing upward. Incision should not penetrate the peritoneum; otherwise any adhesion with the peritoneum may be punctured (**Figs. 38A and B**).
- Incise the fascia until a small amount of preperitoneal fat is identified. Place stay sutures in the fascial edges.
- The stay sutures aid with retraction of the abdominal wall and can be used to secure the port to the fascia, preventing its displacement during the surgery.
- A hemostat is stabbed into the peritoneum while holding the stays up (**Fig. 37**).
- The give-way of the peritoneum can be felt as peritoneum is perforated and then the hemostat is opened to widen the opening.
- Open the peritoneum bluntly, sweep the underside of the abdominal wall with the index finger to clear omentum or bowel, and confirm the absence of adhesions in the region of the incision (**Figs. 36 to 38**).

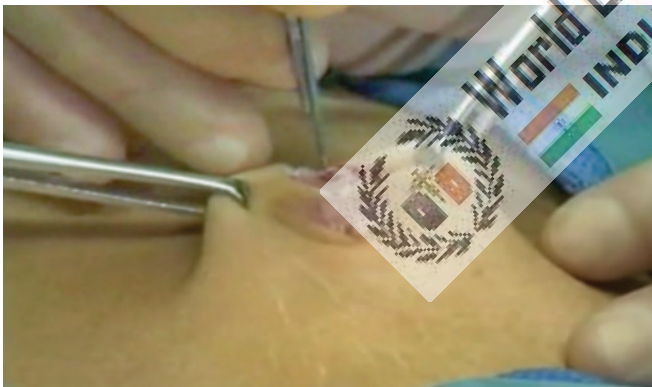
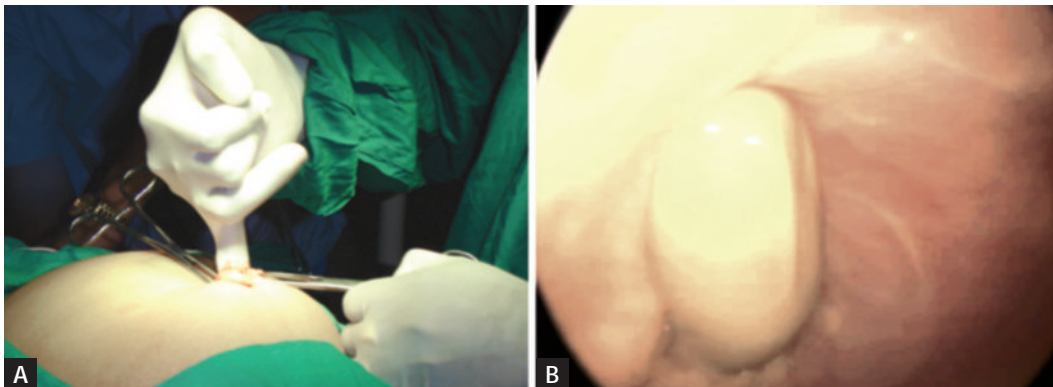


Fig. 36: Skin incision for open technique.

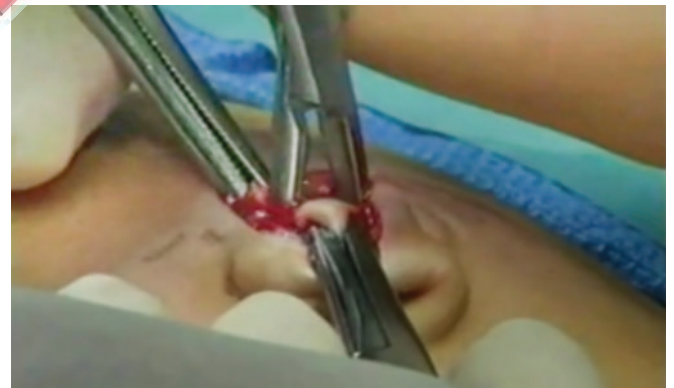

Fig. 37: Hemostat is stabbed into the peritoneum.



Figs. 38A and B: Finger insertion after open access will confirm adhesion.

- Surgeon should insert his finger to feel all around inside the abdominal cavity to feel any possible adhesion.
- Small tiny adhesion felt can be broken with gentle sweeping movement of finger.
- Blunt trocar-cannula should be inserted for the first port after visualizing the intraperitoneal viscera (**Fig. 39**).
- Care is taken not to make a big incision; cannula dilates the smaller incision to give an airtight fit.
- If incision is big, rectus string should be tightened to hold the port in proper position (**Fig. 40**).
- Attach the gas (typically CO₂) to the port and insufflate the abdomen. Fast insufflation should be avoided to prevent vasovagal shock.

Advantages of Open Technique

- Definite, small risk of injury with blind Veress needle technique irrespective of experience.
- Particularly useful in previous abdominal surgery or underlying adhesions.
- The incidence of injury to adhesion although not eliminated is significantly reduced by entry into the peritoneal cavity under direct vision.
- There is a decreased risk of injury to the retroperitoneal vessels. The trocar is blunt, and the angle of entry allows

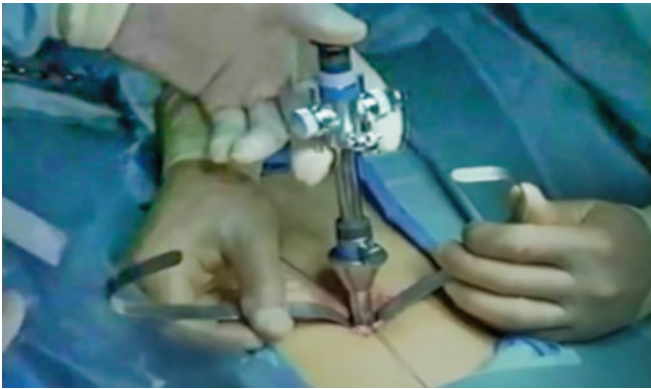


Fig. 39: Introduction of Hasson trocar.

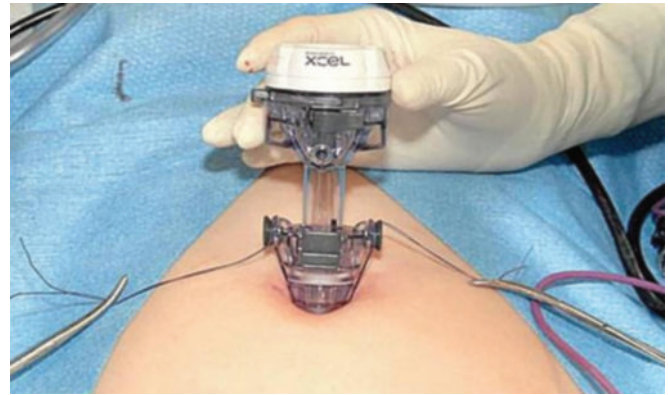


Fig. 40: Fixation of Hasson trocar.



Fig. 41: Optical trocar.

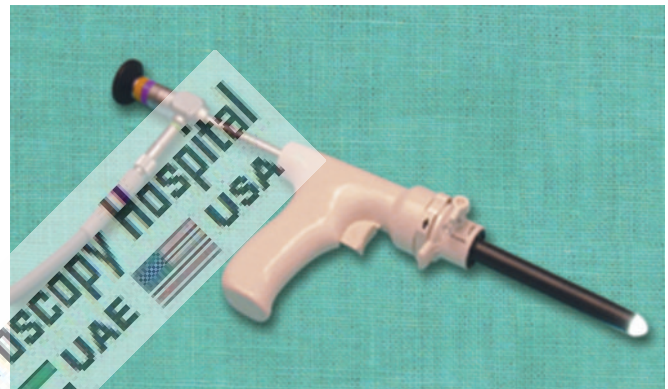


Fig. 42: Visiport.

the surgeon to maneuver the cannula at an angle, which avoids viscera, while still assuring peritoneal placement.

- The risk of extraperitoneal insufflation is eliminated. Placement under direct vision ensures that insufflation of gas is actually into the peritoneal cavity.
- The likelihood of hernia formation is decreased because the fascia is closed as part of the technique.
- Increasing number of surgeons performing laparoscopy without experience and in these group open technique may be easy.
- Useful in muscular man and children with strong abdominal wall.
- Useful for gynecologists or surgeon lacking enough upper arm strength to elevate the abdominal wall of patient.
- An open technique, which involves creating a minilaparotomy into which a special cannula is inserted, may be adopted. This procedure has its own complications and requires skilled execution.

Visual Entry Technique

The visual entry technique accesses the abdominal cavity with a specialized optical port that has a transparent tip, allowing each layer of the abdominal wall to be seen with a 0° laparoscope as it is being traversed (**Fig. 41**). Commercially available optical trocar/ports include Optiview, Kii optical

access system, and Visiport (**Fig. 42**). The way each of these devices affects tissue dissection as the tip advances differs in minor ways. These devices are typically used for primary port placement after Veress needle abdominal insufflation or secondary port placement after pneumoperitoneum has already been established.

Open Fielding Technique

This technique developed by Fielding in 1992 involves a small incision over the everted umbilicus at a point where the skin and peritoneum are adjacent. Fielding technique is useful in patients with abdominal incisions from previous surgery provided there is no midline incision, portal hypertension and recanalized umbilical vein, and umbilical abnormalities, such as urachal cyst, sinus or umbilical hernia. Thorough skin preparation of the umbilicus is carried out and the everted umbilicus is incised from the apex in a caudal direction. Two small retractors are inserted to expose the cylindrical umbilical tube running from the undersurface of the umbilical skin down to the linea alba.

This tube is then cut from its apex downward toward its junction with the linea alba. Further, blunt dissection through this plane permits direct entry into the peritoneum. Once the peritoneal cavity is breached, the primary port can be inserted directly, and insufflation started. A blunt internal

trocar facilitates insertion of this port and an external grip that can be attached to the port assist to secure it in position. Suture is usually not required to prevent gas leakage because the umbilicus has been everted so the angle of insertion of the laparoscopic port becomes oblique and the incision required is relatively small. However, one may be needed to stabilize the port.

Scarred Abdomen

Additional precautions are necessary during the access procedure in patients with abdominal scars. It may be inadvisable to insert the Veress needle below the umbilicus in a patient with a scar in this area (or an umbilical hernia). Insufflation through unscarred such as subcostal region, or if this is scarred, the iliac fossa is better. A general guideline is to choose the quadrant of the abdomen opposite to that of the scar.

Contraindications of Umbilical Entry

- Previous midline incision
- Portal hypertension with recanalized umbilical artery with advanced cirrhosis of the liver
- Umbilical abnormalities viz. urachal cyst, sinus, hernia.

PNEUMOPERITONEUM IN SPECIAL CONDITIONS

Palmer's Technique

This access was advocated by Palmer in the 1940s because visceral parietal adhesions are rarely encountered in this area (**Fig. 43**). A small incision is made to allow the insertion of the Veress needle through left subcostal margin (**Fig. 44**). In addition, some authors feel that because the abdominal wall in the area is supported by the rigid thoracic wall, insertion of the needle is more controlled than in the periumbilical area. Palmer's technique is particular useful in cases where umbilical entry is contraindicated, it is preferred to use left upper quadrante for entry of Veress needle. The Veress needle is introduced through left hypochondria, i.e., Palmer's point 2 cm below the left subcostal margin in midclavicular line

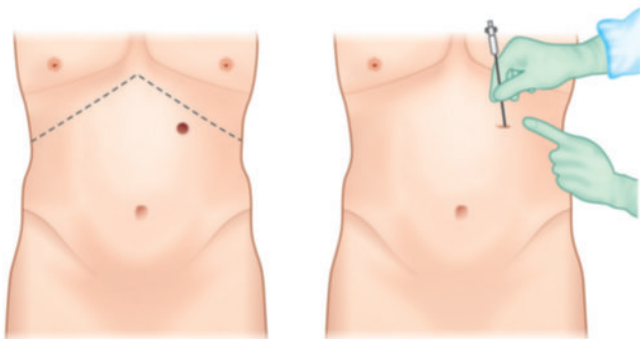


Fig. 43: Palmer's point of access.

(**Fig. 45**). Special care should be taken that there should not be hepatosplenomegaly. After access through Palmer's point, umbilicus site is rechecked for any adhesion or other abnormalities. If necessary, umbilicus port may be introduced under vision.

Mishra's Technique

This access technique we have developed where little modification of Palmer's technique is done. We give incision 2 cm above the costal margin in midclavicular line called Mishra's point (**Fig. 46**). To introduce Veress needle at Mishra's point abdominal wall is stretched down and brought below the costal margin. Advantage of this technique is there is no incidence of hernia because after surgery incision retract back to 2 cm above the costal margin (**Fig. 47**). During insertion of Veress needle or trocar through the palmer's point, the tip of the trocar should be pointed toward the stomach to prevent injury of splenic flexor of colon. It is very important that nasogastric tube should be in place and stomach should be deflated (**Fig. 48**).

Obese Patients

In obese patient, incision site should be transumbilical (base of umbilicus) for the insertion of Veress needle, because it is the thinnest abdominal wall and even in obese patient, the amount of fat in transumbilical region is less compared to other areas of the abdominal wall. Direction of Veress needle entry in obese patient should be perpendicular to abdominal wall and patient should be in supine position not in Trendelenburg's position (**Fig. 49**). Once the Veress needle is inside pneumoperitoneum should be created up to 18 mm Hg. Once the actual pressure is equal to preset pressure and at least 1.5–3 L of gas is introduced, Veress needle is removed. After removing Veress needle, the initial incision is enlarged up to 11 mm. After enlarging the initial incision, fat should be cleared up to anterior rectus sheath with the help of hemostat and little finger. In obese patients, it is difficult to lift the abdominal wall alone, assistant's hand should be asked for help to have a better grip (**Fig. 50**). If bariatric surgery or fundoplication is planned, then Veress needle

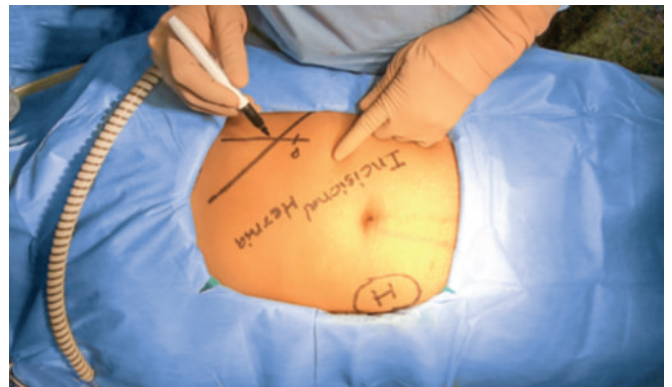


Fig. 44: Palmer's point 2 cm below the costal margin.

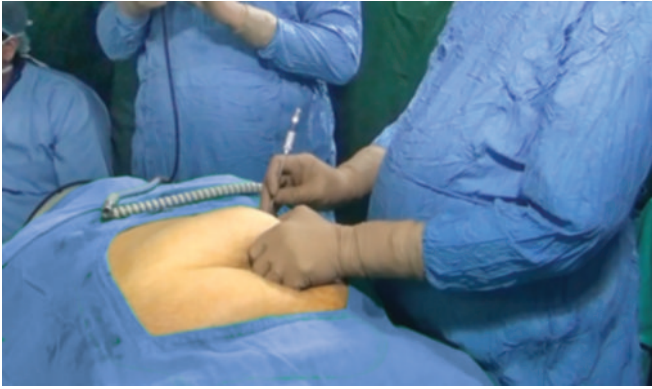


Fig. 45: Veress needle insertion through Palmer's point.

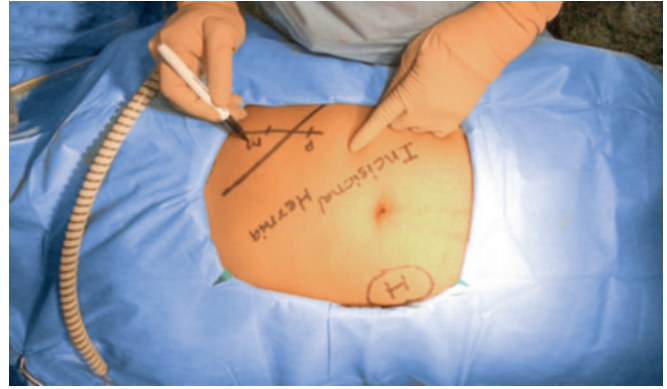


Fig. 46: Mishra's point 2 cm above the costal margin.

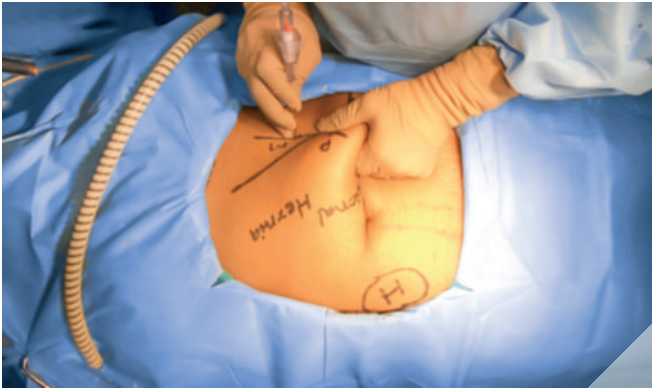


Fig. 47: Veress needle insertion through Mishra's point.

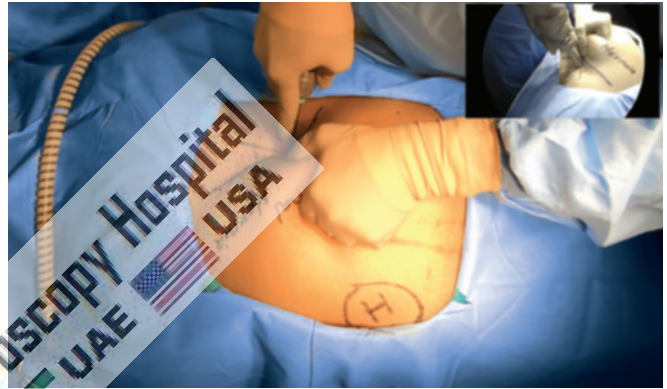


Fig. 48: Trocar insertion through Mishra's point.

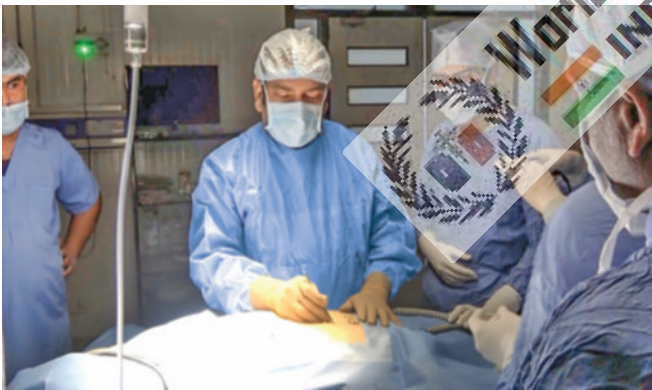

Fig. 49: Patient should be in supine position not in Trendelenburg's position.

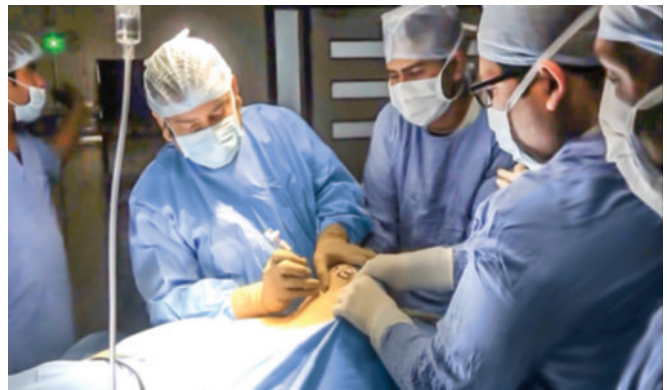

Fig. 50: Veress needle introduction in obese patient.

and primary trocar need to be introduced supraumbilical so that the telescope can show the diaphragm and posterior mediastinum during esophageal mobilization.

■ ENTRY IN CASES OF MORBID OBESITY

Abdominal access can be challenging in the patient with a thick abdominal wall; however, all types of entry access can be safely performed by experienced surgeons. In morbid obese patient, the umbilicus is well below the aortic bifurcation in supine position. When using the Veress needle technique in obese patients, the left

upper quadrant is preferred by many surgeons for initial placement (Palmer's point). If supraumbilical access is used to perform bariatric surgery assistant's help should be taken to lift the abdominal wall (**Fig. 50**). Longer port 20 cm in length is required in case of obese patient (**Fig. 51**). The irrigation test, aspiration test, the saline drop test, and an opening pressure of <10 mm Hg should all be used to confirm proper placement of the needle. When using the Hasson technique for patients with a large amount of subcutaneous fat, the incision should be made large enough to identify the abdominal wall fascia and peritoneum.

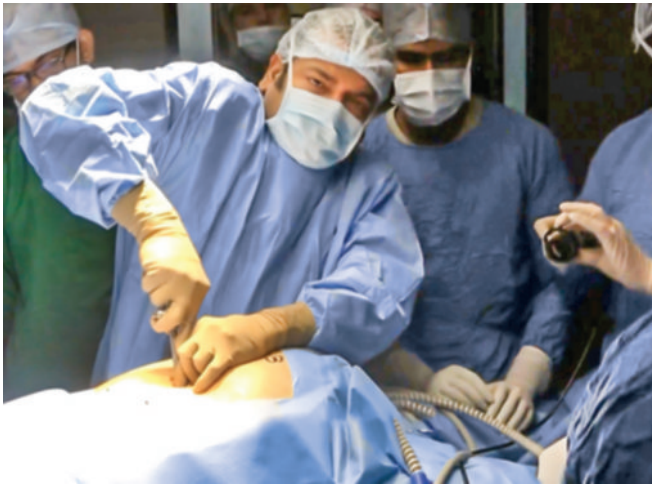

Fig. 51: Optical trocar entry in obese patients.

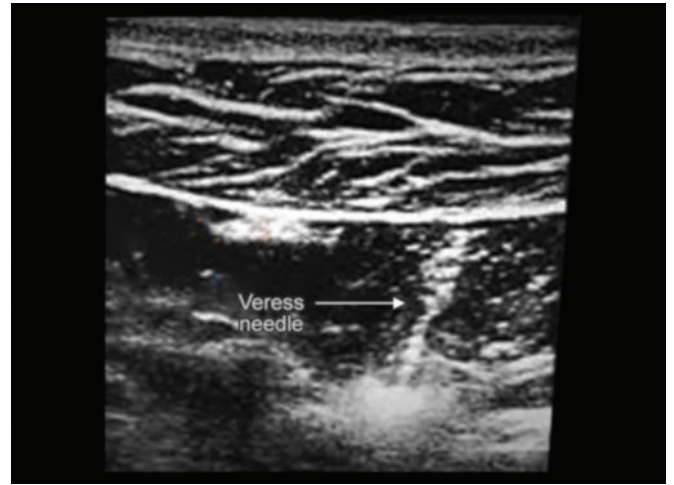


Fig. 52: Ultrasound-guided entry.

The area beneath the Veress needle insertion site inside the abdomen should be inspected for injuries during the initial laparoscopic evaluation of the abdomen.

Ultrasound Visceral Slide

There is a simple preoperative test that can help to identify a safe region for Veress needle insertion in the scarred abdomen. The preoperative detection of anterior abdominal wall adhesions by ultrasonic scanning is a simple and reliable technique of ultrasonic detection and mapping of abdominal wall adhesions. In patients with portal hypertension, a major risk factor upon entry into the abdomen is injury to large, engorged paraumbilical vessels in the anterior abdominal wall (**Fig. 52**). Major blood loss often results from just entering the abdomen. Use of ultrasound-guided access into the peritoneum for laparoscopic surgery is also a safe and effective approach in a patient presenting with portal hypertension. This technique demonstrates an effective tool in the surgical armamentarium for entering the abdomen in patients with caput medusae. Once the Veress needle has been inserted, there should still be concern about the risk of causing damage with the trocar. The following techniques have been described for this situation.

Sounding Test

A fine spinal needle, attached to a saline-filled syringe, is passed into the inflated abdomen. As the needle is slowly advanced, while aspirating, a stream of bubbles is seen in the saline until the needle tip contacts tissue. The needle is then withdrawn toward the surface and the process repeated several times, in different directions, thereby “mapping” the gas filled cavity and any solid structures.

Complications of Access Technique

The rate of serious complications associated with a laparoscopic approach is overall low. Half of the

complications occur at the time of abdominal access for camera or port placement. Complications can also arise from abdominal insufflation, tissue dissection, and hemostasis. Conversion to an open procedure may be needed to manage complications that have been identified intraoperatively, while others may be recognized in postoperative period. Severe complications such as vascular injury and bowel perforation can be catastrophic and are the main cause of procedure-specific morbidity and mortality related to laparoscopic surgery. Improper trocar insertion causes most of the operative complications of laparoscopic surgery. Examples are injury to the bowel, major vessels, bladder, inferior epigastric vessels, and subcutaneous emphysema. Other complications include thermal injury to the bowel, abdominal wall contusions, trocar site herniation with possible bowel obstruction, and trocar site tumor implants. However, the overall incidence of complications is relatively low (about 2%). There have been a few case reports of vulvar edema and surgical emphysema after laparoscopic surgery. The mechanism is unclear, but the condition is self-limited and resolves with conservative management. Patients with an abdominal wall hematoma from laparoscopic access who are hemodynamically stable and with no signs of hematoma expansion can be managed conservatively.

Access Injuries

The incidence of abdominal access injury was 5–30/10,000 procedures. Bowel and retroperitoneal vascular injuries comprised 76% of all injuries, and almost 50% of small and large bowel injuries were unrecognized for at least 24 hours. The overall reported rate of vascular injury arterial or venous injury ranges from 0.1 to 6.4/1,000 laparoscopies. Most injuries involve minor vessels; however, underreporting is common. Bladed disposable trocars with sharp blades are more likely to injure vessels compared with smooth, pyramidal tip trocars that push the vessel out of the way.

The types and proportion of organ injury during abdominal access were as follows:

- Small bowel (25%)
- Iliac artery (19%)
- Colon (12%)
- Iliac or another retroperitoneal vein (9%)
- Secondary branches of a mesenteric vessel (7%)
- Aorta (6%)
- Inferior vena cava (4%)
- Abdominal wall vessels (4%)
- Bladder (3%)
- Liver (2%)
- Other (<2%)

Port-site metastasis refers to cancer growth at a port incision site after laparoscopic tumor resection. Port-site metastasis occurs after 1–2% of laparoscopic procedures performed in the presence of intraperitoneal malignancy, which is equivalent to the rate of wound metastasis after laparotomy performed under similar conditions. Mechanism of metastasis includes hematogenous spread or direct contamination by tumor cells, secondary effects from pneumoperitoneum-related immune suppression, and surgical technique. Although it is not clear whether port-site metastases can be prevented, suggested measures to minimize the risk of port-site metastases include the use of wound protectors and specimen extraction bags, instillation of agents to prevent tumor growth, and port-site excision.

Access Injury Risk Factors

It is shown that patients who have had prior open surgery for intra-abdominal or pelvic disease have a higher risk of complications related to adhesions compared with patients who do not have this history. Other conditions that increase the risk of complications include extensive bowel distention, very large abdominal or pelvic mass-like large fibroid or abdominal cyst, and diaphragmatic hernia. In addition, patients with poor cardiopulmonary reserve due to severe chronic obstructive pulmonary disease (COPD) and cardiac disease may not be candidates for abdominal insufflation given the physiologic changes related to pneumoperitoneum. For patients with risk factors for complications, the laparoscopic approach and approach to abdominal access need to be carefully planned; an open approach may be preferred. If possible, these patients can be a candidate of gasless laparoscopic surgery. The frequency of complications during access technique may be related to surgeon experience and the number of the specific procedures performed for some, but not all, types of minimal access surgical procedures.

Mild-to-Moderate Hypotension

In cases of moderate hypotension, the surgeon should consider discontinuing gas insufflation immediately and

reducing intra-abdominal pressure to 8.0 mm Hg. 360° scan of the abdominal cavity should be performed immediately to rule out retroperitoneal bleeding. If bleeding or expanding hematoma is seen, one should proceed immediately to long midline laparotomy and compression of the bleeding vessel. Blood should be aspirated; bleeder is exposed, and bleeding should be controlled with vascular clamps. When necessary, operator should obtain assistance of a vascular surgeon.

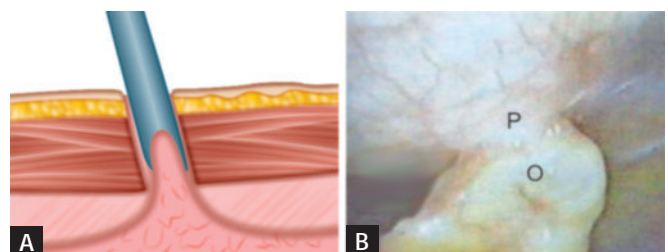
Withdrawal of Instruments and Ports

Once the surgery is finished, all the instrument should be removed carefully under vision. All the accessory port should be removed, and the gas is removed by releasing the valve of 10 mm cannulas. The primary port should be taken out in the end (**Fig. 53**).

If last port is suddenly withdrawn sudden suction effect of cannula can pull the omentum or bowel inside the port wound, the chances of port-site hernia and adhesion are much higher in this case. It is a good practice to insert some blunt instrument or telescope inside the abdomen while removing the last cannula out over that instrument, to prevent inadvertent entrapment of omentum or bowel (**Figs. 54A and B**).

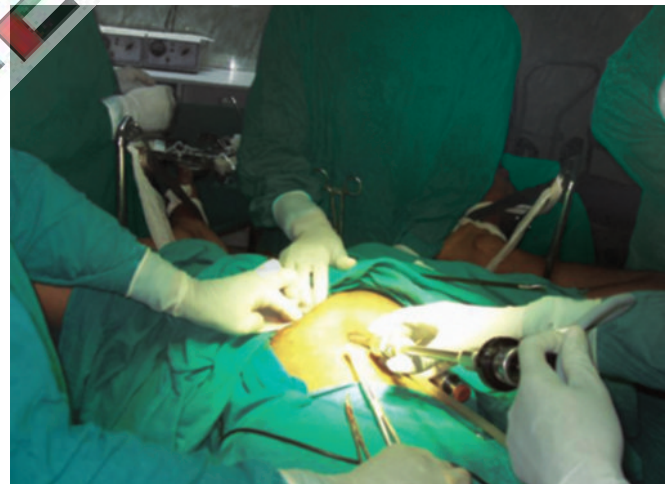

Fig. 53: The tip of telescope should be introduced in and cannula is pulled over telescope to prevent suction of omentum or bowel.



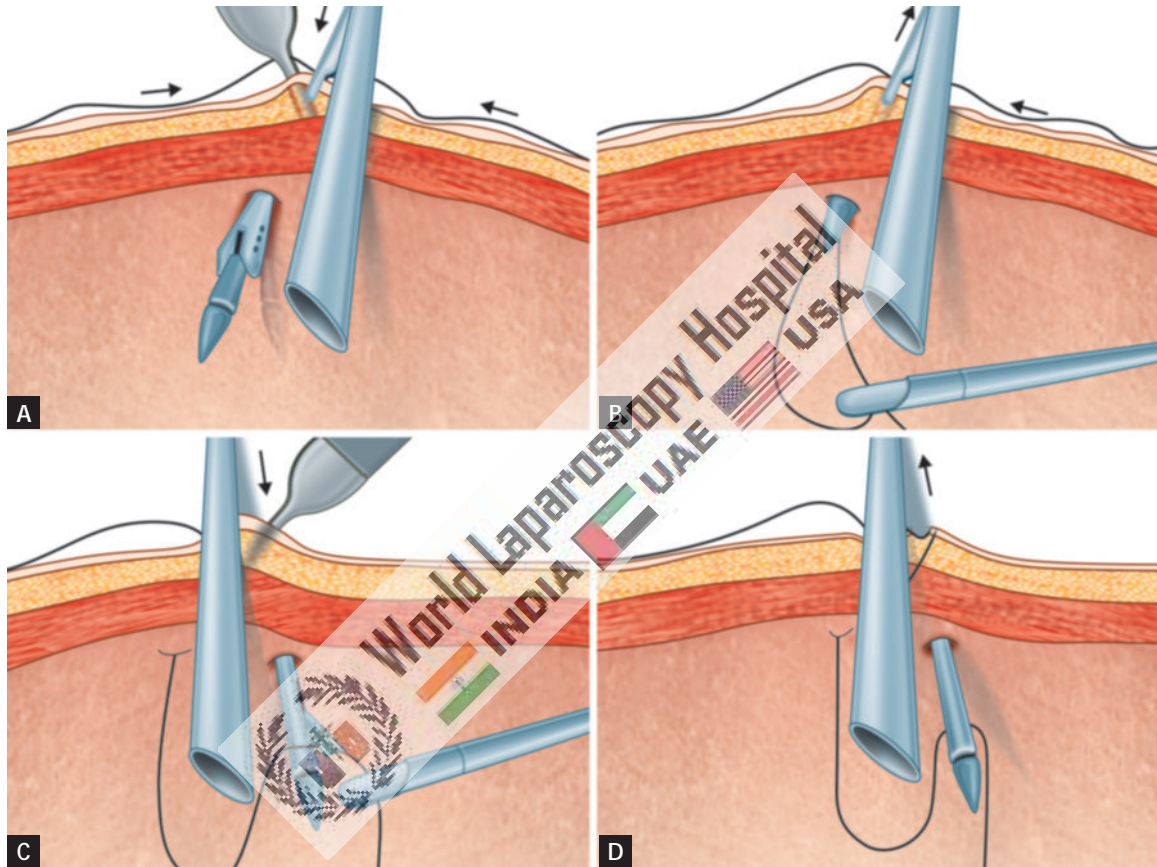
Precaution should be taken not to take out port suddenly, without removing complete gas

Figs. 54A and B: Adhesion may form if cannula is pulled rapidly at the end of surgery (P: peritoneum; O: omentum).

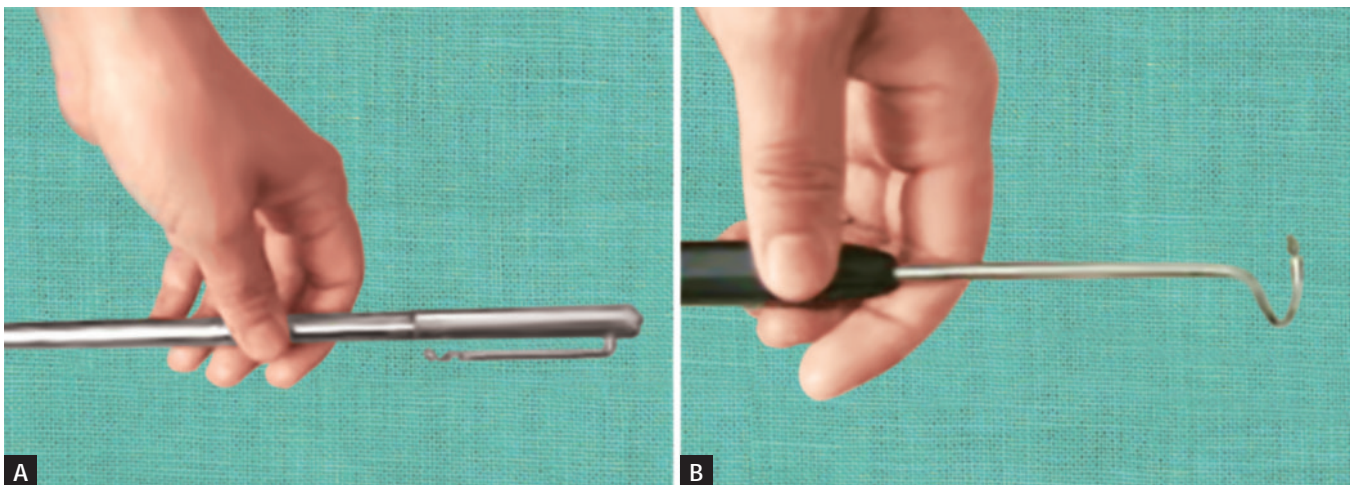
■ PORT CLOSURE TECHNIQUES

The access technique will result in breach in continuity of abdominal wall which need to be repaired at the end of surgery. All the 10 mm or >10 mm port should be repaired properly to prevent any future possibility of hernia. The rectus sheath is only necessary to suture with Vicryl. Only one stitch is required in middle which will convert 10 mm wound into 5 mm. The 5 mm port wounds are not necessary to repair (**Figs. 55A to D**).

Various types of port closure instruments are available. The suture passer is a convenient instrument for port closure, it is used to pass the thread on the side of cannula and then it is tied externally (**Figs. 56A and B**). For port closure, specially designed port closure instruments are also available commercially, such as port closure needle and aneurysm needle. After closing the rectus sheath, the skin can be closed by intradermal, skin stapler or by any of the surgical skin glues available.



Figs. 55A to D: Port closure with the help of suture passer.



Figs. 56A and B: Port closure needle and aneurysm needle.

Gasless Laparoscopic Surgery

Conventional laparoscopic surgery requires pneumoperitoneum to elevate the abdominal wall for proper exposure. A continuous insufflation of a noncombustible gas in a sealed environment is essential part of MAS. Many undesirable physiological side effects have been observed with CO₂ pneumoperitoneum. Furthermore, it has been necessary to retrain surgeons to use specialized instruments in order to operate on video images. Abdominal lifting mechanical devices can provide working space without pneumoperitoneum. With gasless technique, conventional instruments can be used, direct visualization of abdominal viscera is possible, and digital examination of abdominal contents can be performed without the fear of losing exposure. Since these procedures are being performed in an isobaric abdominal cavity, the risk of body fluid contamination to operating team is diminished when compared to open or traditional laparoscopic surgery. Gasless laparoscopic surgery is primarily advocated for the patients who are at high risk of pneumoperitoneum. A variety of abdominal lift devices have been developed recently to provide good working space. Although gasless laparoscopic surgery is good for patient with high risk of pneumoperitoneum, due to intraoperative problems and complications and because of suboptimal exposure, gasless laparoscopic surgery is still not considered as the prime modality for every patient. All the gasless systems can be used on their own or with low pressure insufflation (4–6 mm Hg).

Three Basic Types

1. Rubber tube sling abdominal wall lifts
2. Planar intraperitoneal abdominal wall retraction lift devices
3. Subcutaneous abdominal wall lift devices.

None of these techniques gives as good a laparoscopic exposure as the pressurized pneumoperitoneum because

they produce a tent-like elevation of the abdominal wall rather than an elevated expansion and they do not depress the hollow organs and omentum. Exposure is improved when low pressure insufflation is added.

Several devices for gasless laparoscopy have been developed recently. The Laparolift (Origin Medsystems) is commercially available device routinely used by many surgeons and gynecologist worldwide (**Figs. 57 to 59**).

It consists of an adjustable arm that is attached to the side of the operating table and sterilely draped (**Figs. 60A and B**). The surgeon can raise and lower it electronically. The arm is connected to the Laparofan, a disposable sterile device with two metal blades (available in 10 cm and 15 cm lengths) that are inserted through the umbilical incision in an overlapped position. After entering the peritoneal space, the Laparofan paddles are spread. Using the dovetail connector, the Laparofan retractor is attached to the Laparolift arm and raised, creating a working cavity for laparoscopic surgery. It is intended to be used as a substitute for, or in conjunction

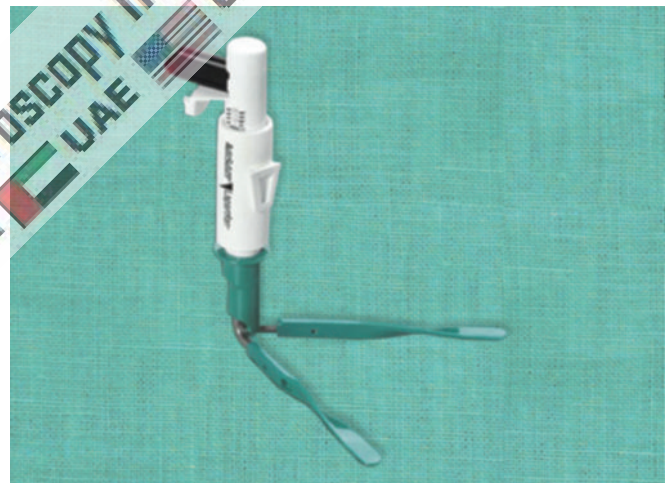


Fig. 58: Laparofan attached with laparolift after introduction inside abdominal cavity.



Fig. 57: Laparolift.

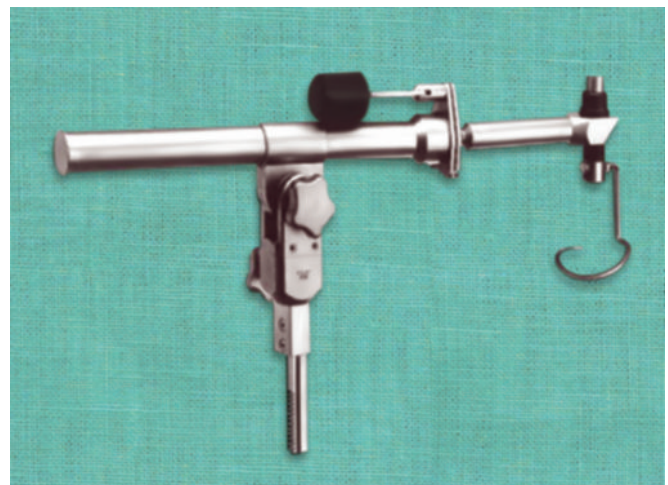
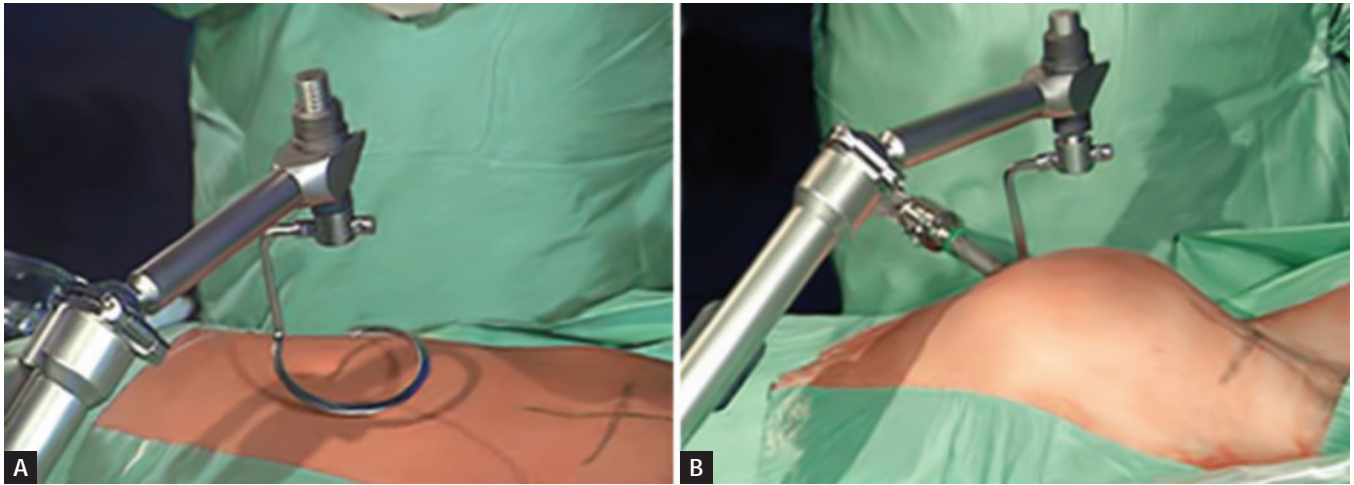


Fig. 59: Abdolift (another variety of abdominal lifting device).



Figs. 60A and B: Abdolift lifting the abdominal cavity.

BOX 1: Problems due to pneumoperitoneum.

- Hypothermia
- Cardiac arrhythmia
- Cardiovascular collapse
- Pulmonary insufficiency
- Gas embolism
- Venous thrombosis
- Cerebral edema/ischemia
- Ocular hypertension
- Extraperitoneal insufflation (subcutaneous emphysema, pneumomediastinum)

with, pneumoperitoneum for abdominal wall retraction. The blades are then splayed out and locked into a V by tabs on the plastic handle, which is fixed to the end of the adjustable arm. The maximum lifting force of 13.6 kg is equivalent to a pneumoperitoneum pressure of 15 mm Hg. The laparoscope is inserted through the same incision, cephalad to the Laparofan.

The physiologic changes associated with CO₂ pneumoperitoneum are well tolerated in healthy patients but may result in life-threatening cardiac arrhythmia, myocardial infarction, cardiac failure, or pulmonary insufficiency in compromised patients who cannot compensate for these alterations in hemodynamic (**Box 1**). A gasless laparoscopic approach could provide an added margin of safety for these patients. Patients undergoing laparoscopic surgery for malignancy or laparoscopically assisted vaginal hysterectomy may also benefit from gasless laparoscopy. Another potential advantage of gasless laparoscopy is the ability to use continuous suction and conventional laparotomy instruments (**Figs. 61 and 62**).

Disadvantages of Gasless Laparoscopic Surgery

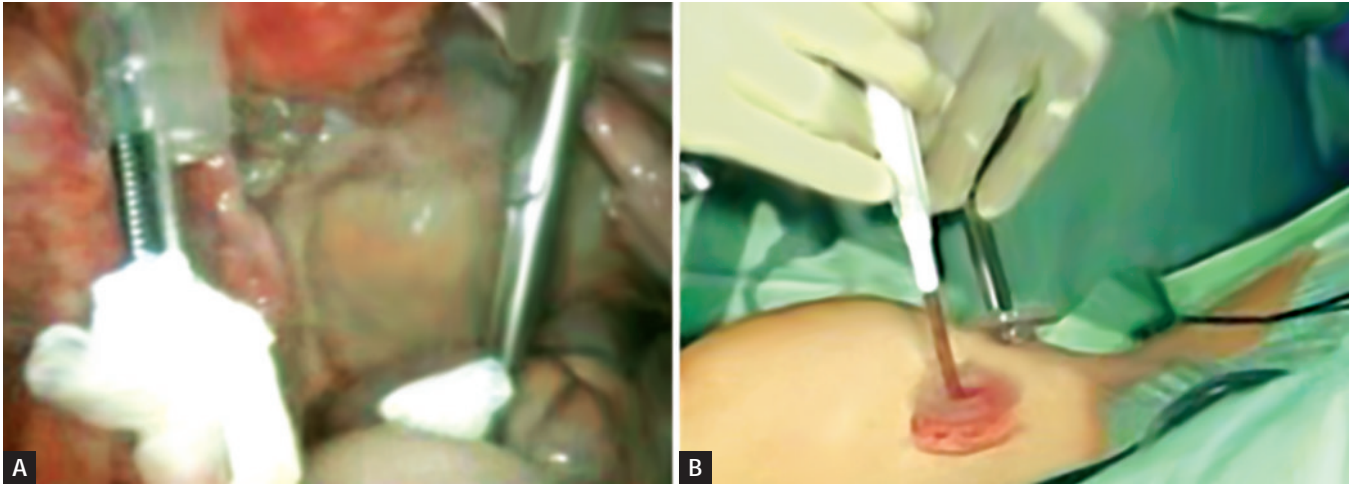
- Marked guttering effect of lateral abdominal wall results after lifting anterior abdominal wall.
- Anterior abdominal adhesion can make insertion of these mechanical device difficult and visualization almost impossible.

- It is a space occupying as instrument takes all the ergonomically good space of port position.
- It only elevates anterior abdominal wall whereas gas creates workable space in whole abdominal cavity.
- Sometime causes pressure necrosis of superior or inferior epigastric vessels.
- Bigger incision is required in the umbilicus.
- Difficult to perform in presence of ileus.
- Difficult peritoneal toileting at remote places.

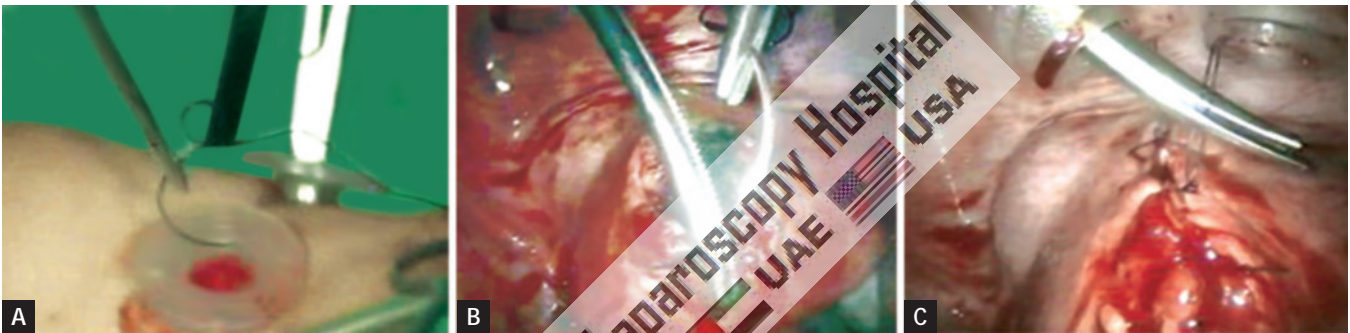
Studies to date have demonstrated that surgical procedures with gasless laparoscopy are technically more difficult than those performed with adequate pneumoperitoneum owing to impaired visualization from bowel in the pelvis. As with any new laparoscopic device, the initial enthusiasm over gasless laparoscopy has been tempered by actual clinical experience. However, because gasless laparoscopy still promises significant advantages over CO₂ pneumoperitoneum in high-risk patient, it is anticipated that interest in this technique will continue with improvements that will eliminate the current limitations to its use.

■ OPEN VERSUS CLOSED ACCESS TECHNIQUE

Knowledge of proper access techniques is crucial to avoid these complications. However, no significant differences in overall complication rates have been found for closed compared with open techniques for primary abdominal insufflation, when performed by experienced surgeons. Proper selection of patients, knowledge of laparoscopic surgical anatomy, and attention to proper abdominal access techniques are necessary to avoid complications. Risk factors for complications include prior laparoscopy, abdominal adhesions, excessive bowel distention, very large abdominal or pelvic masses, and diaphragmatic hernia. Patients with poor cardiopulmonary reserve may not tolerate pneumoperitoneum. For patients with risk factors for laparoscopic complications, an open surgical access should be preferred.



Figs. 61A and B: Use of open surgical instrument in gasless laparoscopic surgery.




Figs. 62A to C: Use of open needle holder and suturing technique in gasless laparoscopic.




BIBLIOGRAPHY




1. Bemelman WA, Dunker MS, Busch OR, den Boer KT, De Wit LT, Gouma DJ. Efficacy of establishment of pneumoperitoneum with the Veress needle, Hasson trocar, and modified blunt trocar (TrocDoc): a randomized study. *J Laparoendosc Adv Surg Tech A*. 2000;10:325-30.
2. Bernik TR, Trocciola SM, Mayer DA, Patane J, Czura CJ, Wallack MK. Balloon blunt-tip trocar for laparoscopic cholecystectomy: improvement over the traditional Hasson and Veress needle methods. *J Laparoendosc Adv Surg Tech A*. 2001;11:73-8.
3. Bhojru S, Payne J, Steffes B, Swansrtom L, Way LW. A randomized prospective study of radially expanding trocars in laparoscopic surgery. *J Gastrointestinal Surg*. 2000;4:392-7.
4. Bhojru S, Vierra MA, Nezhat CR, Krummel TM, Way LW. Trocar injuries in laparoscopic surgery. *J Am Coll Surg*. 2001;192(6): 677-83.
5. Bonjer HJ, Hazebroek EJ, Kazemier G, Giuffrida MC, Meijer WS, Lange JF. Open vs closed establishment of pneumoperitoneum in laparoscopic surgery. *Br J Surg*. 1997;84:599-602.
6. Champault G, Cazacu F, Taffinder N. Serious trocar accidents in laparoscopic surgery: a French survey of 103,852 operations. *Surg Laparosc Endosc*. 1996;6:367-70.
7. Cogliandolo A, Manganaro T, Saitta FP, Micali B. Blind vs open approach to laparoscopic cholecystectomy. *Surg Laparosc Endosc*. 1998;8:353-5.
8. Eden CG, King D, Kooiman GG, Adams TH, Sullivan ME, Vass JA. Transperitoneal or extraperitoneal laparoscopic radical prostatectomy: does the approach matter? *J Urol*. 2004; 172:2218-23.
9. Endogru T, Teber D, Frede T, Marrero R, Hammady A, Seemann O, et al. Comparison of transperitoneal and extraperitoneal laparoscopic radical prostatectomy using match-pair analysis. *Eur Urol*. 2004;46:312-20.
10. Gill IS, Clayman RV, Albala DM, Aso Y, Chiu AW, Das S, et al. Retroperitoneal and pelvic extraperitoneal laparoscopy: an international perspective. *Urology*. 1998;52:566-71.
11. Guillonneau B, Vallancien G. Laparoscopic radical prostatectomy: the Montsouris experience. *J Urol*. 2000;163:418-22.
12. Gutt CN, Oniu T, Schemmer P, Kraus T, Buchler MW. Circulatory and respiratory complications of carbon dioxide insufflation. *Dig Surg*. 2004;21:95-105.
13. Guven S, Guven ES, Ayhan A. Vulvar edema as a rare complication of laparoscopy. *J Am Assoc Gynecol Laparosc*. 2004;11:429-32.
14. Hanney RM, Carmalt HL, Merret N, Tait N. Use of the Hasson cannula producing major vascular injury at laparoscopy. *Surg Endosc*. 1999;13:1238-40.
15. Hashizume M, Sugimachi K. Needle and trocar injury during laparoscopic surgery in Japan. *Surg Endosc*. 1997;11:198-201.
16. Hasson HM. Open laparoscopy as a method of access in laparoscopic surgery. *Gynaecol Endosc*. 1999;8:353-62.
17. Hoznek A, Antiphon P, Borkowski T, Gettman MT, Katz R, Salomon L, et al. Assessment of surgical technique and perioperative morbidity associated with extraperitoneal versus transperitoneal laparoscopic radical prostatectomy. *Urology*. 2003;61:617-22.
18. Khoury N. A comparative study of laparoscopic extraperitoneal and transabdominal preperitoneal hernioplasty. *J Laparoendosc Surg*. 1995;5:349-55.
19. Liao CH, Chueh SC, Lai MK, Hsiao PJ, Chen J. Laparoscopic adrenalectomy for potentially malignant adrenal tumors greater than 5 centimeters. *J Clin Endocrinol Metab*. 2006;91:3080-3.




20. Magrina JF. Complications of laparoscopic surgery. *Clin Obstet Gynecol.* 2002;45:469-80.
21. Marcovici I, Shadigian E. Operative laparoscopy and vulvar hematoma: an unusual association. *JLS.* 2001;5:87-8.
22. McCormack K, Wake BL, Fraser C, Vale L, Perez J, Grant A. Trans-abdominal pre-peritoneal (TAPP) versus totally extraperitoneal (TEP) laparoscopic techniques for inguinal hernia repair: a systematic review. *Hernia.* 2005;9:109-14.
23. Merlin TL, Hiller JE, Maddern GJ, Jamieson GG, Brown AR, Kolbe A. Systematic review of the safety and effectiveness of methods used to establish pneumoperitoneum in laparoscopic surgery. *Br J Surg.* 2003;90:668-79.
24. Neudecker J, Sauerland S, Neugebauer E, Bergamaschi R, Bonjer J, Cuschieri A, et al. The European Association for Endoscopic Surgery clinical practice guideline on the pneumoperitoneum for laparoscopic surgery. *Surg Endosc.* 2002;16:1121-43.
25. Ost MC, Tan BJ, Lee BR. Urological laparoscopy: basic physiological considerations and immunological consequences. *J Urol.* 2005;174:1183-8.
26. Pados G, Vavilis D, Pantazis K, Agorastos T, Bontis JN. Unilateral vulvar edema after operative laparoscopy: a case report and literature review. *Fertil Steril.* 2005;83:471-3.
27. Peitgen K, Nimtz K, Hellinger A, Walz MK. Offener zugang oder Veress-nadel bei laparoskopischen eingriffen? Ergebnisse einer prospektiv randomisierten studie. *Chirurg.* 1997;68:910-3.
28. Porpiglia F, Terrone C, Tarabuzzi R, Billia M, Grande S, Musso F, et al. Transperitoneal versus extraperitoneal laparoscopic radical prostatectomy: experience of a single center. *Urology.* 2006;68:376-80.
29. Raboy A, Ferzli G, Albert P. Initial experience with extraperitoneal endoscopic radical retropubic prostatectomy. *Urology.* 1997; 50:849-53.
30. Remzi M, Klingler HC, Tinzl MV, Fong YK, Lodde M, Kiss B, et al. Morbidity of laparoscopic extraperitoneal versus transperitoneal radical prostatectomy versus open retropubic radical prostatectomy. *Eur Urol.* 2005;48:83-9; discussion 89..
31. Rodriguez AR, Kapoor R, Pow-Sang JM. Laparoscopic extraperitoneal radical prostatectomy in complex surgical cases. *J Urol.* 2007;177:1765-70.
32. Rozet F, Galiano M, Cathelineau X, Barret E, Cathala N, Vallancien G. Extraperitoneal laparoscopic radical prostatectomy: a prospective evaluation of 600 cases. *J Urol.* 2005;174:908-11.
33. Ruiz L, Salomon L, Hoznek A, Vordos D, Yiou R, de la Taille A, et al. Comparison of early oncologic results of laparoscopic radical prostatectomy by extraperitoneal versus transperitoneal approach. *Eur Urol.* 2004;46:50-6.
34. Semm K, Semm I. Safe insertion of trocars and the Veress needle using standard equipment and the 11 security steps. *Gynaecol Endosc.* 1999;8:339-47.
35. Stolzenburg JU, Do M, Rabenalt R, Pfeiffer H, Horn L, Truss MC, et al. Endoscopic extraperitoneal radical prostatectomy: initial experience after 70 procedures. *J Urol.* 2003;169:2066-71.
36. Tafame C, Scheidbach H, Hampe C, Schneider C, Köckerling F. Totally extraperitoneal endoscopic inguinal hernia repair (TEP). *Surg Endosc.* 2003;17:190-5.



Contact us

 World Laparoscopy Hospital
 Cyber City, Gurugram, NCR Delhi
 INDIA : +919811416838

 World Laparoscopy Training Institute
 Bld.No: 27, DHCC, Dubai
 UAE : +971523961806

 World Laparoscopy Training Institute
 8320 Inv Dr, Tallahassee, Florida
 USA : +1 321 250 7653